

CASE REPORT

Atypically large well-differentiated hepatocellular carcinoma with extensive fatty metamorphosis : Report of a Case

Daichi Ishikawa, Mitsuo Shimada, Tohru Utsunomiya, Yuji Morine, Satoru Imura, Tetsuya Ikemoto, Hiroki Mori, Yusuke Arakawa, Mami Kanamoto, Shuichi Iwahashi, Shinichiro Yamada, and Michihito Asanoma

The Department of Surgery, the University of Tokushima, Tokushima, Japan

Abstract : A large well-differentiated hepatocellular carcinoma (HCC) with fatty change is rare, and to date only a few cases have been reported. Herein, we present a 68-year-old man who developed a well-differentiated HCC with extensive fatty metamorphosis. The patient was referred to our institute because of a rapidly growing tumor in the left lobe of the liver. Ultrasonography showed a hyperechoic lesion with a peripheral hypoechoic area. Dynamic contrast-enhanced computed tomography (CT) scan in all three phases revealed the tumor which showed diffuse low attenuation with internal irregular enhancement. He underwent left lateral segmentectomy at the liver. Histological diagnosis confirmed well-differentiated HCC and the surrounding non-cancerous area was diagnosed as non-alcoholic steatohepatitis. The patient is still alive without recurrence after 17 months of follow-up. *J. Med. Invest.* 60 : 267-271, August, 2013

Keywords : *angiomyolipoma, fatty metamorphosis, well differentiated hepatocellular carcinoma, lipomatosis*

INTRODUCTION

Hepatocellular carcinomas (HCCs) are considered to progress stepwise from well-differentiated HCC to moderate, and finally to poorly differentiated HCC along with enlargement and increasing malignancy. Thus, well-differentiated HCCs are early form of HCCs in hepatocarcinogenesis and the average diameter is less than 20 mm (1). HCC as well as liver parenchyma is supplied by both the portal vein and hepatic artery. In general, well-differentiated HCCs progress to moderate-differentiated

HCCs with a transition of dominant blood supply of the tumor from the portal tracts to arteries (2). HCCs often contain various grades of fatty tissue. This fatty metamorphosis are more frequent in small well differentiated HCC nodules especially those under 20 mm in diameter. It is reported that HCCs in diameter from 11 to 15 mm contain fatty metamorphosis in 36.4%, while those in diameter of 3.0 cm have fatty change in 10% only at limited area or peripheral lesion (3). The fatty metamorphosis is also considered to be related to the ischemia and metabolic disorder although its pathogenesis remains unclear. It is very rare for a well-differentiated HCC with fatty change to progress to over 30 mm. Here, we present a case of well-differentiated HCC of 65 mm in diameter with remarkable fatty metamorphosis.

Received for publication February 6, 2013 ; accepted March 21, 2013.

Address correspondence and reprint requests to Mitsuo Shimada, MD, FACS, Department of Surgery, the University of Tokushima, 3-18-15 Kuramoto, Tokushima City, Tokushima, 770-8503, Japan and Fax : +81-88-631-9698.

CASE REPORT

Computed tomography (CT) of a 68-year-old man revealed a hepatic mass of 40 mm in diameter. He had no relevant past history except for regular alcoholic habits. Ultrasound-guided needle biopsy revealed unclear malignancy and remarkable fatty metamorphosis pathologically. Thus, the patient was diagnosed as suspicious angiomyolipoma and followed up without further treatments. After 3-months, however, the tumor was found to have rapidly grown to 65 mm in diameter, and thus he was transferred to our institute under suspicion of a malignant tumor.

On the laboratory findings of this case at the time of admission to our hospital, anti-hepatitis B virus core antibody (HBc Ab) and anti-hepatitis B virus e antibody (HBe Ab) were positive, while hepatitis B surface antigen (HBs Ag) and anti-hepatitis C (HCV) antibody were negative. Serum concentrations of PIVKA, CA19-9, Dupan-2, and Span-1 were elevated at 389 mAU/ml (normal range : < 40 mAU/ml), 44 ng/dl (normal range : < 37 U/ml), 260 U/ml (normal range : < 150 U/ml), and 54.8 U/ml (normal range : < 30 U/ml), respectively. The serum alpha-fetoprotein (AFP) level was within normal limit and AFP-L3 was not detected. ICG₁₅ was 5.4%, and he had no ascites or encephalopathy. Child-Pugh scoring was grade A. Ultrasonography (US) revealed a round high echoic tumor with a peripheral low echoic area in the left lobe of the liver (Figure 1A). On pre-contrast CT, the tumor was depicted as a low density area suggestive of fatty components. Dynamic contrast-enhanced CT in the arterial phase showed irregular enhancement in the tumor (Figure 1B). Portal and venous phases also showed irregular internal enhancement without wash-out (Figure 1C, D). Magnetic resonance imaging (MRI) of the tumor showed internal low intensity on T1-weighted image, and iso intensity on T2-weighted image (Figure 2A, B). Gd-EOB-DTPA-enhanced MRI revealed a decrease of contrast uptake in the hepatocyte phase. Additionally, CT and MRI images showed extensive fatty infiltration of the pancreas, which suggested a metabolic disorder (Figure 2C). Considering the rapid growth, he was preoperatively diagnosed as HCC. Differential diagnosis included hepatic angiomyolipoma (AML), combined hepatocellular and cholangiocellular carcinoma, and cholangiolocellular carcinoma (CoCC). Because AML consists of three components in variable proportions, namely blood vessels, fat and

smooth muscle cells, it is difficult to differentiate fat-containing HCC from AML preoperatively. Combined hepatocellular and cholangiocellular carcinoma and CoCC were considered because of the increased serum Dupan-2 level, low enhancement on contrast CT in the arterial phase and dilation of the peripheral left intrahepatic bile duct on magnetic resonance cholangiopancreatography (MRCP) (Figure 2D).

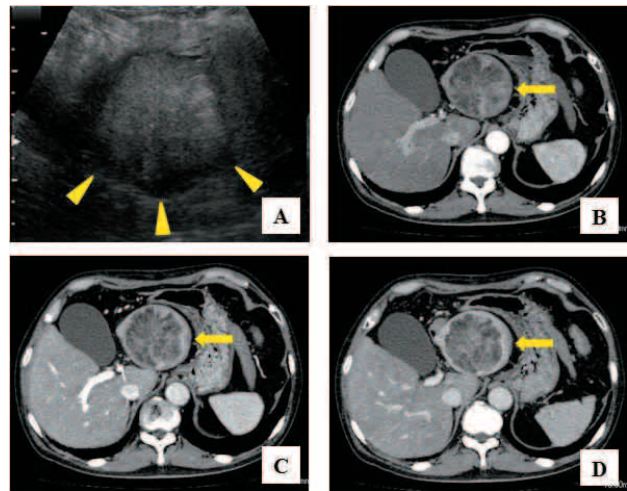


Figure 1 : Ultrasonography showed the round high echoic tumor with the peripheral low echoic area in the left lobe of the liver (A, arrowheads). Dynamic contrast-enhanced computed tomography (CT) in the arterial phase demonstrated irregular enhancement in the tumor (B, arrow). The portal and venous phases also showed the irregular internal enhancement without wash-out (C, D, arrow).

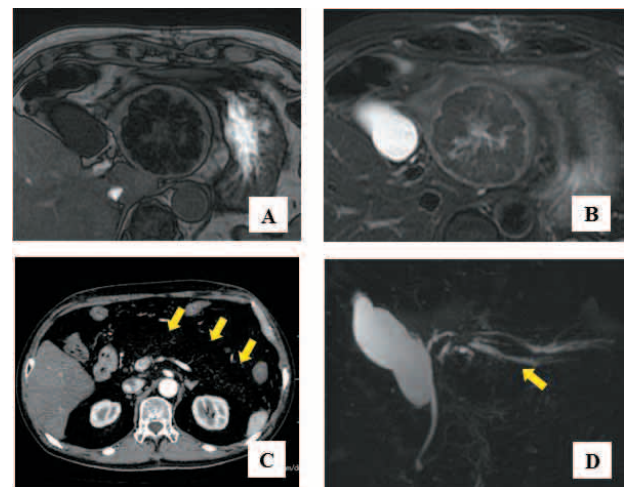


Figure 2 : Magnetic resonance imaging (MRI) showed the tumor with internal low intensity on T1-weighted image (A), and iso intensity on T2-weighted image (B). On CT image, pancreas is almost invisible due to lipomatosis (C, arrows). Magnetic resonance cholangiopancreatography showed dilation of the peripheral left intrahepatic bile duct (D, arrow).

Left lateral segmentectomy was performed with clear surgical margins. Macroscopic examination of the surgical specimen revealed a well circumscribed, solid, yellowish tumor without apparent capsules (Figure 3). Microscopically, most of the tumor was composed of atypical cells with a trabecular pattern and extensive fatty metamorphosis, and some of the peripheral area of the tumor showed the presence of pseudoglandular structures (Figure 4A, B). Histological diagnosis confirmed well-differentiated HCC. The surrounding non-tumor tissue included remarkable fatty change with Mallory body formation, infiltration of inflammatory cells, and fibrosis in the portal area. Thus, the surrounding tissue was diagnosed as non-alcoholic steatohepatitis (NASH) (Figure 4C-F). The postoperative clinical course was uneventful and the patient is still alive and well without any signs of recurrence at 17 months after the operation.

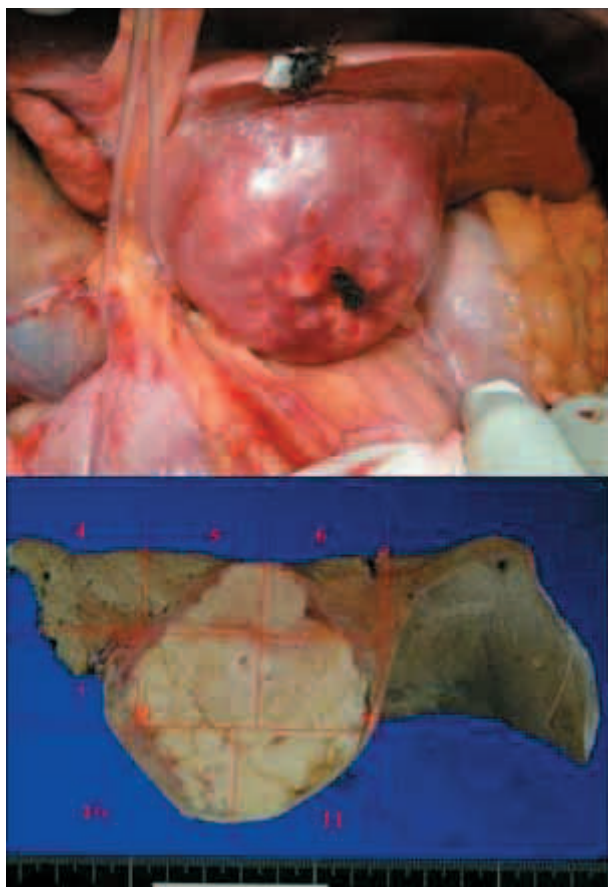


Figure 3 : Operative findings and macroscopic examination showed that the tumor was well-circumscribed, solid, and yellowish in color without apparent capsules.

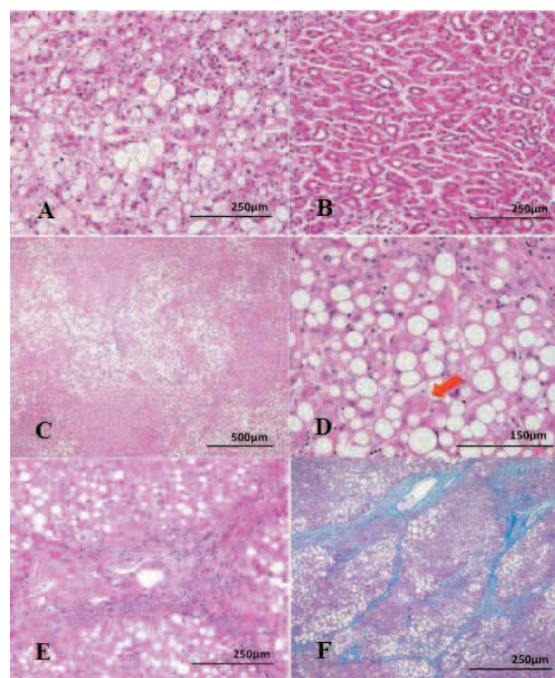


Figure 4 : Microscopically, most proportion of the tumor was composed of atypical cells with trabecular pattern and extensive fatty metamorphosis (A), and some proportion at peripheral area of the tumor included pseudoglandular structure (B).

The surrounding non-cancerous area included remarkable fatty change (C) with Mallory nodule (D, arrowhead), infiltration of inflammatory cells (E), and diagnosed as non-alcoholic steatohepatitis (NASH).

(A, B, C, D, E : Hematoxylin & eosin staining, D : Azan staining)

DISCUSSION

With the significant advances of diagnostic imaging, HCC in an early stage can be detected. Some HCC include fatty tissue within the tumor (3-5). It is reported that 10 of 600 HCC cases demonstrated fat metamorphosis (6). Fatty changes are noted to be diffuse in smaller tumors within 35 mm and concentrated in larger tumors. As to the pathogenesis of fatty metamorphosis in HCC, a relationship with circulatory disturbance has been suggested (3, 7-12). It is considered that the dominant blood supply switches from portal tracts to arteries when HCC becomes approximately 15 mm in diameter. And then some degree of ischemia and metabolic disorder cause the development of fatty change, although precise mechanisms remain to be understood. In this case as well, it can be speculated that the ischemia and metabolic disorder in the tumor caused the fatty metamorphosis. In most cases, this fatty change is observed in HCC within 20 mm in diameter but the tumor in the present case was as large as 65 mm in diameter. To our knowledge, there are no reports describing such a large well-differentiated

HCC (over 40 mm in diameter) with remarkable fatty change. Kudo *et al* reported that well-differentiated HCCs abundant of arterial blood supply grow more rapidly than those showing poor vascularity (13). In our case, CT image in arterial phase showed irregular enhancement of the tumor. Thus, this might cause the rapid growth from 40 mm to 60 mm during 3 months.

Hepatic angiomyolipoma (AML) is a benign tumor composed of various proportions of vessels, fat and smooth muscle tissues. It exhibits various findings on US, CT and MRI, and thus it is sometimes quite difficult to distinguish a fat-containing hepatocellular carcinoma from hepatic angiomyolipoma (AML). In the present case, based on ultrasound-guided fine needle biopsy (US-FNB) findings an accurate diagnosis could not be made in the previous hospital. While US-FNB is an effective method for diagnosis of liver tumor and it is reported to accurately diagnose HCC about 89.4% of nodules (14), sometimes it cannot provide a precise diagnosis because of sampling error or a lower ability to distinguish well-differentiated HCC from benign lesions. In addition, the tumor in this case included a large amount of fatty tissue, rendering an accurate diagnosis more difficult.

Pancreatic lipomatosis is a relatively rare benign condition and this is characterized by deposition of fat cells in pancreatic parenchyma. Although the exact pathogenesis behind this fatty replacement is not well known, several predisposing factors have been suggested, such as obesity, diabetes mellitus, chronic pancreatitis, aging, and liver disease (15, 16). In our case, it is unclear whether this pancreatic lipomatosis is related to extensive fatty metamorphosis of the tumor or non-alcoholic steatohepatitis. However, there might be some degree of metabolic disorder in this patient.

In conclusion, we described a rare case of large well-differentiated HCC with remarkable fatty metamorphosis. When radiographic evaluation shows fatty components in a liver tumor with a diameter greater than 20 mm, HCC with fatty metamorphosis should be taken into consideration.

CONFLICT OF INTEREST

None of the authors has any potential financial conflict of interest related to this manuscript.

REFERENCES

1. Monzawa S, Omata K, Yagawa A, Hosoda K, Araki T : Well-differentiated hepatocellular carcinoma. findings of US, CT, and MR imaging. *Abdom Imaging* 24 : 392-397, 1999
2. Toyoda H, Fukuda Y, Hyakawa T, Kumada T, Nakano S : Changes in blood supply in small hepatocellular carcinoma. correlation of angiographic images and immunohistochemical findings. *J Hepatol* 27 : 654-660, 1997
3. Kutami R, Nakashima Y, Nakashima O, Shiota K, Kojiro M : Pathomorphologic study on the mechanism of fatty change in small hepatocellular carcinoma of humans. *J Hepatol* 33 : 282-289, 2000
4. Tanaka S, Kitamura T, Imaoka S, Sasaki Y, Taniguchi H, Ishiguro S : Hepatocellular carcinoma ; sonographic and histologic correlation. *Am J Roentgenol* 140 : 701-707, 1983
5. Kanno T, Kurioka N, Kim S, Tamori A, Kim K, Oka H : Implications of hyperechoic lesions in small hepatocellular carcinoma. *Gastroenterol Jpn* 24 : 528-534, 1989
6. Yoshikawa J, Matsui O, Takashima T, Ida M, Takanaka T, Kawamura I : Fatty metamorphosis in hepatocellular carcinoma : Radiologic features in 10 cases. *Am J Roentgenol* 151 : 717-720, 1988
7. Saitoh S, Ikeda K, Koida I, Tsubota A, Arase Y, Chayama K : Small hepatocellular carcinoma : evaluation of portal blood flow with CT during arterial portography performed with balloon occlusion of the hepatic artery. *Radiology* 193 : 67-70, 1994
8. Matsui O, Kadoya M, Kameyama T, Yoshikawa J, Takashima T, Nakanuma Y : Benign and malignant nodules in cirrhotic livers : distinction based on blood supply. *Radiology* 178 : 493-497, 1991
9. Ikeda K, Saitoh S, Koida I, Tsubota A, Arase Y, Chayama K : Imaging diagnosis of small hepatocellular carcinoma. *Hepatoloty* 20 : 82-87, 1994
10. Saitoh S, Ikeda K, Koida I, Tsubota A, Arase Y, Chayama K : Serial hemodynamic measurements in well-differentiated hepatocellular carcinoma. *Hepatoloty* 21 : 1530-1534, 1995
11. Kiyomatsu K : Pathomorphologic study on hepatocellular carcinoma (HCC) ; a study of fatty change in HCC. *Acta Hepatol Jpn* 30 : 974-979, 1989

12. Kudo M, Tomita S, Kashida H, Mimura J, Okabe Y, Hirasa M : Tumor hemodynamics in hepatic nodules associated with liver cirrhosis. relationship between cancer progression and tumor hemodynamic change. *Jpn J Gastroenterol* 88 : 1554-1565, 1991
13. Kudo M, Tochio H : Intranodular Blood Supply Correlates Well with Biological Malignancy Grade Determined by Tumor Growth Rate in Pathologically Proven Hepatocellular Carcinoma. *Oncology* 75 : 55-64, 2008
14. Schölmerich J : Is ultrasound-guided fine-needle biopsy effective for diagnosis of early HCC in liver cirrhosis? *Nat Clin Pract Gastroenterol* 2 : 16-17, 2005
15. Patel S, Bellon EM, Haaga J : Fat replacement of the exocrine pancreas. *AJR Am J Roentgenol* 135 : 843, 1980
16. Kim HJ, Byun JH, Park SH : Focal fatty replacement of the pancreas : usefulness of chemical shift MRI. *AJR Am J Roentgenol* 188 : 429, 2007