

CASE REPORT

Usefulness of artificial endocrine pancreas during resection of insulinoma

Kayo Hirose^{1,2}, Shinji Kawahito³, Naoji Mita³, Kazumi Takaishi⁴, Tomiya Kawahara³, Tomohiro Soga³, Toshiko Katayama³, Satoru Imura⁵, Yuji Morine⁵, Tetsuya Ikemoto⁵, Mitsuo Shimada⁵, Munehide Matsuhisa⁶, and Hiroshi Kitahata⁴

¹Department of Pharmacology, Institute of Health Biosciences, the University of Tokushima Graduate School, Tokushima, Japan, ²Department of Anesthesiology, Tokyo University Graduate School of Medicine, Tokyo, Japan, ³Department of Anesthesiology, Tokushima University Hospital, Tokushima, Japan, ⁴Department of Dental Anesthesiology, Institute of Health Biosciences, the University of Tokushima Graduate School, Tokushima, Japan, ⁵Department of Digestive and Pediatric Surgery, Tokushima University Hospital, Tokushima, Japan, ⁶Diabetes Therapeutics and Research Center, the University of Tokushima, Tokushima, Japan

Abstract : A 71-year-old woman had an episode of syncope due to hypoglycemia of 27 mg/dl. She was diagnosed with insulinoma and scheduled for laparoscopic enucleation along with the use of an artificial endocrine pancreas (STG-22, Nikkiso Co., Ltd., Tokyo, Japan). Anesthesia was maintained with sevoflurane and remifentanyl. Her blood glucose level was controlled using the artificial endocrine pancreas, which enabled continuous blood glucose monitoring and computer-operated glucose and insulin infusion to maintain the blood glucose level at a steady state. The target concentration of blood glucose was set at 80-120 mg/dl during surgery. Until removal of the tumor, the blood glucose level was kept at around 80-100 mg/dl. After removal of the tumor, the blood glucose level gradually increased, but it was kept in the normal range by the artificial endocrine pancreas. The artificial endocrine pancreas was useful to monitor and maintain blood glucose levels during and after the removal of insulinoma, without any hyper- or hypoglycemia. *J. Med. Invest.* 61 : 421-425, August, 2014

Keywords : *insulinoma, perioperative glucose management, artificial endocrine pancreas, anesthetic management, continuous blood glucose monitoring*

INTRODUCTION

Insulinoma is a tumor characterized by excessive

Received for publication April 14, 2014 ; accepted June 2, 2014.

Address correspondence and reprint requests to Shinji Kawahito, M.D., Ph.D., Department of Anesthesiology, Tokushima University Hospital, 3-18-15, Kuramoto, Tokushima 770-8503, Japan and Fax : +81-88-633-7182.

endogenous insulin secretion resulting in severe hypoglycemia (1, 2). Surgical resection of insulinoma causes deterioration of the plasma glucose level due to dramatic change of the insulin level by removing the tumorous source of excessive insulin production. Surgical stress is also well known to increase the plasma glucose level due to an increase in endogenous glucose production. It is, therefore, important to prevent hyperglycemia and hypoglycemia

during and after resection of insulinoma.

Recently, perioperative glycemic control using an artificial endocrine pancreas was reported (3-6). However, the use of the artificial endocrine pancreas in the perioperative period of pancreatic surgery has yet to spread widely or become established in Japan. We could successfully control and manage hypoglycemia and stress-induced hyperglycemia throughout the procedure, as well as hyperglycemic rebound after removal of the tumor, using an artificial endocrine pancreas.

CASE REPORT

A 71-year-old woman with insulinoma underwent laparoscopic enucleation of insulinoma, along with the use of an artificial endocrine pancreas (STG-22, Nikkiso Co., Ltd., Tokyo, Japan). Her height and body weight were 150 cm and 64.6 kg. She had an episode of syncope due to hypoglycemia of 27 mg/dl. Even though her blood glucose level dropped below 40 mg/dl, she had no symptoms of hypoglycemia, such as sweating palpitation or general fatigue. Insulinoma was strongly suspected from high immunoreactive insulin (IRI) of 17.2 μ U/ml during typical hypoglycemia of 35 mg/dl. Dynamic abdominal computed tomography scan demonstrated a hypervascular tumor of 12 mm diameter in the head of the pancreas. Selective arterial calcium injection into the gastroduodenal artery markedly increased serum IRI levels, suggesting the localization of insulinoma in the head of the pancreas.

After admission, blood glucose was monitored frequently to avoid hypoglycemia. Before the induction of anesthesia, peripheral venous access was established and initial vital monitoring was started using electrocardiogram, pulse oximeter and non-invasive blood pressure. Anesthesia was induced with propofol, remifentanyl and rocuronium bromide and maintained with air, oxygen, sevoflurane (1.0-2.0%), remifentanyl (0.1-0.5 μ g/kg/min) and rocuronium bromide. Then, the radial artery was catheterized to monitor arterial blood pressure and STG-22 was employed. The target concentration of blood glucose was set at 80-120 mg/dl during surgery. Intraoperative blood glucose level was monitored with STG-22 continuously and also checked every 30 minutes by another strategy.

At the beginning of laparoscopic surgery, blood glucose level was 105 mg/dl. When insulinoma was detected and enucleated under ultrasound guidance, the blood glucose level did not decrease in spite of tumor manipulation. Until removal of the tumor, the blood glucose level remained at around 80-100 mg/dl. Soon after resection of the mass, the blood glucose level was 80 mg/dl, but it gradually increased, which is a typical reaction after the removal of a tumor (hyperglycemic rebound) (Figure). However, it was kept in the normal range by exogenous insulin infusion. The operation time was 3 hours and 8 minutes, and the anesthesia time was 4 hours and 18 minutes.

After surgery, STG-22 was continuously used to control blood glucose until the next morning. The target concentration of blood glucose was set at

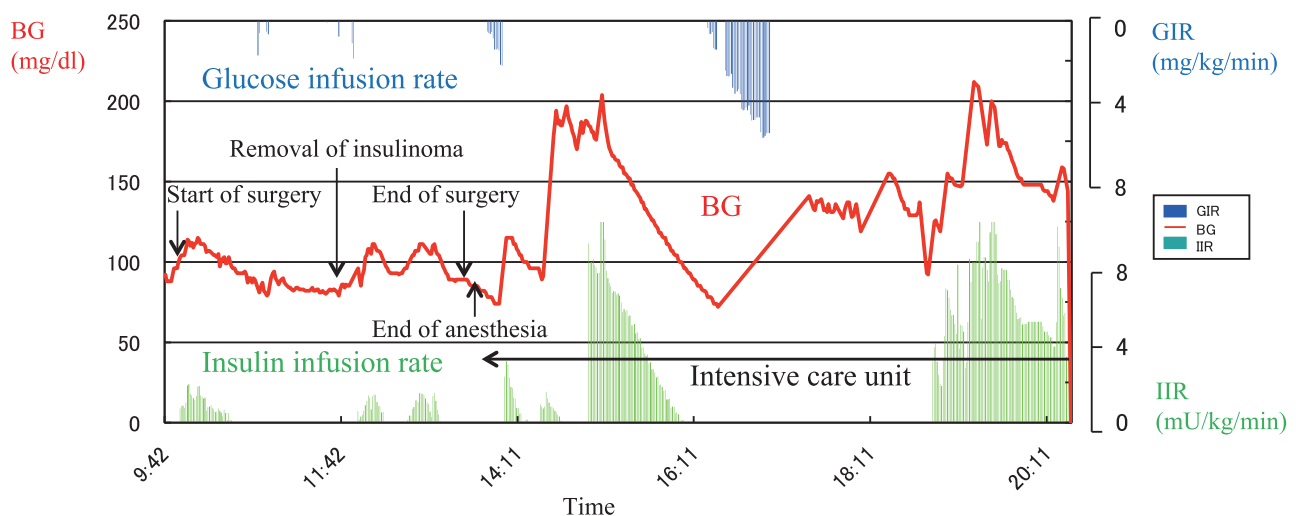


Figure : Alteration of blood glucose and the infusion rates of glucose and insulin in a patient with insulinoma treated using an artificial endocrine pancreas during and after surgery

BG : blood glucose, GIR : glucose infusion rate, IIR : insulin infusion rate

100-140 mg/dl after surgery. The glucose concentration increased to around 200 mg/dl in the ICU, but immediate administration of insulin suppressed the severe hyperglycemia. With the reduction in glucose concentration, the insulin infusion rate decreased and glucose infusion was started to avoid hypoglycemia (Figure). The perioperative course was uneventful. The artificial pancreas was shown to be safe and efficient in a patient with insulinoma during and after surgery.

DISCUSSION

Insulinoma is an endocrine tumor of the pancreatic β cells that is characterized by excessive endogenous insulin secretion resulting in severe hypoglycemia and unconsciousness. The incidence of insulinoma in the general population is about one to four per one million person-years. It is generally solitary and smaller than 2 cm in more than 90% of cases (1, 2). Surgical management especially enucleation is the first choice for insulinoma. However, in the case of malignancy or multiple tumors, progressive distal resection is required. After surgical resection (distal pancreatectomy) of the pancreas, 8-23% of patients develop pancreatogenic diabetes, which increases to 40-50% during follow-up (7).

The most important point in anesthetic management of insulinoma resection is perioperative glycemic control. The fluctuation of perioperative blood glucose during the resection of insulinoma is very intense. Until removal of the tumor, the blood glucose level tends to decrease. On the other hand, after removal of the tumor, blood glucose levels sometimes tend to increase (called hyperglycemic rebound) (8, 9). This was also observed in our patient. In addition, the postoperative blood glucose fluctuation is also very intense. In our case, the blood glucose level started to increase in the ICU, but only to a maximum of 200 mg/dl, and the level was controlled by appropriate insulin administration. Subsequently, the blood glucose level began to decrease, but hypoglycemia was avoided by appropriate glucose administration (minimum blood glucose value : around 75 mg/dl). In the ICU in particular, sudden glycemic control is critical, and use of a mild control algorithm is necessary.

We report a case of insulinoma in which an artificial endocrine pancreas was used during and after surgery. Intraoperative glucose management during resection of pancreas (7, 10, 11) or total

pancreatectomy (7, 12) using an artificial endocrine pancreas has previously been reported ; however, there are extremely few reports of the use of an artificial endocrine pancreas in perioperative care of insulinoma (13, 14). Pulver *et al.* (13) reported a case which artificial beta cell (Biostator, Miles Laboratories, Elkhart, IN) was utilized to maintain normal blood glucose in a patient who underwent partial pancreatectomy for removal of an insulinoma. However, this was reported a long time ago, it was used only during surgery, and the device used is no longer available. Manabe *et al.* (14) reported the anesthetic management of a 5-year-old patient with insulinoma. They attempted continuous blood glucose monitoring only using an artificial endocrine pancreas (STG-22), and did not use a closed-loop blood glucose control system. We performed not only monitoring but also glycemic control by automatic injection of glucose and insulin using a closed-loop system during and after surgery.

The human brain primarily uses glucose as its source of energy. Under normal conditions, the brain is unable to synthesize or store glucose and is thus exquisitely vulnerable to glucose deprivation (15). In the 1930s, Manfred Sakel introduced hypoglycemia as a therapy in psychiatry, as reported in the English literature in the late 1930s. From the treatment, it was discovered that, if a patient remained in a coma for longer than 30 minutes, the coma would be irreversible (16). A flat electroencephalogram was seen at blood glucose levels of 20 mg/dl or less (17). After 30-60 minutes of isoelectricity, neuronal damage develops in selective brain areas such as the cortex, the hippocampus and the caudoputamen, while other areas like the cerebellum and the brainstem are more resistant (18). Although the mechanisms underlying this selective vulnerability to hypoglycemic damage are unknown, an association with oxidative stress has recently been suggested (19). Anesthesiologists must avoid hypoglycemia during surgery.

On the other hand, stress-induced hyperglycemia and hyperglycemic rebound after the removal of tumor often occur during the resection of insulinoma. In addition, elevation of insulin resistance evoked by typical hyperinsulinemia and reduction of pancreatic parenchyma leads to postoperative hyperglycemia. Hyperglycemia can worsen a number of perioperative problems, including cardiac, neurologic and infectious complications (20). Prevention of hyperglycemia during and after surgery is also very important for patients with insulinoma.

To avoid hypo- or hyperglycemia, frequent monitoring of the blood glucose level is necessary during the resection of insulinoma. However, it is difficult to detect glycemic disorder from symptoms such as tachycardia or diaphoresis during anesthesia. It is thus ideal to use an artificial endocrine pancreas. In December 2007, our clinical team at Tokushima University initiated a clinical trial to evaluate the efficacy of the artificial endocrine pancreas for intraoperative patients (5). In this case, we used STG-22, which is a bedside-type artificial endocrine pancreas (3, 4). The Nikkiso Company developed the STG-22 unit in 1984 as an artificial endocrine pancreas, which was only a single device with a closed-loop system. Peripheral venous blood for glucose monitoring was sampled continuously at 2 ml/h. STG-22 is capable of measuring the blood glucose level continuously with its glucose sensor, and automatically infuses insulin and/or glucose to adjust the blood glucose level in accordance with a target glucose value, which is called a closed-loop system. The perioperative accuracy and reliability of continuous blood glucose monitoring during use of an artificial pancreas have been established, both intraoperatively (21) and postoperatively (22). In this case, STG-22 was shown to be safe and efficient in a patient with insulinoma during and after surgery, similarly to other reports.

The merits of closed-loop intensive insulin therapy using the artificial endocrine pancreas are the possibility of strict glycemic control, an absence of hypoglycemic attacks, reduced workload in spite of frequent blood glucose measurements, and a reduction in incidents. On the other hand, the demerits are high cost, problems associated with an insufficient quantity of blood obtained for monitoring, the need for a long preparation time, difficulty of operation, and limited duration of use, among others. However, we believe that an artificial pancreas will become a standard modality to achieve glycemic control in patients who need strict and safe glycemic control. Establishment of a new perioperative blood glucose control method with the aid of an artificial endocrine pancreas is urgently needed.

In conclusion, we used an artificial endocrine pancreas for insulinoma enucleation. The artificial endocrine pancreas (STG-22) was useful to monitor and maintain blood glucose levels during and after removal of the insulinoma without any hyper- or hypoglycemia.

CONFLICT OF INTEREST

No conflicts of interest declared.

REFERENCES

1. Grant CS : Insulinoma. *Best Pract Res Clin Gastroenterol* 19 : 783-798, 2005
2. Okabayashi T, Shima Y, Sumiyoshi T, Kozuki A, Ito S, Ogawa Y, Kobayashi M, Hanazaki K : Diagnosis and management of insulinoma. *World J Gastroenterol* 19 : 829-837, 2013
3. Hanazaki K, Nosé Y, Brunicardi FC : Artificial endocrine pancreas. *J Am Coll Surg* 193 : 310-322, 2001
4. Kono T, Hanazaki K, Yazawa K, Ashizawa S, Fisher WE, Wang XP, Nosé Y, Brunicardi FC : Pancreatic polypeptide administration reduces insulin requirements of artificial pancreas in pancreatectomized dogs. *Artif Organs* 29 : 83-87, 2005
5. Kawahito S, Kitahata H, Kitagawa T, Oshita S : Intensive insulin therapy during cardiovascular surgery. *J Med Invest* 57 : 191-204, 2010
6. Okada T, Kawahito S, Mita N, Matsuhisa M, Kitahata H, Shimada M, Oshita S : Usefulness of continuous blood glucose monitoring and control for patients undergoing liver transplantation. *J Med Invest* 60 : 205-212, 2013
7. Maeda H, Okabayashi T, Yatabe T, Yamashita K, Hanazaki K : Perioperative intensive insulin therapy using artificial endocrine pancreas in patients undergoing pancreatectomy. *World J Gastroenterol* 15 : 4111-4115, 2009
8. Schnelle N, Molnar GD, Ferris DO, Rosevear JW, Moffitt EA : Circulating glucose and insulin in surgery for insulinomas. *JAMA* 217 : 1072-1078, 1971
9. van Heerden JA, Edis AJ, Service FJ : The surgical aspects of insulinoma. *Ann Surg* 189 : 677-682, 1979
10. Okabayashi T, Nishimori I, Yamashita K, Sugimoto T, Maeda H, Yatabe T, Kohsaki T, Kobayashi M, Hanazaki K : Continuous postoperative blood glucose monitoring and control by artificial pancreas in patients having pancreatic resection : a prospective randomized clinical trial. *Arch Surg* 144 : 933-937, 2009
11. Hanazaki K : Tight glycemic control using an artificial endocrine pancreas may play an important role in preventing infection after pancreatic

- resection. *World J Gastroenterol* 18 : 3787-3789, 2012
12. Hanazaki K, Yatabe T, Kobayashi M, Tsukamoto Y, Kinoshita Y, Munekage M, Kitagawa H : Perioperative glycemic control using an artificial endocrine pancreas in patients undergoing total pancreatectomy : tight glycemic control may be justified in order to avoid brittle diabetes. *Biomed Mater Eng* 23 : 109-116, 2013
 13. Pulver JJ, Cullen BF, Miller DR, Valenta LJ : Use of the artificial beta cell during anesthesia for surgical removal of an insulinoma. *Anesth Analg* 59 : 950-952, 1980
 14. Manabe M, Morimatsu H, Egi M, Suzuki S, Kaku R, Matsumi M, Morita K : Anesthetic management of pediatric patients with insulinoma using continuous glucose monitoring (in Japanese with English abstract). *Masui (Jpn J Anesthesiol)* 58 : 757-759, 2009
 15. Zammitt NN, Frier BM : Hypoglycemia in type 2 diabetes : pathophysiology, frequency, and effects of different treatment modalities. *Diabetes Care* 28 : 2948-2961, 2005
 16. Auer RN : Hypoglycemic brain damage. *Metab Brain Dis* 19 : 169-175, 2004
 17. Auer RN, Olsson Y, Siesjö BK : Hypoglycemic brain injury in the rat. Correlation of density of brain damage with the EEG isoelectric time : a quantitative study. *Diabetes* 33 : 1090-1098, 1984
 18. Auer RN, Wieloch T, Olsson Y, Siesjö BK : The distribution of hypoglycemic brain damage. *Acta Neuropathol* 64 : 177-191, 1984
 19. Patočková J, Marhol P, Tůmová E, Krsiak M, Rokyta R, Stípek S, Crkivská J, Anđel M : Oxidative stress in the brain tissue of laboratory mice with acute post insulin hypoglycemia. *Physiol Res* 52 : 131-135, 2003
 20. Kawahito S, Kitahata H, Oshita S : Problems associated with glucose toxicity : role of hyperglycemia-induced oxidative stress. *World J Gastroenterol* 15 : 4137-4142, 2009
 21. Yamashita K, Okabayashi T, Yokoyama T, Yatabe T, Maeda H, Manabe M, Hanazaki K : The accuracy of a continuous blood glucose monitor during surgery. *Anesth analg* 106 : 160-163, 2008
 22. Yamashita K, Okabayashi T, Yokoyama T, Yatabe T, Maeda H, Manabe M, Hanazaki K : Accuracy and reliability of continuous blood glucose monitor in post-surgical patients. *Acta Anaesthesiol Scand* 53 : 66-71, 2009