

## CASE REPORT

# Efficacy of hip arthroscopy in the diagnosis and treatment of synovial osteochondromatosis : a case report and literature review

Kazuaki Mineta, Tomohiro Goto, Daisuke Hamada, Takahiko Tsutsui, Ichiro Tonogai, Naoto Suzue, Tetsuya Matsuura, Kosaku Higashino, Toshinori Sakai, Yoichiro Takata, Toshihiko Nishisho, Ryousuke Sato, Yuichiro Goda, Tadahiro Higuchi, Shingo Hama, Tetsuya Kimura, Akihiro Nitta, and Koichi Sairyo

*Department of Orthopedics, Institute of Health Biosciences, the University of Tokushima Graduate School, Tokushima, Japan*

**Abstract :** Here we report a rare case of synovial osteochondromatosis of the hip and provide a brief review of the literature. A 37-year-old woman was referred to our department with a 3-year history of right hip pain. At initial consultation, she complained of pain upon standing and when sitting down, occasional pain at rest and nocturnal pain in the right hip, and worsening of the pain at premenstruum. The range of motion of the affected hip was totally limited by pain. Plain radiography revealed a slightly calcified (or ossified) lesion at the acetabular fossa of the right hip. Computed tomography showed clusters of loose bodies filling the acetabular fossa. Synovial osteochondromatosis was suspected and she underwent hip arthroscopic surgery. Complete resection was performed using the lateral and anterior portals. Postoperatively, her symptoms disappeared entirely and she was discharged 4 days after surgery. The patient regained full range of motion of the right hip and follow-up CT revealed no remaining loose bodies in the right hip. Hip arthroscopy is considered to be effective for the diagnosis and treatment of synovial osteochondromatosis of the hip and is minimally invasive. *J. Med. Invest.* 61 : 436-441, August, 2014

**Keywords :** *synovial osteochondromatosis, hip joint, hip arthroscopy, minimally invasive surgery*

## INTRODUCTION

Synovial osteochondromatosis is a benign proliferative disorder of the synovial joint membrane that results in osteochondral loose bodies (1). The generally accepted pathogenesis is that these bodies are

formed by cartilaginous metaplasia of the synovium (2). It is well known that this condition affects the knee or elbow joint, but its occurrence in the hip is relatively uncommon (3). Since clinical symptoms of synovial osteochondromatosis of the hip are usually nonspecific and insidious, it is difficult to detect this condition during the early stages and it may progress over several years before being diagnosed on the basis of radiographic evidence of loose osseous bodies (4, 5).

In this report, we present a rare case of synovial osteochondromatosis of the hip with nonspecific

Received for publication May 8, 2014 ; accepted June 30, 2014.

Address correspondence and reprint requests to Tomohiro Goto, MD, PhD, Department of Orthopedics, Institute of Health Biosciences, the University of Tokushima Graduate School, 3-18-15 Kuramoto, Tokushima 770-8503, Japan and Fax : +81-88-633-0178.

symptoms and relatively unclear radiographic findings. Although the optimal treatment of either open or arthroscopic surgery is controversial, we performed hip arthroscopic surgery, which allowed complete removal of the lesions with a less invasive approach.

## CASE REPORT

A 37-year-old woman presented with pain and limited range of motion in the right hip joint. The pain had increased steadily over the past 3 years. She felt the pain upon standing and when sitting down. The pain worsened in the morning, sometimes at rest and during the nighttime, and also inexplicably at premenstruum. A precise diagnosis had not been made at several hospitals and she was referred to our department for further investigation.

Physical examination of the right hip revealed a limited range of motion, with flexion/extension of

110°/0°, abduction/adduction of 30°/20°, and external rotation/internal rotation of 45°/15°. Severe pain during external rotation was noted. The anterior impingement sign and Patrick test were positive. There was no tenderness or leg length discrepancy. The Japan Orthopedic Association (JOA) score was 62 (max. 100). Blood tests showed no signs of inflammation or infection.

Plain radiography revealed a slightly radiopaque lesion at the acetabular fossa in the right hip joint (Figure 1). Computed tomography (CT) with multiplanar reconstruction images showed clusters of intra-articular ossified loose bodies filling the acetabular fossa; there were no lesions in the peripheral compartment (Figure 2). Magnetic resonance imaging (MRI) showed slight joint effusion and no evidence of osteoarthritic changes. The ossified lesions at the acetabular fossa showed low signal intensities on T1-weighted images and mosaic patterns on T2-weighted and short inversion time inversion recovery (STIR) images (Figure 3). CT arthrography

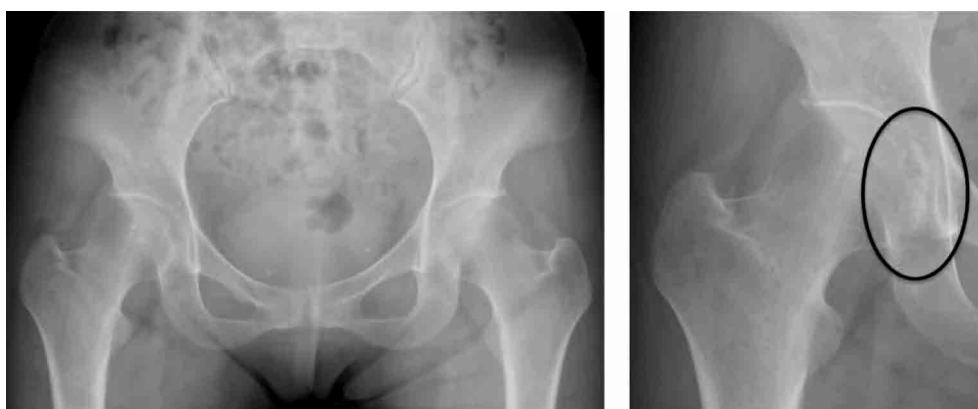

Figure 1 Plain anteroposterior radiographs reveal a radiopaque lesion in right hip joint space after careful searching.

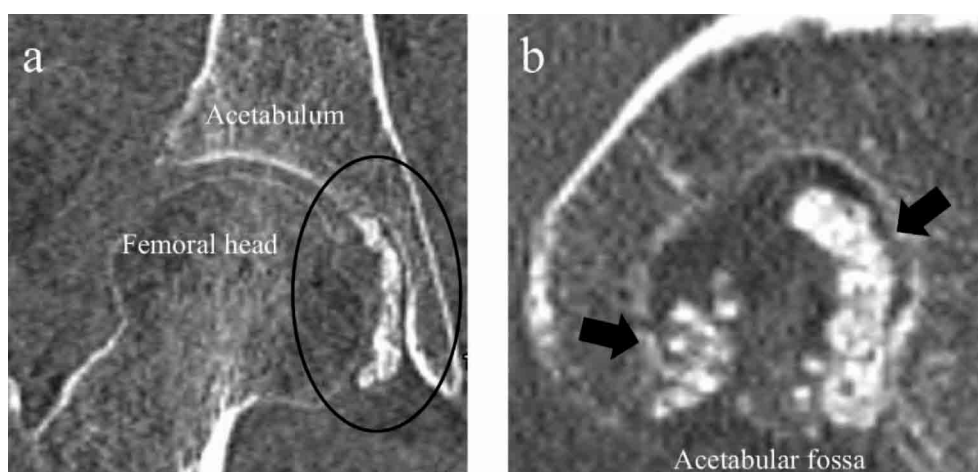
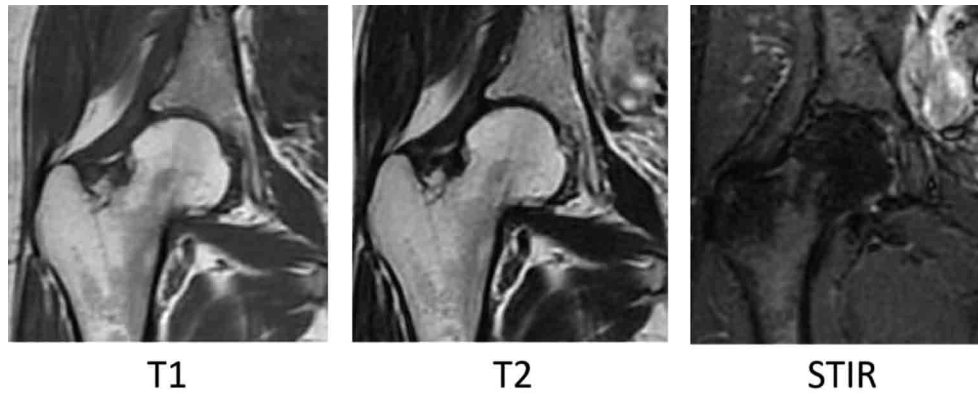


Figure 2 Coronal (a) and sagittal (b) CT images show intra-articular radiopaque loose bodies filling the right acetabular fossa (a : circle, b : gray arrow).

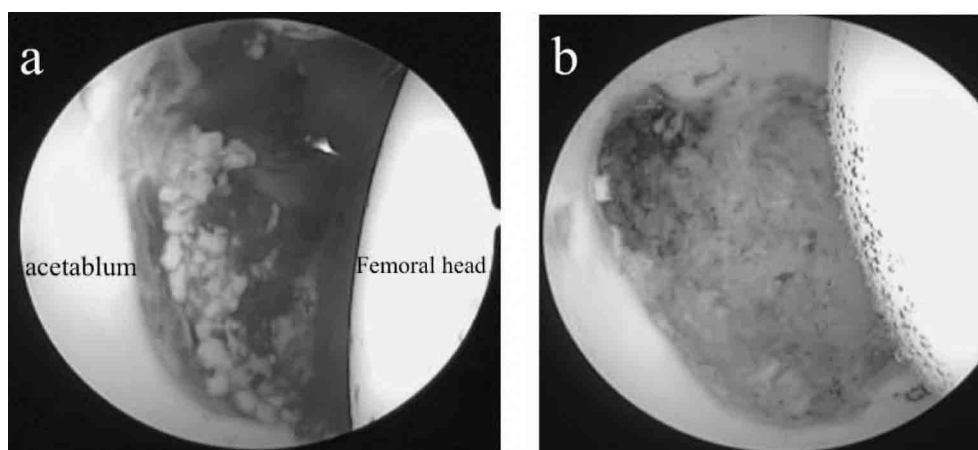


**Figure 3** MRI reveals slight joint effusion and no evidence of osteoarthritic changes. The ossified lesions at the acetabular fossa show low signal intensities on T1-weighted images and mosaic patterns on T2-weighted and short inversion time inversion recovery (STIR) images.

confirmed that the lesions including the osteochondral bodies were restricted to the central compartment. Synovial osteochondromatosis of the right hip was suspected from multiple intraarticular calcifications (ossifications) revealed by CT and we performed hip arthroscopic surgery for definitive diagnosis and treatment.

Under general anesthesia, the patient was placed in the supine position. A well-padded traction boot connected to a hip distractor was applied to the leg of the operative side. For surgery in the central compartment, the affected hip joint was distracted so that the joint space was widened by approximately 1 cm while being monitored with an image intensifier. The lateral portal was positioned directly over the superior aspect of the greater trochanter. Also under monitoring with the image intensifier, a 17-gauge spinal needle was inserted into the hip joint through the lateral portal and 30 ml of normal saline was injected into the hip joint. A guidewire was inserted into the guide needle and the guide

needle removed. A trocar was passed over the remaining guidewire and inserted to enlarge the lateral portal, and an arthroscope was then inserted to observe the lesions in the central compartment. To decrease the possibility of damage to the femoral artery and nerve, an anterior portal was modified to place slightly more lateral and distal; the traditional anterior portal located at the site of intersection of a sagittal line distally through the anterior superior iliac spine and a transverse line across the tip of the greater trochanter. At this time, the femoral artery was identified by palpation and marked to avoid damage to the femoral vessels and nerves. A 70° angled arthroscope was mainly used in the lateral portal, and instruments such as the probe, grasper, shaver and flexible adjuvant electrothermal device were inserted via the anterior portal. Hematoma, synovium pieces, and many millet-sized loose bodies were observed in the acetabular fossa and these were removed (Figure 4). No lesions were apparent in the peripheral compartment.



**Figure 4** Arthroscopic images of the right hip joint. Lateral portal view shows hematoma, synovium pieces, and many millet-sized loose bodies in the acetabular fossa (a), which were all removed (b).

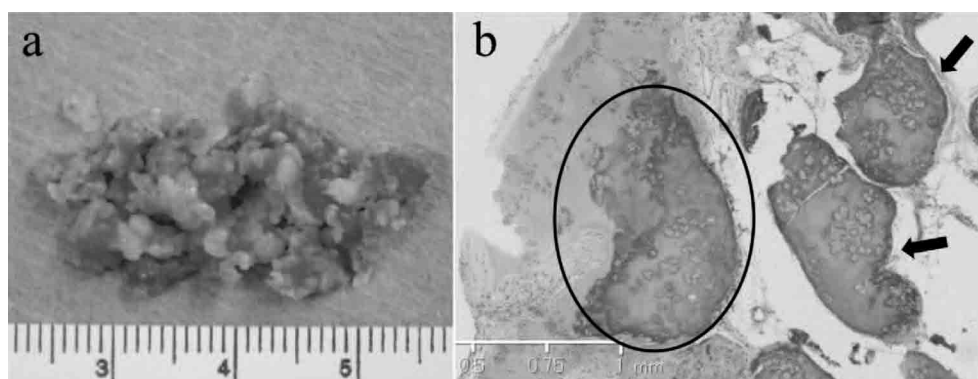
Histologic findings of the loose bodies revealed that osteocartilaginous nodules containing hyaline cartilage within focal areas were present beneath the synovial membrane and chondrocytes were clustered together in nodules. A diagnosis of synovial osteochondromatosis was made by histopathology (Figure 5).

The patient's postoperative course was uneventful and she was able to walk with full weight-bearing 1 day after the surgery. Her pain at rest and nocturnal pain disappeared immediately, and she was discharged 4 days after surgery. There were no complications including infection, thromboembolism, paresthesia, or peripheral neurologic deficits. At 1 year after surgery, she had regained the full range of motion of the right hip and JOA score was improved from 62 to 95, with no recurrence of symptoms. Follow-up CT confirmed no remaining loose bodies in the right hip joint (Figure 6).

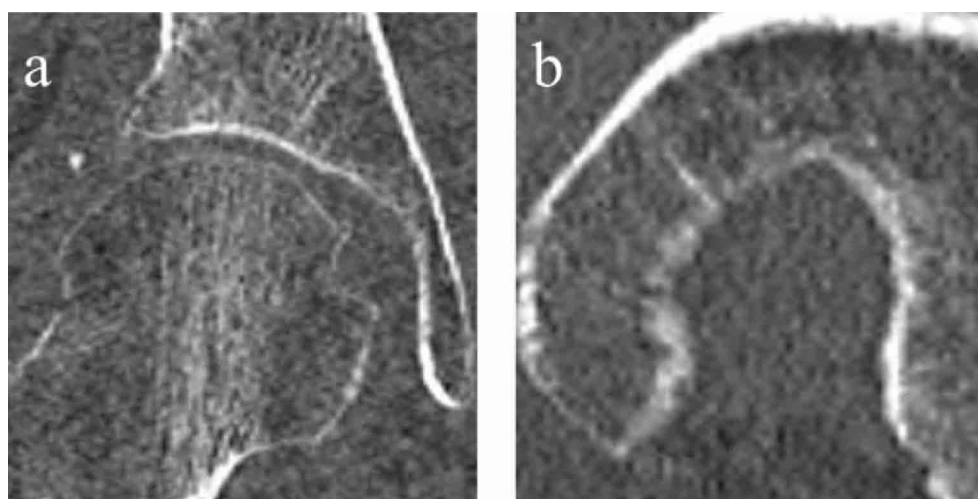
## DISCUSSION

Synovial osteochondromatosis is a rare benign condition characterized by synovial metaplasia and the formation of osteochondral bodies in the synovial cavity. Although it can occur in any synovial joint and most commonly the knee joint, involvement of the hip joint is relatively rare. Here, we reported a rare case of synovial osteochondromatosis of the hip where hip arthroscopy allowed for definitive diagnosis and less invasive treatment.

Synovial osteochondromatosis is difficult to diagnose and consequently treatment is usually delayed. The mean age at the time of diagnosis is from 34 to 40 years and the mean interval from symptom onset to reaching the diagnosis ranges from 30 to 38 months (6, 7); in our case, approximately 36 months were needed to reach a precise diagnosis. There are two main reasons for the delay in diagnosis. The first is that onset of synovial osteochondromatosis of the hip is insidious and the disease



**Figure 5** Gross findings of the loose bodies removed from the affected hip joint (a). Photomicrograph (b) shows osteocartilaginous nodules (black circle) containing hyaline cartilage within focal areas beneath the synovial membrane, and chondrocytes clustered together (black arrow) in nodules (hematoxylin and eosin, original magnification,  $\times 125$ ).



**Figure 6** Follow-up CT images (a : coronal, b : sagittal) show no loose bodies or evidence of recurrence.

progresses slowly with unspecific symptoms. In general, patients with synovial osteochondromatosis of the hip frequently have mechanical symptoms such as locking, catching, or crepitus and these symptoms aid in making the diagnosis. However, our patient did not have mechanical symptoms and had only nonspecific symptoms such as pain at rest, nocturnal pain and worsening of pain at premenstruum. The second reason for delay is the poor diagnostic rate of imaging studies. Loose bodies caused by synovial chondromatosis could be either ossified or non-ossified, and the latter remains notoriously elusive in imaging studies. Plain radiographs show the presence of loose bodies in only 50% of the cases (8). McCarthy and Lee reported an 80% false-negative rate for imaging studies including plain X-ray, bone scintigraphy, CT, and MRI (9). Marchie *et al.* reported a high rate (48%) of failed diagnosis at radiographic imaging assessment, including X-ray, CT and gadolinium-enhanced MRI (10). As the delay in diagnosis and treatment can cause progression of hip osteoarthritis, hip arthroscopy could have a critical role in prompt diagnosis, identifying the loose bodies and assessing the articular damage, including labral and cartilage injury.

Conventional treatment is open synovectomy and removal of the loose bodies with surgical dislocation of the femoral head (1). This procedure affords good outcomes, but its drawbacks are the invasiveness of surgery, long rehabilitation periods, and many major complications such as avascular necrosis of the femoral head, fracture of the femoral neck, and nerve injury (4, 11). By comparison, hip arthroscopy has fewer complications and offers the surgeon a minimally invasive technique to diagnose and treat synovial disorders of the hip (10). Hip arthroscopy permits rapid return to daily life after the surgery and a short rehabilitation period. Patients who underwent arthroscopic surgery for synovial osteochondromatosis were reported to be able, on average, to weight-bear and walk 2 days after the surgery and to be discharged 3.5 days (1). Our patient was able to walk with full weight-bearing after 1 day and was discharged after 4 days.

Several authors reported a relatively high recurrence rate after arthroscopic surgery, ranging from 30% to 39% (1, 12, 13) compared to that for open surgical synovectomy and removal of the loose bodies, ranging from 0% to 22.2% (14, 15). Lee *et al.* reported a lower recurrence rate of 16.7% and good patient satisfaction after arthroscopic surgery, but pointed out that the disadvantage of arthroscopic

surgery was the inability of the arthroscope to reach the anteroinferior and posteroinferior portions of the joint, so lesions located in these regions were likely to remain. They suggested an additional medial portal was useful for performing wider synovectomy and greater loose body removal at these sites (1). Moreover, it was also reported that in cases where loose bodies were located at the posterior or posterolateral region of the peripheral compartment, the loose bodies could not be removed completely by only arthroscopic surgery (1). In our case, we decided to perform arthroscopic surgery because the lesions were restricted to the acetabular fossa. During the surgery, the affected hip joint was distracted enough to reach the inferior portion of the acetabular fossa. Moreover, flexible instruments specifically designed for the hip, such as a radiofrequency heating probe with a flexible tip, allowed for significantly improved access to the deep inferior portions of the hip joint (16). Sufficient distraction with optimal joint space widening and the use of special equipment for hip arthroscopy enabled us to remove all of the lesions in our case. Although the risk of recurrence can be higher compared with open surgery, hip arthroscopy is considered to be an effective tool for early diagnosis and treatment of synovial osteochondromatosis of the hip.

## DECLARATION OF INTEREST

The authors report no conflict of interest.

## REFERENCES

1. Lee JB, Kang C, Lee CH, Kim P-S, Hwang DS : Arthroscopic treatment of synovial chondromatosis of the hip. *Am J Sports Med* 40 : 1412-1418, 2012
2. Mussey RD, Henderson MS : Osteochondromatosis. *J Bone Joint Surg Am* 31 : 619-627, 1949
3. Maurice H, Crone M, Watt I : Synovial chondromatosis. *J Bone Joint Surg Br* 70 : 807-811, 1988
4. Lim SJ, Chung HW, Choi YL, Moon YW, Seo JG, Park YS : Operative treatment of primary synovial osteochondromatosis of the hip. *J Bone Joint Surg Am* 88 : 2456-2464, 2006
5. Shpitzer T, Ganel A, Engelberg S : Surgery for synovial chondromatosis. 26 cases followed up

- for 6 years. *Acta Orthop Scand* 61 : 567-569, 1990
6. Zini R, Longo UG, de Benedetto M, Loppini M, Carraro A, Maffulli N, Denaro V : Arthroscopic management of primary synovial chondromatosis of the hip. *Arthroscopy* 29 : 420-426, 2013
  7. Lin RC, Lue KH, Lin ZI, Lu KH : Primary synovial chondromatosis mimicking medial meniscal tear in a young man. *Arthroscopy* 22 : 803.e1-3, 2006
  8. Christensen JH, Poulsen JO : Synovial chondromatosis. *Acta Orthop Scand* 46 : 919-925, 1975
  9. McCarthy JC, Lee J : Hip arthroscopy : indications and technical pearls. *Clin Orthop Relat Res* 441 : 180-187, 2005
  10. Marchie A, Panuncialman I, McCarthy JC : Efficacy of hip arthroscopy in the management of synovial chondromatosis. *Am J Sports Med* 39 : 126-131, 2011
  11. Ganz R, Gill TJ, Gautier E, Ganz K, Krügel N, Berlemann U : Surgical dislocation of the adult hip a technique with full access to the femoral head and acetabulum without the risk of avascular necrosis. *J Bone Joint Surg Br* 83 : 1119-1124, 2001
  12. Boyer T, Dorfmann H : Arthroscopy in primary synovial chondromatosis of the hip : description and outcome of treatment. *J Bone Joint Surg Br* 90 : 314-318, 2008
  13. Kim SJ, Choi NH, Kim HJ : Operative hip arthroscopy. *Clin Orthop Relat Res* 353 : 156-165, 1998
  14. Schoeniger R, Naudie DDR, Siebenrock KA, Trousdale RT, Ganz R : Modified complete synovectomy prevents recurrence in synovial chondromatosis of the hip. *Clin Orthop Relat Res* 451 : 195-200, 2006
  15. Witwity T, Uhlmann RD, Fischer J : Arthroscopic management of chondromatosis of the hip joint. *Arthroscopy* 4 : 55-56, 1988
  16. Kelly BT, Williams RJ, Philippon MJ : Hip arthroscopy : current indications, treatment options, and management issues. *Am J Sports Med* 31 : 1020-1037, 2003