

CASE REPORT

Cytological analysis of glycogen-rich carcinoma of the breast : report of two cases

Nobuo Satake^{*}, Hisanori Uehara^{*}, Nobuya Sano[†], Takayuki Kubo[†], Mitsunori Sasa[‡], and Keisuke Izumi^{*}

^{*}Department of Molecular and Environmental Pathology, [†]Division of Surgical Pathology, University Hospital, The University of Tokushima School of Medicine, Tokushima, Japan ; and [‡]Director of Tokushima Breast Care Clinic, Tokushima, Japan

Abstract : Background : Glycogen-rich carcinoma is a rare special histologic subtype of breast cancer and its incidence is estimated to be 1.4% in breast malignancies. However, its precise characteristics in cytological specimens have not yet been fully clarified.

Case : Fifty-nine-year-old and 53-year-old women underwent fine-needle aspiration biopsy cytology (FNABC) of a breast tumor, confirming malignancy. A mastectomy with axillary dissection was performed. Cytologically, a moderate amount of eosinophilic, finely granular cytoplasm was seen in the majority of the tumor cells, however, foamy and vacuolated cytoplasm was noted in some tumor cells. Histologically, the tumor cells of both cases had clear and granular cytoplasm, which showed a positive reaction with periodic acid-Schiff, eliminated by diastase.

Conclusion : While clear cytoplasm in the tumor cells in the FNABC seemed to be a pivotal cytological characteristic of glycogen-rich carcinoma, it may not be a major component of cytological specimens. Routine periodic acid-Schiff staining may be required to diagnose glycogen-rich carcinoma in cytological methods. J. Med. Invest. 49 : 193-196, 2002

Keywords : breast, fine-needle aspiration biopsy cytology, glycogen-rich carcinoma, c-erbB-2, cytology

INTRODUCTION

Glycogen-rich carcinoma (GRC) is a rare special histologic subtype of breast cancer, comprising 1.4% of breast malignancies(1). The clear cytoplasm observed in histological specimens is caused by the extraction of water-soluble glycogen during histological processing. We reviewed the cytological findings in two cases, which were histologically diagnosed by surgically resected specimens.

Received for publication June 14, 2002 ; accepted July 11, 2002.

Address correspondence and reprint requests to Nobuo Satake, Department of Molecular and Environmental Pathology, The University of Tokushima School of Medicine, Kuramotocho, Tokushima 770-8503, Japan and Fax : +81-88-633-7067.

CASE REPORT

Case 1 : A 59-year old woman had complained of a bloody nipple discharge and a palpable mass in her right breast for three months. Case 2 : A 53-year old woman had noticed a mass in her left breast, and the tumor had gradually enlarged. They visited Tokushima Breast Care Clinic and received ultrasonography and mammography. Fine-needle aspiration biopsy cytology (FNABC) revealed malignant cells from their lesions. A mastectomy with axillary dissection was performed at another institution.

CYTOLOGICAL FINDINGS

On a hemorrhagic background, small clusters of atypical cells were identified in both cases. The tumor cells had a high N/C ratio and large and polygonal nuclei with prominent nucleoli (Figs. 1A-1D). A moderate amount of eosinophilic, finely granular cytoplasm was observed in most of the tumor cells. However, some were rich in foamy and vacuolated cytoplasm. Mitotic figures were infrequent.

MACROSCOPIC FINDINGS

The tumor of Case 1 consisted of many solid and whitish yellow nodules measuring a maximum of 1 cm. Some nodules were noted to extend into the surrounding adipose tissue. The gross findings of Case 2 did not differ from those of the usual invasive carcinoma of the breast. The tumor measured 2.5 × 2.3 × 2.0 cm, a whitish-yellow solitary mass with irregular margins. Necrosis, bleeding and infarction were not prominent in either case.

HISTOLOGICAL AND IMMUNOHISTOCHEMICAL FINDINGS

The following stains and immunohistochemical examinations were performed: hematoxylin and eosin (HE), periodic acid-Schiff (PAS) with and without diastase pretreatment, alcian blue, mucicarmine; Cam 5.2 (cytokeratin) (BECTON, prediluted), AE1/AE3 (cytokeratin) (DAKO ×50), epithelial membrane antigen (EMA) (clone: E 29; DAKO, ×100), desmin (DAKO, ×50), vimentin (DAKO, ×150), carcinoembryonic antigen (CEA) (polyclonal; DAKO, ×50), estrogen receptor (DAKO, ×50) and c-erbB-2 (clone: AO485; DAKO, ×800). Immunohistochemical staining was carried out with DAKO LSAB kit.

The tumor cells of both cases had mostly clear and granular cytoplasm, small and hyperchromatic nuclei and prominent nucleoli (Figs. 1E-1G). The cytoplasmic granular staining by PAS was abolished by pretreatment with diastase. The tumors showed both intraductal and invasive growth patterns. Although a comedo pattern was evident in both cases, no cribriform pattern was observed in either of the cases. Alcian blue and mucicarmine failed to show mucus in the tumor cells in either case. The tumor had four and seventy mitotic figures per 10 high power fields (HPFs) in Cases 1 and 2, respectively.

Immunohistochemically, the tumor cells in both cases were positive for Cam 5.2, AE 1/AE 3, but negative for vimentin, desmin and estrogen receptor. CEA was weakly positive in Case 1, but negative in Case 2. Faint or barely perceptible membrane staining of c-erbB-2 in more than 10% of the tumor cells was observed in both cases (Fig. 1H).

DISCUSSION

GRC of the breast, a rare histologic subtype originally reported by Hull *et al.* in 1981, is defined when 90% or more tumor cells have clear cytoplasm containing glycogen in histological specimens (2-4). Histologically, our cases were consistent with the definition. In the records of Tokushima Breast Care Clinic, between 1996 and 2001, two of 217 (0.9 percent) cases of breast carcinoma were GRC.

Although rare, the cytologic findings of GRC have been described in a few case reports. Satoh *et al.* reported that tumor cells with various nuclear atypia, small round or ovoid nuclei and abundant, clear cytoplasm were identified in FNABC(4). Borislav *et al.* reported that papillary cell groups and single tall columnar cells with apical cytoplasmic projections were contained in the aspirate(5). Although foamy and vacuolated cytoplasm could be seen in some tumor cells, we diagnosed both cases as 'simple' adenocarcinoma. With the PAS reaction, the accumulation of glycogen may be easily demonstrated by cytology. In our laboratory, routine cytological screening of aspiration biopsies of the breast has been performed only by standard Papanicolaou staining.

The differential diagnosis of GRC includes mammary carcinomas with clear or vacuolated cytoplasm, and lipid rich carcinoma. The presence of lipid cannot be demonstrated by cytology because aspiration biopsy smears were immediately fixed in 95% ethanol. The presence of lipid can be demonstrated in frozen sections of fresh tissue or electron microscopy.

The prognosis of glycogen-rich carcinoma were described in many reports. In the reported cases, 14 of 35 patients (forty percents) of invasive glycogen-rich carcinomas died. Metastasis in the lymph nodes were observed in 17 patients (49 percents). The prognosis of glycogen-rich carcinoma were reported to be worse(6). The patients of case 1 and 2 are now well and post-operative regular checkup are necessary.

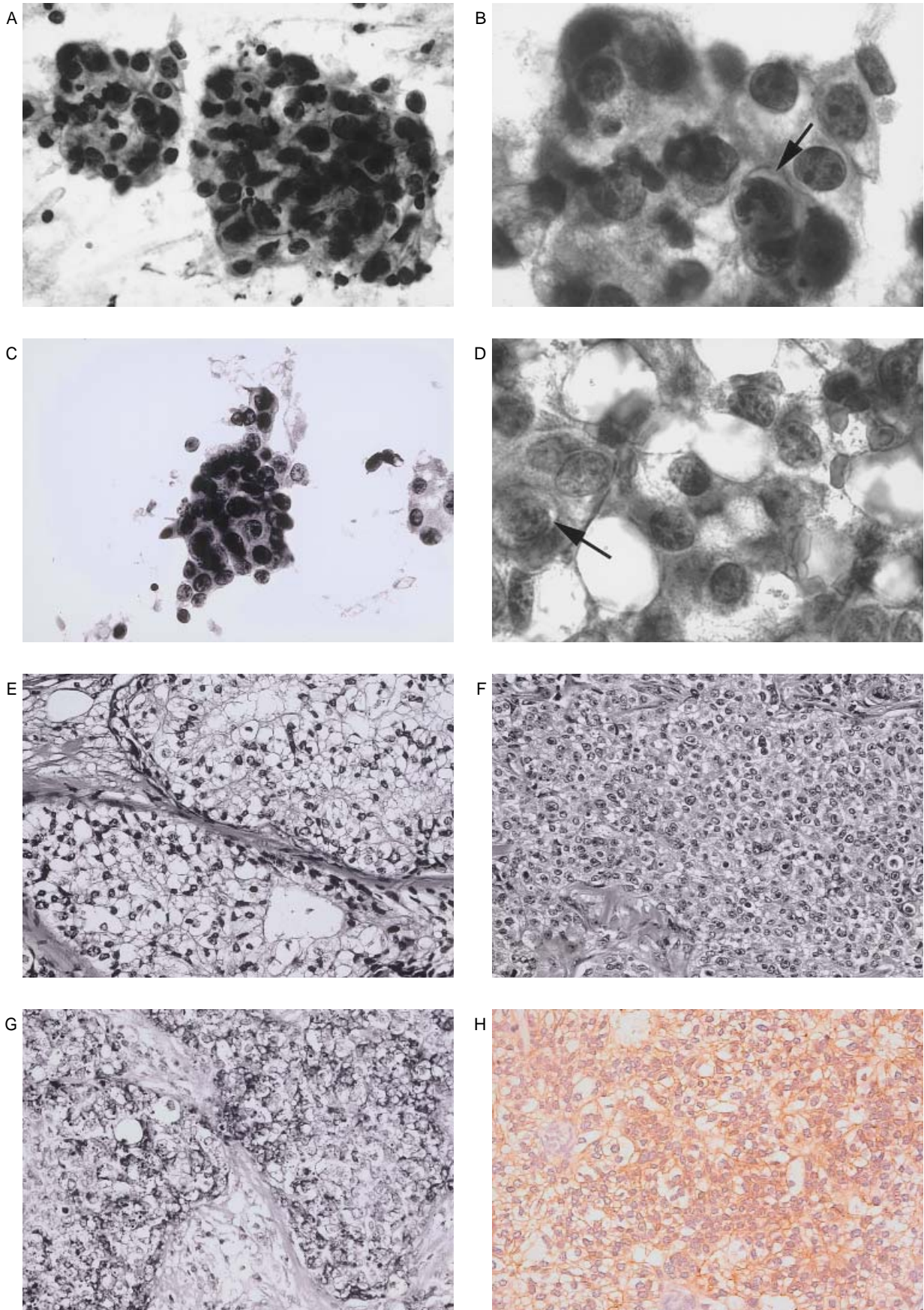


Figure 1 : Cytological and histological findings. A, B (Case 1), C, D (Case 2) : Aspiration cytology. In a hemorrhagic background, tumor cells with polygonal nuclei and prominent nucleus were observed. Clear cytoplasm (arrow) was seen in some tumor cells. E (Case 1) : The tumor was composed of solid alveolar proliferating clear cells. F (Case 2) : The tumor was composed of solid alveolar proliferating granular cells. G (Case 2) : The PAS reaction revealed abundant PAS-positive, diastase-digestible material in the cytoplasm in both cases. H (Case 1) : The membrane of the tumor cells was weakly positive for c-erbB-2.

The c-erbB-2 (HER2/neu) proto-oncogene encodes a receptor protein with a tyrosine kinase domain that shows extensive homology with epidermal growth factor receptor (EGFR) (7, 8). HER 2/neu proto-oncogene is amplified in 25 to 30% of primary breast carcinomas(9) and HER 2/neu overexpression is associated with a more aggressive potential and shortened survival(10). As far as we know, the immunohistochemical features of c-erbB-2 proto-oncogene in GRC have not been reported.

Estrogen receptor (ER) plays an important role in the biology of breast cancer and is accepted as a good prognostic marker. Estrogen receptor was positive in the case reported by Hull *et al.* (2) and among four invasive carcinoma cases reported by Hayes *et al.*, two cases were positive and the other two were negative(11). The positive rate of ER in 15 cases reported by Fujino *et al.* was 53%(6). However, the tumor cells were negative for ER in our two cases.

In summary, it may be difficult to diagnose GRC by FNABC, particularly when the cytological specimens are processed promptly. Clear cell changes caused by glycogen and other substances are often observed histologically in ordinary intraductal and invasive ductal carcinomas. Since there was a poorer overall prognosis for GRC than for ordinary ductal carcinoma and the prominent features could not be detected by ultrasound examination and mammography, diagnosing GRC in cytological specimens may be of significance. In this concern, PAS reaction (with or without diastase digestion) in addition to the standard Papanicolaou stain may be necessary in routine cytological screening of aspiration biopsies of the breast.

ACKNOWLEDGEMENTS :

We are grateful to Kumiko Fujii, Toshio Yamaguchi (Department of Molecular and Environmental Pathology, The University of Tokushima School of Medicine), Aki Katsura (Division of Surgical Pathology, University Hospital, The University of Tokushima School of Medicine) for technical assistance.

REFERENCES

1. Rosen PP, Obermann H : Tumors of the mammary gland. Atlas of tumor pathology. Vol.7. Armed Forces Institute of Pathology, Washington, DC, 1993, pp. 240-242
2. Hull MT, Priest JB, Broadie TA, Ransburg RC, McCarthy LJ : Glycogen-rich clear cell carcinoma of the breast : a light and electron microscopic study. *Cancer* 48 : 2003-2009, 1981
3. Toikkanen S, Joensuu H : Glycogen-rich clear-cell carcinoma of the breast : a clinicopathologic and flowcytometric study. *Human Pathology* 22 : 81-83, 1991
4. Satoh F, Umemura S, Itoh H, Miyajima Y, Tokuda Y, Tajima T, Osamura RY: Fine needle aspiration cytology of glycogen-rich clear cell carcinoma of the breast. A case report. *Acta Cytol* 42 : 413-418, 1998
5. Alexiev BA : Glycogen-rich clear cell carcinoma of the breast : report of a case with fine-needle aspiration cytology and immunocytochemical and ultrastructural studies. *Diagn Cytopathol* 12 : 62-66, 1995
6. Fujino S, Tezuka N, Sawai S, Konishi T, Inoue S, Kato H, Mori A, Okabe H : Glycogen-rich Clear Cell Carcinoma of the Breast : A Case Report and Review of the Literature. *Breast Cancer* 3 : 205-208, 1996
7. King CR, Kraus MH, Aaronson SA : Amplification of a novel v-erbB-related gene in a human mammary carcinoma. *Science* 229 : 974-976, 1985
8. Yamamoto T, Ikawa S, Akiyama T, Semba K, Nomura N, Miyajima N, Saito T, Toyoshima K : Similarity of protein encoded by the human c-erbB-2 gene to epidermal growth factor receptor. *Nature* 319 : 230-234, 1986
9. Slamon DJ, Godolphin W, Jones LA, Holt JA, Wong SG, Keith DE, Levin WJ, Stuart SG, Udove J, Ullrich A, Press MF : Studies of the HER-2/neu proto-oncogene in human breast and ovarian cancer. *Science* 244 : 707-712, 1989
10. Tsuda H, Hirohashi S, Shimosato Y, Hirota T, Tsugane S, Yamamoto H, Miyajima N, Toyoshima K, Yamamoto T, Yokota J, Yoshida T, Sakamoto H, Terada M, Sugimura T : Correlation between long-term survival in breast cancer patients and amplification of two putative oncogene-coamplification units : hst-1/int-2 and c-erbB-2/ear-1. *Cancer Res* 49 : 3104-3108, 1989
11. Hayes MMM, Seidman JD, Ashton MA : Glycogen-rich clear cell carcinoma of the breast. A clinicopathologic study of 21 cases. *Am J Surg Pathol* 19 : 904-911, 1995