

## CASE REPORT

# Arterial infusion chemotherapy for the patient of unresectable pancreatic carcinoma with multiple liver metastases : a case report

Masahiko Fujii, Hidenori Miyake, Katsuya Sasaki, Toshihide Takagi,  
Kazuhito Takamura, and Seiki Tashiro

*Department of Digestive Pediatric Surgery, The University of Tokushima School of Medicine,  
Tokushima, Japan*

**Abstract : Introduction : Despite various treatment trials for unresectable pancreatic carcinoma with liver metastases, the outcome has not been satisfactory. This paper reports a case of pancreatic carcinoma with multiple liver metastases that responded well to arterial infusion chemotherapy. Case report : A 65-year-old male was diagnosed with multiple liver tumors, and needle biopsy revealed adenocarcinoma. With endoscopic ultrasonography, a tumor in the pancreatic head was detected, and pancreatic carcinoma with multiple liver metastases was diagnosed. He received arterial infusion chemotherapy : cisplatin at a dose of 10mg/body/day and 500mg/body/day of 5-fluorouracil. After 14days administration, liver metastases had decreased in number and size, but thereafter, because of hepatic arterial occlusion, the same dose of drugs was administered intravenously. The patient was discharged from the hospital and was given chemotherapy 3 days a week on an outpatient basis. Although the chemotherapy was effective, it was stopped because of severe general fatigue 5 months after discharge. His general status continued to gradually worsen, and he died 12 months after diagnosis. Conclusions : Prognosis of pancreatic carcinoma with liver metastases is poor ; however, transarterial infusion chemotherapy may be effective to improve the prognosis and quality of life of the patients. J. Med. Invest. 50 : 199-202, 2003**

**Keywords :** *pancreatic carcinoma, arterial infusion chemotherapy, liver metastases*

## INTRODUCTION

Previous clinical trials for the detection and treatment of small pancreatic carcinoma have shown the possibility of improved prognosis ; however, at the time of diagnosis, only 10-11.6% of the patients can be given a resection (1, 2). Moreover, in many cases, despite the smallness of the primary lesion, liver metastases were detected. Though the outcome of a patient with liver metastases has not been satisfactory, some

recent studies have reported the possibility of improved prognosis by modified chemotherapy. Among them, arterial infusion chemotherapy has been reported to be effective for the treatment of liver metastases (3-5). This study reports a case of pancreatic carcinoma with multiple liver metastases that responded well to transarterial infusion chemotherapy.

## CASE REPORT

A 65-years-old male, diagnosed with multiple liver tumors, visited our hospital. He was symptom-free, and physical examination revealed no abdominal tumor or signs of jaundice. Laboratory examinations showed a slight elevation of liver function tests : asparate ami-

---

Received for publication January 21, 2003 ; accepted March 1, 2003.

Address correspondence and reprint requests to Masahiko Fujii, M.D., Department of Digestive Pediatric Surgery, The University of Tokushima School of Medicine, Kuramoto-cho Tokushima 770-8503, Japan and Fax : +81-88-633-9277.

notransferase (AST); 43 IU/L (normal range; 10-35 IU/L), alanine aminotransferase (ALT); 50 IU/L (normal range; 15-40 IU/L), alkaline phosphatase (ALP); 420 IU/L (normal range; 81-231 IU/L) and gamma-glutamyl transpeptidase (gamma-GTP); 241 (normal range; <60 IU/L). There were no elevations of tumor markers: alpha fetoprotein (AFP), carbohydrate antigen (CA) 19-9 and carcinoembryonic antigen (CEA).

### Diagnostic images

An abdominal ultrasonography detected multiple liver tumors, the largest being 8×8 cm in diameter. A contrast enhanced computed tomography (CE-CT) showed multiple low-density tumors in the liver (Fig. 1a), and a low-density mass 2 cm in diameter, in the pancreatic head (Fig. 1 b). Endoscopic retrograde cholangiopancreatography (ERCP) showed obstruction of the main pancreatic duct at the head of pancreas (Fig. 2a). Endoscopic ultrasonography detected a hypoechoic mass 3×2 cm in diameter in the pancreatic head (Fig. 2b). Celiac angiography showed multiple hypervascular tumors in the liver (Fig. 3).

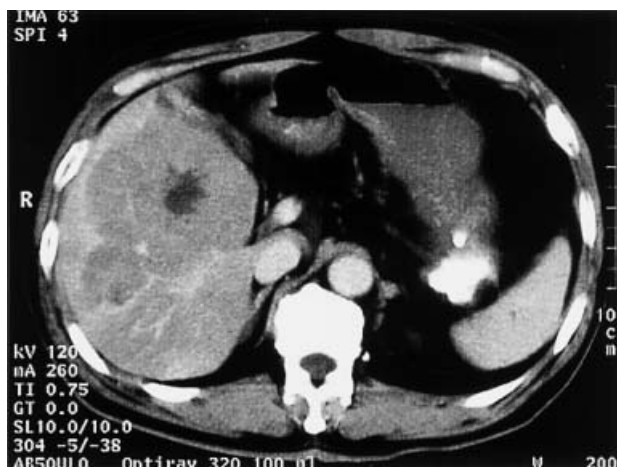


Fig. 1a. CE-CT showed multiple low-density tumors in the liver.

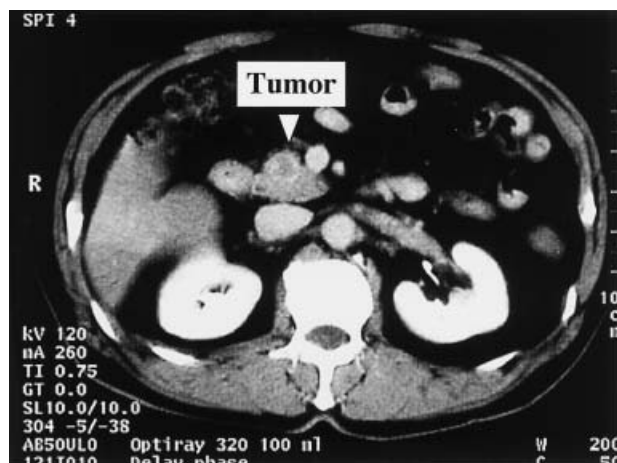


Fig. 1b. CE-CT revealed a low-density mass 2cm in diameter in the pancreatic head.

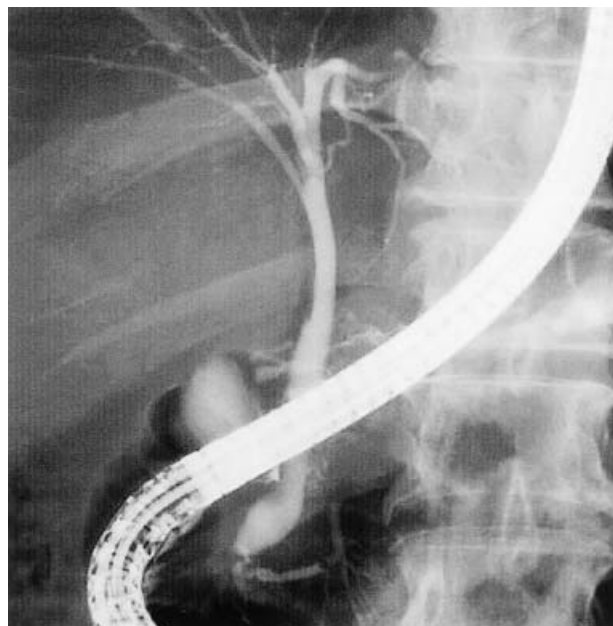


Fig. 2a. ERCP showed obstruction of the main pancreatic duct at the head of pancreas.

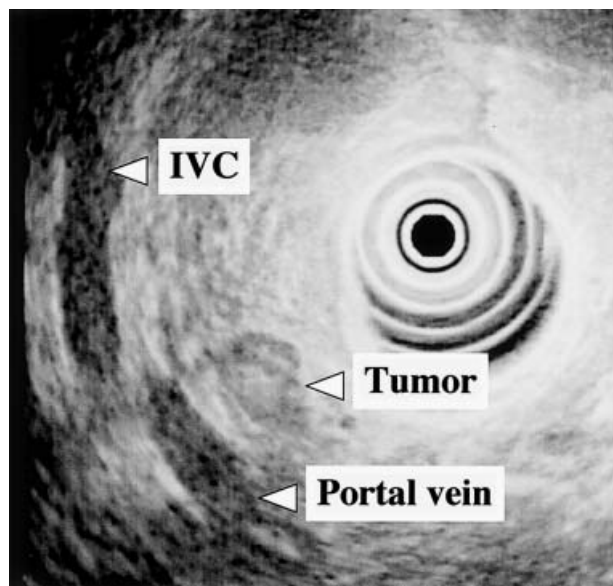


Fig. 2b. Endoscopic ultrasonography detected a hypoechoic mass 3×2 cm in diameter in the pancreatic head.

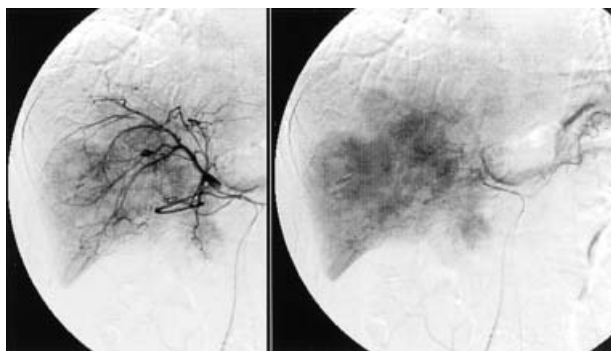


Fig. 3. Celiac angiography showed multiple hypervascular tumors in the liver.

US guided fine needle aspiration biopsy of the liver tumor revealed adenocarcinoma, and then pancreatic carcinoma with multiple liver metastases was diagnosed.

#### Therapeutic regimen

A catheter was placed in the common hepatic artery for arterial infusion chemotherapy via the right femoral artery, and then the gastroduodenal artery and right gastric artery were embolized with the microcoils. The catheter was connected to the port implanted in the subcutaneous space of the right lower abdomen. The patient received 5-fluorouracil (5-FU) and cisplatin (CDDP) combination chemotherapy for 14 days (5-FU at a dose of 500mg/day and CDDP of 10mg/day. Total dose : 5-FU ; 3500 mg, CDDP ; 140 mg). After 14 days administration, because of hepatic arterial occlusion, the same dose of CDDP and 5-FU were administered intravenously for 14 days until his discharge (Total dose : 5-FU ; 3500 mg, CDDP ; 140 mg). At the same time, the tumor in the pancreatic head was irradiated with total 50 Grays (2 Grays/fraction per day).

#### Images after arterial infusion

After 14 days administration, CE-CT revealed a decrease of liver metastases in number and size (Fig. 4a), and a reduction in the size of the pancreatic tumor (Fig. 4 b).

#### Clinical course after discharge

The patient was discharged from the hospital and given chemotherapy intravenously 3 days a week on an outpatient basis. Although the chemotherapy was effective, it was stopped because of severe general fatigue 5 months after discharge. CE-CT showed no sign of progression of liver and pancreatic tumors, but ascites had appeared. His general status contin-

ued to gradually worsen ; however, he could remain at home. The patient died 12 months after diagnosis because of peritonitis carcinomatosa.

## DISCUSSION

The prognosis and outcome of patients with pancreatic carcinoma still remain poor, despite various trials. One of the major reasons for these unsatisfactory results is its tendency to cause liver metastases. The incidence of liver metastases from pancreatic carcinoma was 27.4% at diagnosis (2), and 63% to 78% at autopsy (6). Moreover, in 50-62% of the patients after operations or chemotherapies, liver metastasis was the reason for therapeutic failure(2).

Recently, hepatic arterial infusion chemotherapy was reported as an effective treatment for liver metastases. Furuse *et al.* (4) treated liver metastases from pancreatic carcinoma using hepatic arterial infusion with 5-FU, and reported higher response rates than venous infusion, but no improvement of survival (the median survival time ; 15.9 weeks). Also, Suzuki *et al.* (5) reported a case of percutaneous isolated hepatic perfusion after local resection ; however, despite a distinct regression of liver metastases, the patient died 9 months after diagnosis. On the other hand, Homma *et al.* (3) administered 5-FU and CDDP via a catheter placed in the splenic and common hepatic artery after hemodynamic change, and then the mean survival period was improved ( $16.25 \pm 8.35$  months). In our patient, although the primary pancreatic carcinoma was small in size and there was no evidence of local invasion, metastatic liver tumors were very large and multiple. Then, liver metastases were regarded as a prognostic factor, and hepatic arterial infusion

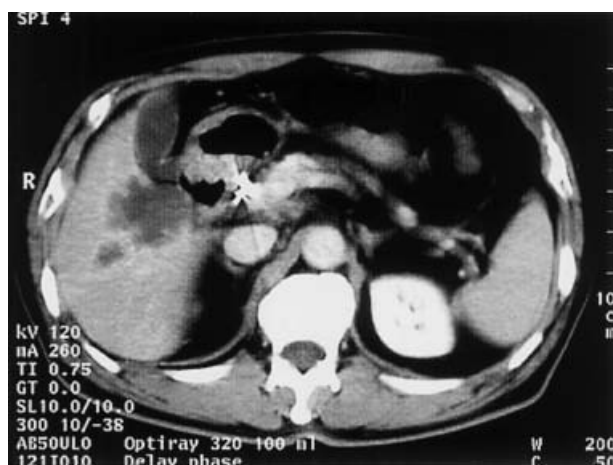


Fig. 4a. CE-CT revealed decrease of liver metastases in number and size after 14 days administration.

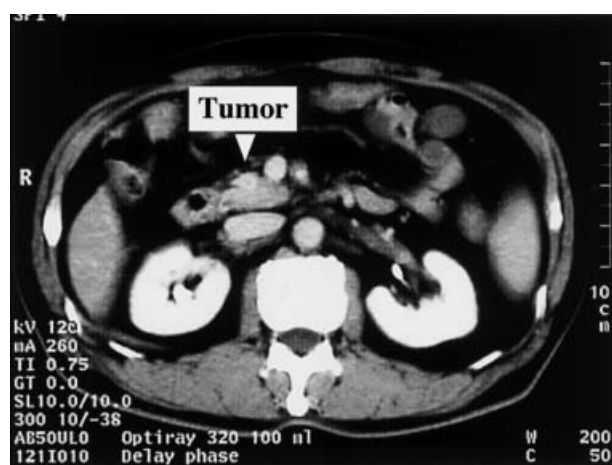


Fig. 4b. Pancreatic tumor was reduced after 14 days administration.

chemotherapy with radiation was selected for the primary pancreatic carcinoma. Liver tumors decreased in number and size, and no progression was observed throughout the follow-up period even after occlusion of the hepatic artery. Although Furuse *et al.* (4) pointed out that hepatic arterial occlusion during arterial chemotherapy would be responsible for the rapid progression of liver metastases, systemic chemotherapy after arterial occlusion may contribute to the improvement of the prognosis.

After discharge, the patient received systemic chemotherapy on an outpatient basis, and he could remain at home without severe side effects. In conclusion, transarterial infusion chemotherapy and subsequent systemic chemotherapy may be effective for the treatment of patients with pancreatic carcinoma with liver metastases, and moreover, may improve the quality of life of the patient.

## REFERENCES

1. Connolly MM, Dawson PJ, Michelassi F, Moosa AR, Lowenstein F : Survival in 1001 patients with carcinoma of the pancreas. *Ann Surg* 206 : 366-73, 1987
2. Muchmore JH, Preslan JE, George WJ : Regional chemotherapy for inoperable pancreatic carcinoma. *Cancer* 78 : 664-73, 1996
3. Homma H, Doi T, Mezawa S, Takada K, Kukitsu T, Oku T, Akiyama T, Kusakabe T, Miyanishi K, Niitsu Y : A novel arterial infusion chemotherapy for the treatment of patients with advanced pancreatic carcinoma after vascular supply distribution via superselective embolization. *Cancer* 89 : 303-13, 2000
4. Furuse J, Maru Y, Yoshino M, Mera K, Sumi H, Tajiri H, Satake M, Onaya H, Ishikura S, Ogino T, Kawashima M, Ikeda H : Hepatic arterial infusion of 5-fluorouracil for liver metastases from pancreatic carcinoma : results from a pilot study. *Hepatogastroenterology* 48 : 208-11, 2001
5. Suzuki Y, Ku Y, Tominaga M, Kamigaki T, Fujino Y, Tamioka Y, Iwasaki T, Fukumoto T, Takeyama Y, Kuroda Y : Two-staged treatment with local resection and percutaneous isolated hepatic chemoperfusion for advanced pancreatic cancer with multiple liver metastases:report of a case. *Hepatogastroenterology* 48 : 574-77, 2001
6. Lee YN, Tatter D : Carcinoma of the pancreas and periampullary structures. *Arch Pathol Lab Med* 108 : 584-87, 1984