

CASE REPORT

A case of early-stage lung cancer detected by autofluorescence bronchoscopy

Masaki Hanibuchi, Seiji Yano, Nobutaka Edakuni, Mami Inayama, Saburo Sone

Department of Internal Medicine and Molecular Therapeutics, Course of Bioregulation and Medical Oncology, The University of Tokushima School of Medicine, Tokushima, Japan.

Abstract : A 71-year-old man was referred to our hospital for further examination of abnormal sputum cytology. No abnormal nodular shadows were detected in chest X-ray and chest CT. The location of the tumor was clearly identified as a defect of autofluorescence by autofluorescence bronchoscopy at the bifurcation between the left B¹⁺² and B³ bronchi, whereas it was quite difficult by conventional bronchoscopy. Transbronchial biopsy revealed squamous cell carcinoma. Further examinations yielded the diagnosis of early-stage lung cancer. Photodynamic therapy was performed and complete response was confirmed. This case indicates the efficacy of autofluorescence bronchoscopy for detecting early-stage lung cancer. *J. Med. Invest.* 51 : 234-237, August, 2004

Keywords : early-stage lung cancer, autofluorescence bronchoscopy, photodynamic therapy

INTRODUCTION

Lung cancer is the most common cause of cancer deaths in the countries of North America and other developed countries (1). Despite advances in the detection and treatment of many cancers leading to improvements in the 5-year survival rates, the survival rate for lung cancer continues to be <15% (2). The main reason for the continued low survival rate for lung cancer patients is that tumors are found at late invasive stages, when the options for treatment are mostly palliative. Thus, for the significant reduction of mortality in lung cancer, the detection and treatment at earlier stages should be essential. Recent advances in endoscopic technology such as autofluorescence bronchoscopy (AFB) have markedly improved the early detection of premalignant and malignant bronchial lesions in high-risk individuals (3, 4). In the present report, we describe a case of early-stage lung cancer detected by AFB and successfully treated with

photodynamic therapy (PDT).

CASE REPORT

A 71-year-old man was referred to our hospital for further examination of abnormal sputum cytology (class) in May 2003. He was diagnosed as having chronic pulmonary emphysema in 1982 and secondary pulmonary hypertension in 2001. Home oxygen therapy had been conducted since 1997. He was a heavy smoker with a Brinkman Index of 1840 (40 cigarettes/day for 46 years). Physical examination revealed no remarkable findings. Peripheral blood count and biochemical examinations were within the normal range. Among serum tumor markers, carcinoembryonic antigen (CEA) was slightly elevated to 3.6 ng/ml (normal, <2.5 ng/ml) but squamous cell carcinoma related antigen (SCC), cytokeratin 19 fragment (Cyfra) and progastrin releasing peptide (proGRP) were within normal range. Post-inflammatory change in the right apex pulmonis, hyperinflation and irregular radiolucencies of the bilateral lung field and dilatation of the pulmonary artery were detected, but no abnormal nodular shadows were seen in chest X-ray. A chest CT showed multiple bulla formation and low attenuation area ori-

Received for publication January 23, 2004 ; accepted March 24, 2004.

Address correspondence and reprint requests to Masaki Hanibuchi, Department of Internal Medicine and Molecular Therapeutics, Course of Bioregulation and Medical Oncology, The University of Tokushima School of Medicine, Kuramoto-cho, Tokushima 770-8503, Japan and Fax : +81-886-33-2134.

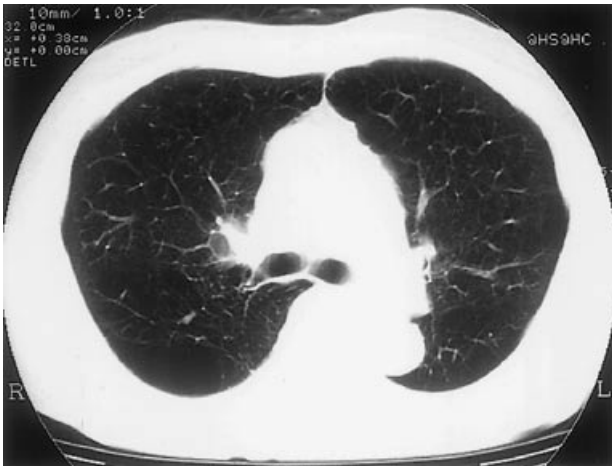

Figure 1. A chest CT film on admission. Multiple bulla formation and low attenuation area oriented in centrilobular and panlobular patterns in the bilateral lungs were seen. However, no abnormal nodular opacities and no hilar or mediastinal lymphadenopathy were detected.

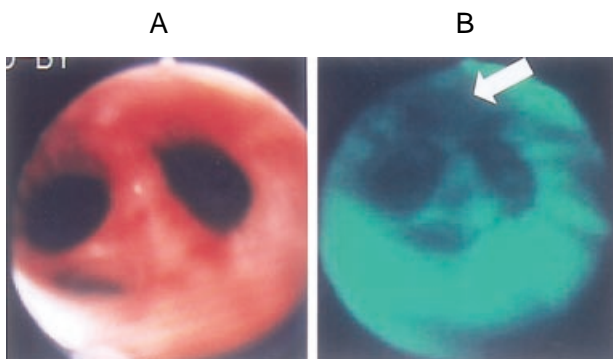


Figure 2. (A) Conventional bronchoscopic findings. Whereas some spotty, reddened lesions were found at the upper division bronchus of the left lung, the precise location of the tumor was quite difficult to determine. (B) Autofluorescence bronchoscopic findings. The location of the tumor was clearly identified as the defect of autofluorescence (arrow) by AFB (SAFE-1000®) at the bifurcation between the left B¹⁺² and B³ bronchi.

ented in centrilobular and panlobular patterns in the bilateral lungs (Fig. 1). However, no abnormal nodular opacities and no hilar or mediastinal lymphadenopathy were observed in chest CT. Pulmonary function tests showed markedly reduced forced expiratory volume in one second (FEV_{1.0} 670ml). Arterial blood gas values, with the patient breathing 2 liters of oxygen per minute via nasal prongs, were pH 7.415, PaO₂ 76.2 mmHg, PaCO₂ 37.8mmHg and oxygen saturation 95.5%. Laryngoscopic examinations revealed no abnormalities. While some spotty reddened lesions were found at the upper division bronchus of the left lung, the precise location of the tumor was quite difficult to determine by the inspection with conventional bronchoscopy alone (Fig. 2A). On the other hand, the location of the tumor was clearly identified as a defect of autofluo-

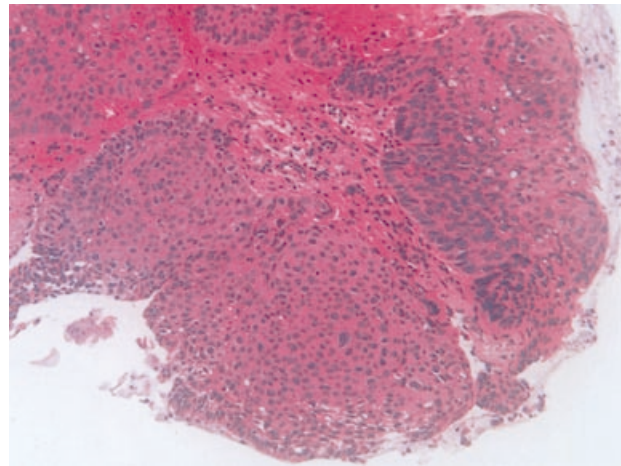


Figure 3. Histological findings of a transbronchial biopsy specimen obtained at the bifurcation between the left B¹⁺² and B³ bronchi (H.E stain, × 200). A solid growth pattern composed of polymorphic tumorous cells with large and hyperchromatic nuclei and partial keratinization was found. Histology was squamous cell carcinoma. The tumor invaded beyond the basement membrane.

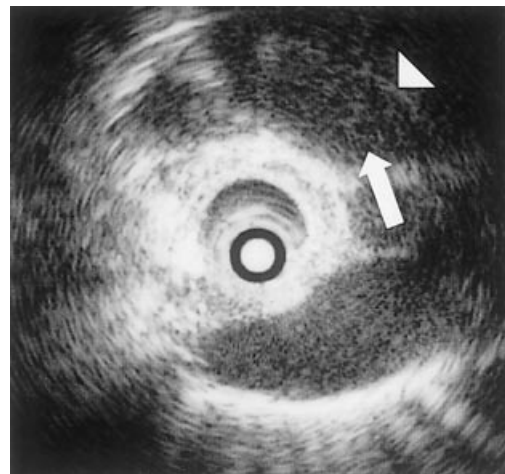


Figure 4. Endobronchial ultrasonography findings. The tumor (arrow) invasion was shown to be confined within the submuscle layer and not beyond the cartilage layer (arrow head).

rescence by the inspection with AFB (the SAFE-1000® system) at the bifurcation between the left B¹⁺² and B³ bronchi (Fig. 2 B). No other abnormal lesions were observed by careful inspection with conventional bronchoscopy and AFB. Transbronchial biopsy obtained at the bifurcation between the left B¹⁺² and B³ bronchi revealed a solid growth pattern of squamous cell carcinoma composed of polymorphic tumorous cells with large and hyperchromatic nuclei and partial keratinization (Fig. 3). No distant metastases were detected and endobronchial ultrasonography revealed no tumor invasion beyond the cartilage layer of the bronchial wall (Fig. 4). Taking all these findings into consideration, the patient was diagnosed as having early-stage lung cancer. Since he was not eligible for surgical resection due to poor pulmonary function and pulmonary

hypertension, PDT laser irradiation (total 400 kJ) was performed at 48 hours after Photofrin[®] (2mg/kg) injection intravenously. Complete response was confirmed and no severe complications appeared after therapy. Currently, he is periodically under follow up with AFB and no evidence of recurrence has been observed for nine months.

DISCUSSION

Lung cancer has become the most common cause of all deaths from cancer and the mortality rate of lung cancer is still increasing. Diagnosis and resection of lung cancer at an early stage are considered to be effective based on dramatically improved survival rates for resected patients with no surgery (5). However, only minority of patients are diagnosed at these curable stages, because of the limitations in radiographic technology, the lack of specific symptoms at an early stage of the disease, and currently available validated screening test (6).

Advances in endoscopic technology such as AFB have recently improved the detection of premalignant and malignant bronchial lesions in high-risk individuals (7-9). According to previous report, the sensitivity of biopsy proved squamous dysplasia and carcinoma *in situ* detected by white-light bronchoscopy alone was 61.2%, whereas the sensitivity was significantly increased to 89.8% with the addition of AFB (9). Among AFBs, we have been used the SAFE-1000[®] system since 2000. The advantages of this system are followings : 1) it uses simple device such as a standard xenon lamp with a filter, rather than a laser, 2) it is handier to carry than the LIFE[®] lung system (10). In the present case, the precise location of malignant lesion was clearly detected as a defect of autofluorescence by the inspection with the SAFE-1000[®] system, whereas it was quite difficult by the inspection with conventional bronchoscopy alone. In terms of the diagnosis of early-stage lung cancer, the visibility of the peripheral edge of the tumor with bronchoscopy is essential. Because the range of tumor invasion was accurately identified by AFB in the present case, the appropriate diagnosis of early-stage lung cancer was able to be yielded. These observations strongly imply that the usefulness of AFB for the detection of early-stage lung cancers.

Carcinogen exposure causes sequential morphological and genetic changes in the bronchial mucosa. Especially, tobacco, one of the most famous carcinogens, is well known to lead to multifocal carcinogenesis and cause synchronous and/or metachronous multiple

lung cancers (11). In the present case, although no other abnormalities except for the bifurcation between the left B¹⁺² and B³ bronchi were observed by careful inspection with conventional bronchoscopy and AFB, his heavy smoking habit indicates high risk for occurrence of metachronous multiple lung cancers. Because the repeated inspection with AFB in the high-risk individuals is reported to be useful for the detection of premalignant and malignant lesions (11), careful follow-up with AFB should be required in the present case.

The increased thickening of the bronchial epithelium and increases in blood content or vessel growth are thought to be involved in areas of abnormal autofluorescence irrespective of malignancy or not. As chronic inflammatory bronchial lesions due to bronchial asthma and chronic bronchitis are also known to reveal increased thickening of the epithelium and blood content, the defects of autofluorescence were frequently observed by the inspection with AFB in these lesions. Therefore, AFB is possible to detect false-positive lesions in the patients with bronchial asthma and chronic bronchitis. The relatively low specificity of AFB to distinguish malignancy or not has been reported as one of the main disadvantages of AFB (3). For example, the specificity of conventional bronchoscopy alone was 78%, whereas it was 42% with the addition of AFB (3). Recently, high magnification bronchovideoscope has been developed to overcome this disadvantage of AFB (12). At sites of abnormal autofluorescence established by AFB, high magnification bronchovideoscopy detects squamous dysplasia more accurately than AFB alone (12). Thus, the combined use of AFB with high magnification bronchovideoscopy may be able to decrease false-positive rate detected by AFB alone.

Almost all cases of early-stage lung cancer occur in current heavy smokers or ex-smokers, many of whom are not eligible for surgical resection due to synchronous multiple early-stage lung cancers and/or smoking-related complications, such as poor pulmonary function and cardio-vascular diseases. Thus, these cases seem to be good candidates for bronchial interventions. PDT, brachytherapy, electrocautery, cryotherapy, and Nd-YAG laser therapy are therapeutic options available for management of endobronchial malignancies. These bronchial interventions have been reported to be effective for both progressive and early-stage lung cancers, especially for the latter (13, 14). We treated this case with PDT for the following reasons : 1) squamous cell carcinoma was histologically proven, 2) no evidence of lymph node or distant

metastasis was observed, 3) the peripheral edge of the tumor was bronchoscopically visible, 4) the tumor did not exceed the cartilage layer of the bronchial wall, 5) there was no indication for surgical resection due to poor pulmonary function and pulmonary hypertension. As described previously (14), PDT was effective, and a complete response was confirmed in this case. However, since it is known that early-stage lung cancers even when successfully treated with PDT sometimes relapse, careful follow-up will be required in the present case.

In conclusion, we reported a case of early-stage lung cancer detected by AFB and successfully treated with PDT. AFB is a very promising tool for the early detection of premalignant and malignant bronchial lesions in high-risk individuals. The early detection of lung cancer by AFB combined with early treatment including bronchial interventional procedures might lead to a significant reduction of mortality in lung cancer.

ACKNOWLEDGEMENTS

The authors are grateful to Drs. Yoshihito Kakimoto, Takanori Miyoshi, Shoji Sakiyama, Kazuya Kondo and Yasumasa Monden, Department of Oncological and Regenerative Surgery, Course of Bioregulation and Medical Oncology, The University of Tokushima School of Medicine, for contributing to clinical diagnosis and treatment. We also thank Dr. Takayuki Kubo, Department of Molecular and Environmental Pathology, Course of Bioregulation and Medical Oncology, The University of Tokushima School of Medicine, for contributing to pathological diagnosis.

REFERENCES

- Greenlee RT, Murray T, Bolden S, Wingo PA: Cancer statistics, 2000. *CA Cancer J Clin* 50: 7-30, 2000
- Fry WA, Menck HR, Winchester DP: The national cancer data base report on lung cancer. *Cancer* 77: 1947-1955, 1996
- Lam S, Kennedy T, Unger M, Miller YE, Gelmont D, Rusch V, Gipe B, Howard D, LeRiche JC, Coldman A, Gazdar AF: Localization of bronchial intraepithelial neoplastic lesions by fluorescence bronchoscopy. *Chest* 113: 696-702, 1998
- Kusunoki Y, Imamura F, Uda H, Mano M, Horai T: Early detection of lung cancer with laser-induced fluorescence endoscopy and spectrofluorometry. *Chest* 118: 1776-1782, 2000
- Field JK, Brambilla C, Hirsch FR, Hittleman W, Hogan M, Marshall D, Mulshine JL, Rabbitts P, Sutedja T, Watson A, Weiss S: Molecular Biomarkers Workshop. A European strategy for developing lung cancer molecular diagnostics in high risk populations. *Lung Cancer* 31: 339-345, 2001
- Tockman MS, Mulshine JL: Sputum screening by quantitative microscopy: a new dawn for detection of lung cancer. *Mayo Clin Proc* 72: 788-790, 1997
- Hung J, Lam S, LeRiche JC, Palcic B: Autofluorescence of normal and malignant bronchial tissue. *Lasers Surg Med* 11: 99-105, 1991
- Lam S, MacAulay C, Hung J, LeRiche J, Profio AE, Palcic B: Detection of dysplasia and carcinoma *in situ* with a lung imaging fluorescence endoscope (LIFE) device. *J Thorac Cardiovasc Surg* 105: 1035-1040, 1993
- Kusunoki Y, Imamura F, Uda H, Mano M, Horai T: Early detection of lung cancer with laser-induced fluorescence endoscopy and spectrofluorometry. *Chest* 118: 1776-1782, 2000
- Kato H, Okunaka T, Ikeda N: Application of simple imaging technique for fluorescence bronchoscope: preliminary report. *Diag & Ther Endoscopy* 1: 79-81, 1994
- Bota S, Auliac JB, Paris C, Metayer J, Sesboue R, Nouvet G, Thiberville L: Follow-up of bronchial precancerous lesions and carcinoma *in situ* using fluorescence endoscopy. *Am J Respir Crit Care Med* 164: 1688-1693, 2001
- Shibuya K, Hoshino H, Chiyo M, Yasufuku K, Iizasa T, Saitoh Y, Baba M, Hiroshima K, Ohwada H, Fujisawa T: Subepithelial vascular patterns in bronchial dysplasias using a high magnification bronchovideoscope. *Thorax* 57: 902-907, 2002
- Vonk-Noordegraaf A, Postmus PE, Sutedja TG: Bronchoscopic treatment of patients with intraluminal microinvasive radiographically occult lung cancer not eligible for surgical resection: a follow-up study. *Lung Cancer* 39: 49-53, 2003
- Mathur PN, Edell E, Sutedja T, Vergnon JM: American College of Chest Physicians. Treatment of early stage non-small cell lung cancer. *Chest* 123(Suppl 1): 176 S-180 S, 2003