

CASE REPORT

A case of sarcoidosis accompanying squamous cell carcinoma in the mandibular gingiva

Masaki Hanibuchi, Yuka Matsumori, Yasuhiko Nishioka, and Saburo Sone

Department of Internal Medicine and Molecular Therapeutics, Institute of Health Biosciences, The University of Tokushima Graduate School, Tokushima, Japan

Abstract : A 51-year-old man with a history of gingival cancer two years previously was referred to our hospital for further examination of chest abnormal shadow. Bilateral hilar and mediastinal lymphadenopathy, diffuse small nodular opacities and pleural nodules were observed in chest high resolution CT. Serum angiotensin converting enzyme and lysozyme were elevated. Transbronchial lung biopsy specimens demonstrated non-caseous granuloma. CD4-positive lymphocytes were increased in broncho-alveolar lavage (CD4/CD8 ratio 5.47). The patient was diagnosed as having sarcoidosis. Radiological findings were improved and serum angiotensin converting enzyme level was decreased to within the normal range by corticosteroid therapy (prednisolone 30 mg/day). This is the first report of sarcoidosis accompanying the gingival cancer. *J. Med. Invest.* 52 : 118-121, February, 2005

Keywords : sarcoidosis, gingival cancer, chest high resolution CT

INTRODUCTION

Sarcoidosis is characterized by systemic granulomatous lesions, and cellular immunity is reported to be depressed. Several authors have reported the high incidence of malignant disease in sarcoidosis patients (1-4), but no definitive information about the association of these diseases is available yet. In the present report, we describe a case of sarcoidosis accompanied by squamous cell carcinoma in the bilateral mandibular gingiva. To our knowledge, this is the first report of sarcoidosis accompanying the gingival cancer.

CASE REPORT

A 51-year-old man with no remarkable past history

Abbreviations : ACE : angiotensin converting enzyme, PPD : purified protein derivative.

Received for publication September 29, 2004 ; accepted December 21, 2004.

Address correspondence and reprint requests to Masaki Hanibuchi, Department of Internal Medicine and Molecular Therapeutics, Institute of Health Biosciences, The University of Tokushima Graduate School, Kuramoto-cho, Tokushima 770-8503, Japan and Fax : +81-886-33-2134.

became aware of swelling and redness in the bilateral mandibular gingiva in May, 1998 and was diagnosed as having squamous cell carcinoma in the bilateral mandibular gingiva in June 1999. He was successfully treated by chemotherapy and operation, and followed in an out-patient clinic with no evidence of recurrence of disease for about two years.

In February, 2001, he was referred to our hospital for further examination of a newly appeared chest abnormal shadow. He had no respiratory symptoms and physical examination revealed no remarkable findings except for operative scars. No skin lesion was observed. Bilateral hilar lymphadenopathy and diffuse small nodular shadows in the bilateral lung field were observed in a chest X-ray (Fig. 1A). Diffuse small nodular opacities oriented mainly in centrilobular and peribronchovascular pattern and pleural nodules were seen in chest high resolution CT scan (Fig. 1B). Bilateral hilar and mediastinal lymphadenopathy was also observed in chest CT. Laboratory examinations were almost within the normal range, except for mild positive inflammatory reactions (CRP 0.63mg/dl) and hyperlipidemia (T-cho 249 mg/dl, TG 404 mg/dl). Se-

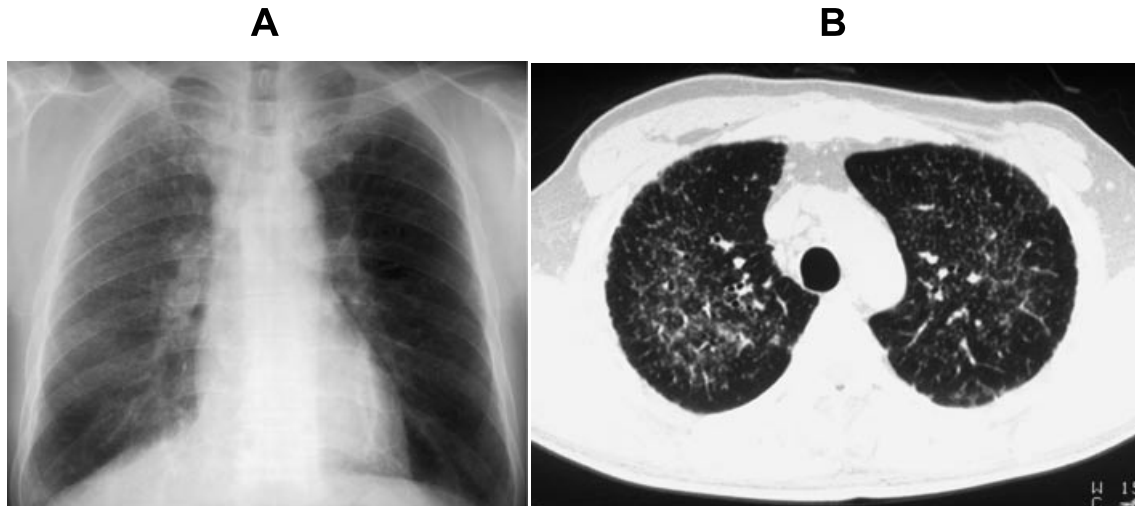

Figure 1. (A) A chest X-ray film on admission (March 16, 2001). Bilateral hilar lymphadenopathy and diffuse small nodular shadows in the bilateral lung fields were observed. (B) A Chest high resolution CT film on admission (March 19, 2001). Diffuse small nodular opacities oriented mainly in a centrilobular and peribronchovascular pattern and pleural nodules were seen.

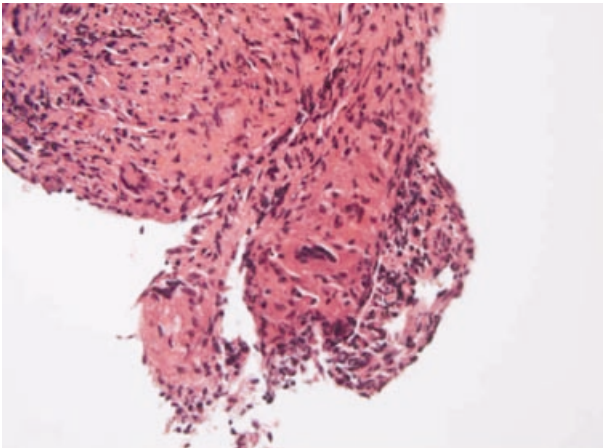


Figure 2. Microscopic findings of biopsied specimen obtained by transbronchial lung biopsy (March 22, 2001). Non-caseous granulomatous lesions were observed. No malignant cells were seen in the same sample (H.E stain, $\times 200$).

rum angiotensin converting enzyme (ACE) (50.5 IU/L; normal range: 7.7-29.4) and lysozyme (18.4 $\mu\text{g/ml}$; normal range: 5.0-10.2) were elevated. Tumor markers were all negative (Table 1). Purified protein derivative (PPD) skin test was positive (11 \times 10mm). Electrocardiogram findings were within normal limits. Ophthalmological examinations revealed bilateral uveitis.

Transbronchial lung biopsy specimens obtained with a fiberoptic bronchoscope (Olympus Co., Tokyo, Japan) demonstrated non-caseous granuloma (Fig. 2). No malignant cells were observed in the biopsied specimens. CD4-positive lymphocytes were increased in bronchoalveolar lavage (CD4/CD8 ratio 5.47). The patient was diagnosed as having stage II disease of sarcoidosis. He was initially followed up in an out-patient clinic without medication. In November 2001, oral corticosteroid therapy (prednisolone 30 mg/day) was started due

to disease progression as diagnosed by the increase of small nodular shadows in the chest X-ray and CT scan and elevation of the serum ACE level (73.3 IU/L). Radiological findings were promptly improved and the serum ACE level was decreased to within the normal range by corticosteroid therapy. He is now under follow up with careful tapering of corticosteroid and no evidence of recurrence has been observed.

DISCUSSION

We report here a case of sarcoidosis that occurred two years after treatment for squamous cell carcinoma in the mandibular gingiva. Few cases of the association of oral malignancies with sarcoidosis have been reported in the literature (5). To our knowledge, this is the first report of sarcoidosis accompanying the gingival cancer.

Regarding the mechanisms of the complication of malignancy by sarcoidosis, the following three possibilities have been suggested (6). 1) These two diseases occur together by chance. 2) Sarcoidosis initiates the carcinogenesis and/or promotes the growth of malignancy via the suppression of cellular immunity. 3) Sarcoidosis occurs as a result of the host immunological response against malignancy. In the present case, no evidence of recurrence of the gingival cancer was observed at the time of diagnosis of sarcoidosis. Thus, we speculated these two diseases might have occurred together by chance, but it also seems possible that the immunological response against residual squamous cell carcinoma in the mandibular gingiva led to the occurrence of sarcoidosis.

When discussing malignant disease accompanied

Table 1. Laboratory findings on admission

Peripheral blood	T-cho	249mg/dl	Tumor marker	
RBC	430 × 10 ⁴ /μl	TG	404mg/dl	
Hb	13.4g/dl	TP	7.2g/dl	
Ht	41.2%	Alb	4.3g/dl	
WBC	4600/μl	UA	3.6mg/dl	
neut .	58.0%	BUN	14mg/dl	
lymph .	28.8%	Cr	0.9mg/dl	
mono .	9.2%	Na	139mEq/l	
eos .	2.9%	K	4.0mEq/l	
baso .	1.1%	Cl	101mEq/l	
Plt .	15.7 × 10 ⁴ /μl	Ca	9.7mg/dl	
Biochemistry		P	3.8mg/dl	
GOT	26U/l	Glucose	106mg/dl	
GPT	16U/l	ACE	50.5IU/L	
LDH	165U/l	lysozyme	18.4μg/ml	
T-bil	0.7mg/dl	Serology		
ALP	285U/l	CRP	0.63mg/dl	
γ-GTP	80U/l	Wa-R	()	
CK	102U/l	HBs-Ag	()	
AMY	72U/l	HCV-Ab	()	
			Pulmonary function test	
			VC	3020ml
			%VC	79.68%
			FEV _{1.0}	2620ml
			FEV _{1.0} %	87.04%
			Blood gas analysis (room air)	
			pH	7.389
			PaO ₂	86.7
			PaCO ₂	40.3
			SaO ₂	97.4
			Sputum	
			Culture	normal flora
			Acid-fast bacteria	()
			cytology	class II

by sarcoidosis, sarcoid reaction complicated with malignant disease must always be considered (3). Sarcoid reaction associated with malignancies has been reported for various kinds of malignancies (7). Histologically, it is often difficult to distinguish sarcoidosis from sarcoid reaction. Commonly, the differential diagnosis between sarcoid reaction and sarcoidosis is based on the presence of extrapulmonary manifestations and the time of occurrence (8). In the present case, extrapulmonary manifestations such as uveitis were evident and no evidence of recurrence of the gingival cancer was observed at the time of the appearance of chest abnormal shadow. Moreover, the incidence of metastasis of the gingival cancer to the lungs and mediastinal lymphnodes was reported to be extremely rare (9). Therefore, we diagnosed the present case as having sarcoidosis.

We should also discriminate sarcoidosis from metastatic lung tumor originating from the gingiva and/or other organs in this case. In the chest high resolution CT, small nodular opacities oriented mainly in a centrilobular and peribronchovascular pattern and pleural nodules were observed. These findings were much more compatible with sarcoidosis than metastatic lung tumor, supporting the accuracy of the diagnosis. The chest high resolution CT may be very useful for distinguishing sarcoidosis from metastatic lung tumor and other diffuse lung diseases.

There are some etiological reports on the incidence of malignant diseases in sarcoidosis patients and the relationship of the two diseases. In 1972, Brinker re-

ported a high rate of sarcoidosis incidence in an analysis of about 1500 Danish patients with Hodgkin's disease and other malignant lymphomas (1). Moreover, Yamaguchi *et al.* reported excess deaths from lung cancer among Japanese sarcoidosis patients (2). In contrast, Seersholm *et al.* argued against the theory of an association between sarcoidosis and malignancy and concluded that the main reasons other studies have shown such an association were most likely to have been selection bias and misclassification (3). More recently, Romer *et al.* reported no increased occurrence of lung cancer or malignant lymphoma in an analysis of 555 patients with sarcoidosis (4). Taking these data together, the association between sarcoidosis and various malignancies is still controversial and it is impossible to draw definite conclusions.

Furthermore, the contribution of the existence of sarcoidosis to tumor progression and prognosis is also controversial. Yamasawa *et al.* reported 4 cases of the coexistence of sarcoidosis and lung cancer and 2 of these cases showed a surprisingly slow growth of cancers (10). On the other hand, two reports mentioned that cancer associated sarcoid-like reaction did not influence the prognosis of malignancy (11, 12). Further study should be required to investigate these associations.

In conclusion, we report here a rare case of sarcoidosis accompanying squamous cell carcinoma in the bilateral mandibular gingiva. This seems to be the first report of sarcoidosis accompanying gingival cancer. Nevertheless, since the association between sarcoidosis

and various kinds of malignancies is still controversial, it will be useful to accumulate data about patients with malignant disease in sarcoidosis patients for such evaluation.

ACKNOWLEDGEMENT

The authors are grateful to Dr. Mitsuyoshi Hirokawa, Department of Human Pathology, Course of Diseased Organ and Repair Medicine, Institute of Health Biosciences, The University of Tokushima Graduate School, for contributing to pathological diagnosis.

REFERENCES

1. Brinker H, Wilbek E : The incidence of malignant tumors in patients with pulmonary sarcoidosis. *Br J Cancer* 29 : 247-51, 1974
2. Yamaguchi M, Odaka M, Hosoda Y, Iwai K, Tachibana T : Excess death of lung cancer among sarcoidosis patients. *Sarcoidosis* 8 : 51-5, 1991
3. Seersholm N, Vestbo J, Viskum K : Risk of malignant neoplasms in patients with pulmonary sarcoidosis. *Thorax* 52 : 892-4, 1997
4. Romer FK, Hommelgaard P, Schou G : Sarcoidosis and cancer revisited: a long-term follow-up study of 555 Danish sarcoidosis patients. *Eur Respir J* 12 : 906-12, 1998
5. Pollock JL, Catalano E : Metastatic ductal carcinoma of the parotid gland in a patient with sarcoidosis. *Arch Dermatol* 115 : 1098-9, 1979
6. Sakula A : Bronchial carcinoma and sarcoidosis. *Br J Cancer* 17 : 206-12, 1963
7. Brinker H : Sarcoid reactions in malignant tumors. *Cancer Treat Rev* 13 : 147-56, 1986
8. Segawa Y, Takigawa N, Okahara M, Maeda Y, Takata I, Fujii M, Mogami H, Mandai K, Kataoka M : Primary lung cancer associated with diffuse granulomatous lesions in the pulmonary parenchyma. *Intern Med* 35 : 728-31, 1996
9. Osaki T, Yoneda K, Yamamoto T, Kimura T, Matuoka H, Sakai H, Ryoike K : Clinical investigation on pulmonary metastasis of head and neck carcinomas. *Oncology* 59 : 196-203, 2000
10. Yamasawa H, Ishii Y, Kitamura S : Concurrence of sarcoidosis and lung cancer. A report of four cases. *Respiration* 67 : 90-3, 2000
11. Kamiyoshihara M, Hirai T, Kawashima O, Ishikawa S, Morishita Y : Sarcoid reactions in primary pulmonary carcinoma : report of seven cases. *Oncol Rep* 5 : 177-80, 1998
12. Kovacs J, Varga A, Bessenyei M, Gomba S : Renal cell cancer associated with sarcoid-like reaction. *Pathol Oncol Res* 10 : 169-71, 2004