

CASE REPORT

A patient with esophageal hemangioma treated by endoscopic mucosal resection : a case report and review of the literature

Masahiro Sogabe,^{1,3} Toshikatsu Taniki⁵, Yasuo Fukui,⁵ Takahiro Yoshida,² Koichi Okamoto,⁴ Yoshio Okita,³ Hiroshige Hayashi⁶, Eriko Kimuara³, Yoshitaka Kimura³, Yukiko Onose³, Yuji Ozaki,³ Hiroshi Iwaki³, Kei Sato³, Shingo Hibino³, Seizo Sawada³, Naoki Muguruma¹, Seisuke Okamura¹, and Susumu Ito¹

¹Department of Digestive and Cardiovascular Medicine, and ²Department of Oncological and Regenerative Surgery, Institute of Health Biosciences, The University of Tokushima Graduate School, Tokushima, Japan;

³Department of Internal Medicine, Anan Central Hospital of The Medical Association, Tokushima, Japan;

⁴Department of Gastroenterology, and ⁵Department of Surgery, Kochi Health Sciences Center, Kochi, Japan;

and ⁶Fukuda Clinic of Internal Medicine Heart and Digestive, Kochi, Japan

Abstract : In a 58-year-old male, upper digestive endoscopy revealed a protruding lesion in the esophagus on a medical examination. The patient was referred to the Department of Surgery in our hospital to undergo surgery. On the initial consultation, upper digestive endoscopy showed a smooth, soft, black purple, type protruding lesion measuring approximately 25 mm at 35 cm apart from the incisor. For diagnostic treatment and patient's request, endoscopic mucosal resection (EMR) was performed. The resected specimen measured 25 mm × 25 mm. The histological findings suggested cavernous hemangioma. To treat esophageal hemangioma, esophagectomy, tumor enucleation, or sclerotherapy has been performed. However, recently, thorough preoperative examination, such as endoscopic ultrasonography (EUS), has facilitated endoscopic resection, such as EMR. *J. Med. Invest.* 53 : 177-182, February, 2006

Keywords : esophageal hemangioma, endoscopic mucosal resection

INTRODUCTION

Among benign tumors of the esophagus, esophageal hemangioma is relatively rare(1). However, the recent widespread use of endoscopy and medical examination has increased the incidence of this tumor. To treat

esophageal hemangioma, esophagectomy or tumor enucleation has been performed, but recently, the number of endoscopic therapy is increasing. Endoscopic mucosal resection (EMR) of esophageal hemangioma is rare. In this study, we report a patient with esophageal hemangioma that was detected at the medical examination and could be resected by endoscopic mucosal resection (EMR), and review the literature.

Received for publication August 22, 2005 ; accepted November 22, 2005.

Address correspondence and reprint requests to Masahiro Sogabe, M.D., Department of Internal Medicine, Anan Central Hospital of The Medical Association, 2 Kawahara, Takarada-cho, Anan, Tokushima 774-0045, Japan and Fax : +81-88-423-6773.

CASE REPORT

The patient was a 58-year-old male. There was no complaint. The family history was not contributory. Concerning previous history, he underwent surgery for rectal cancer at the age of 50 years. In September 2002, upper digestive endoscopy in a periodic medical examination revealed a protruding lesion in the esophagus. The patient was referred to the Department of Surgery in our hospital to undergo surgery. For preoperative endoscopy, the patient was referred to the Department of Internal Medicine. Concerning physical examination on admission, height and body weight were 162 cm and 54 kg, respectively. The physical status was moderate, and nutrition was good. Anemia was not observed in the palpebral conjunctivae, and jaundice was not observed in the bulbar conjunctivae. There were no abnormal physical findings in the thoracic or abdominal regions. Palpation did not reveal any abnormalities in the superficial lymph nodes. There was no edema of the lower thigh.

Concerning blood biochemistry (Table 1), there were no abnormalities in peripheral blood/blood biochemistry/blood coagulation test findings or tumor/viral markers.

Esophagography (Fig. 1) showed an oval shadow defect measuring approximately 22 mm × 8 mm with a smooth surface at the anterior wall of the lower thoracic esophagus.

Upper digestive endoscopy (Fig. 2) revealed a smooth, soft, black purple, type II protruding lesion measuring approximately 25 mm at the anterior wall approximately 35 cm from the incisor.

On endoscopic ultrasonography (EUS)(Fig. 3), the main location of the lesion was visualized as a

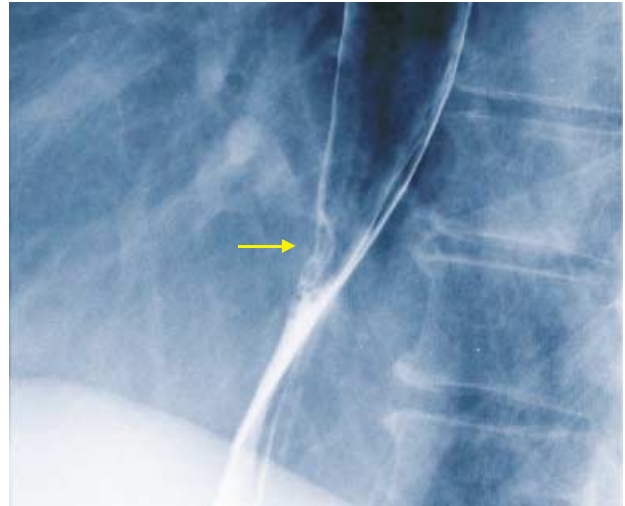


Fig.1 . Esophagography showing a filling defect, measuring 22 × 8 mm in size on the lower esophagus.

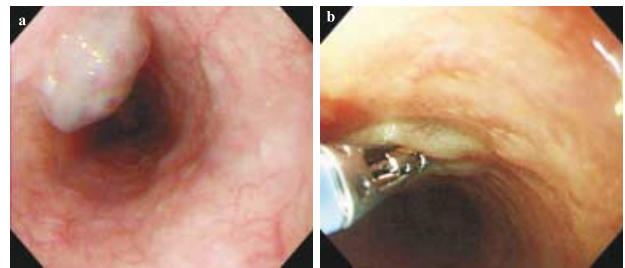


Fig. 2 . Endoscopic findings. (a) A showing black purple, type II protruding lesion with a smooth surface. (b) The lesion is soft.

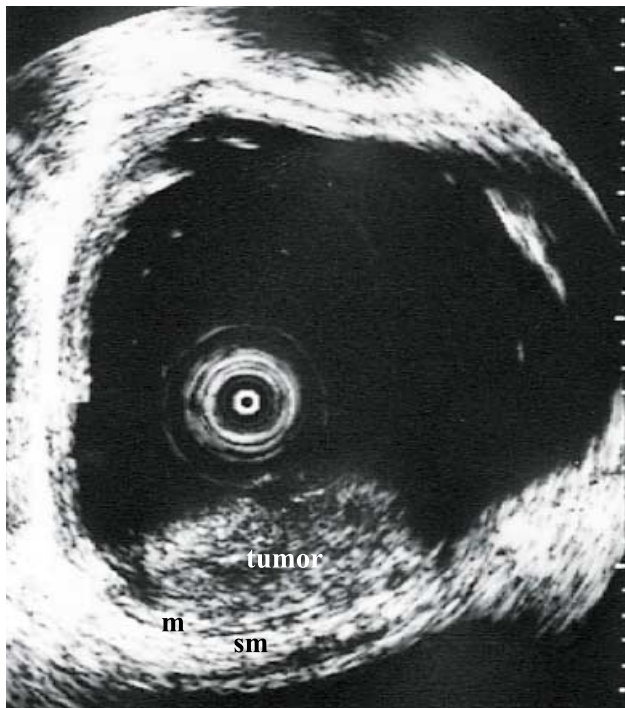


Fig. 3 . EUS showing hypoechoic ~ isoechoic mass, which is located in the mucosal and submucosal layer.

Table 1. Laboratory data on admission

Hematological test		Blood chemistry		Coagulation test	
WBC	8450/mm ³	T-Bil	0.4 mg/dl	PT	10.9 sec
RBC	440 × 10 ⁴ /mm ³	GOT	30 IU/L	PT	96.4%
Hb	14.3 g/dl	GPT	26 IU/L	APTT	31.4 sec
Ht	41.6%	LDH	330 IU/L	B.T.	2 : 00 min
Plt	31.9 × 10 ⁴ /mm ³	ALP	183 IU/L		
		γ-GTP	49 IU/L	Tumor markers	
Urinary analysis		T-Cho	129 mg/dl	SCC	0.5 ng/ml
Protein	(-)	T.P.	7.4 g/dl	CYFRA	2.9 ng/ml
augar	(-)	Alb	4.3 g/dl		
occult blood	(-)	ChE	142 IU/L	Viral markers	
		Bun	11 mg/dl	RPR	(-)
Serological test		CRNN	0.7 mg/dl	TPHA	(-)
CRP	0.1 g/mdl	Na	138 mEq/L	HBs-Ag	(-)
		K	4.2 mEq/L	HCV Ab	(-)
		Cl	98 mEq/L		
		FBS	98 mEg/dl		

hypoechoic to isoechoic tumor involving mucosa to the submucosal layer, and the muscularis propria layer was intact. There was no continuity between the tumor and low echoic bands such as the blood vessels.

Contrast-enhanced computed tomography (CT) of the thoracic region (Fig. 4) revealed a tumor measuring approximately 8 to 10 mm at an area adjacent to the anterior wall of the thoracic esophagus.

After informed consent which progress observation or treatment was chosen was obtained, EMR (Fig. 5) was performed for diagnostic treatment and patient's request on October 30. Endoscopic esophageal mucosal resection (EMR)-tube method was used as EMR method. Resection was successful without complications such as hemorrhage and perforation.

The resected specimen measuring 25 mm × 25 mm (Fig. 6). The soft surface was blue white to blue purple.

The histopathological findings (Fig. 7) showed formation of a vascular lumen with irregular dilatation just below the lamina muscularis mucosa, suggesting cavernous hemangioma.

After EMR, there were no complications. The patient was discharged 1 week after EMR. Three months after EMR, upper digestive endoscopy did not

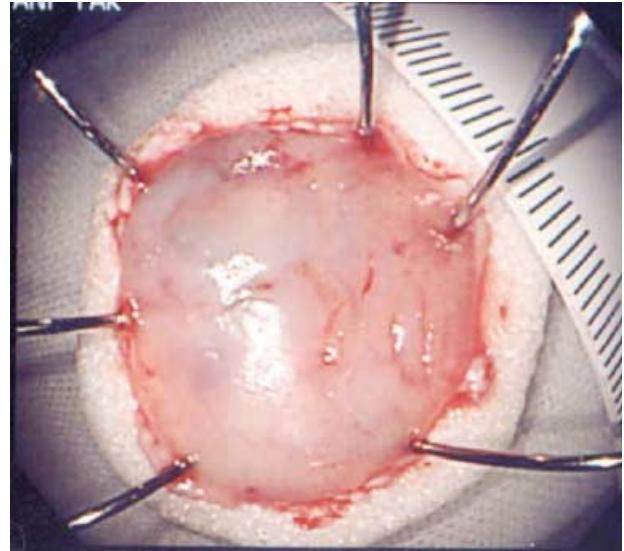


Fig. 6 . The resected specimen measuring 25 × 25 mm is blue white to blue purple.

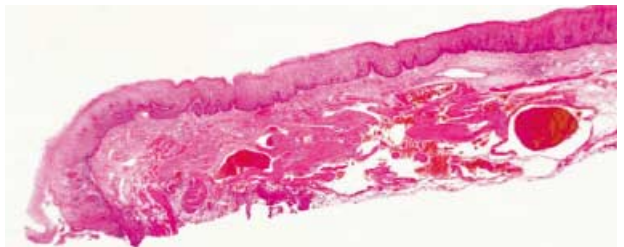


Fig. 7 A photomicrograph of the resected tumor showing formation of a vascular lumen with irregular dilatation immediately below the lamina muscularis mucosa

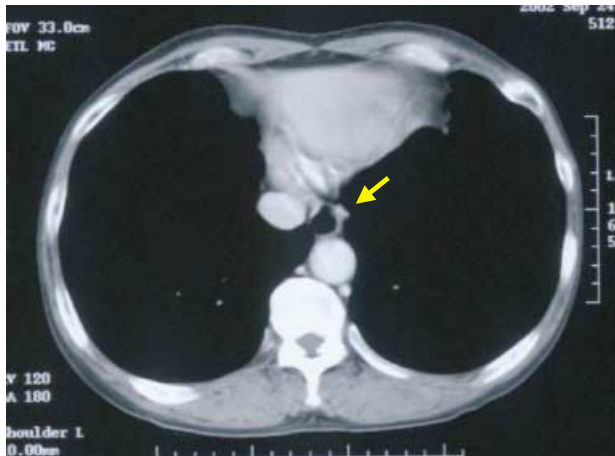


Fig. 4 . Chest CT revealing a tumor at the anterior wall of the thoracic esophagus.

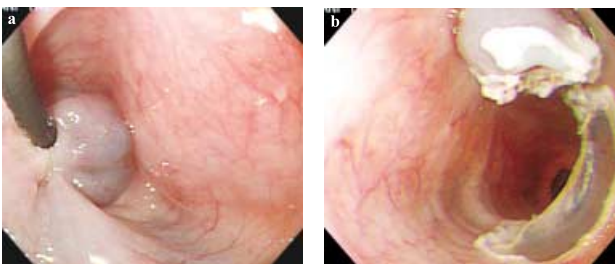


Fig. 5 . Endoscopic mucosal resection. (a) The tumor is snared at the base which is injected with hypertonic saline and epinephrine solution. (b) Resection site without bleeding and perforation.

reveal stenosis of the esophagus, residual hemangioma, or relapse.

DISCUSSION

The incidence of benign tumors of the esophagus is relatively low. Moersch & Harrington *et al.* (1) reported these tumors in 44 (0.6%) of 7,459 autopsy cases. In addition, esophageal hemangioma was observed in only 3 patients (0.04%). In Japan, 83 patients with esophageal hemangioma, including our patient, have been reported in the literature (agendas were excluded because the details were unclear). In 20 of these patients, endoscopic resection was performed (Table 2)(2-18). Procedures included polypectomy in 16 patients and EMR in 4 patients (11,15,16), as performed in our patient. There were 16 males and 4 females, with a mean age of 62.4 ± 11.4 years. Complaints consisted of hematemesis (hemorrhage of the digestive tract) in 1 patient and dysphasia in 9 patients. In 7 patients, esophageal hemangioma was asymptomatic, as demonstrated

Table 2. Characteristics of the reported cases of endoscopic resection for the treatment of esophageal hemangioma in Japan

Investigator	(Year)	Age	Sex	Chief complain	Location	Form	Size(mm)	Pathological findings	Variety of endoscopic therapy
1 Kawahara	(1983)	60	F	dysphagia	Mt	IV	9×8×7	cap HA	Polypectomy
2 Oguchi ⁽²⁾	(1984)	82	M	dysphagia	Lt	III	18×11×8	cap HA	Polypectomy
3 Kurashita	(1985)	41	M	(-)	Lt	III	6×5×5	cap HA	Polypectomy
4 Yoshioka ⁽³⁾	(1985)	57	M	hematemesis	Ce	III	24×23×18	cav HA	Polypectomy
5 Arai ⁽⁴⁾	(1986)	56	F	dysphagia	Lt	IV	22×13×7	cav HA	Polypectomy
6 Kubo ⁽⁵⁾	(1986)	76	M	dysphagia	Ut	IV	22×12×9	cap HA	Polypectomy
7 Sato ⁽⁶⁾	(1986)	50	M	(-)	Lt	IV	5×3×3	cap HA	Polypectomy
8 Onozawa ⁽⁷⁾	(1988)	82	M	dysphagia	Lt	III	18×11×8	cap HA	Polypectomy
9 Ohkubo ⁽⁸⁾	(1989)	55	M	abdominal pain	Ut	III	18×15×14	cap HA	Polypectomy
10 Inui ⁽⁹⁾	(1990)	72	M	dysphagia	Mt	IV	6×5×4	cap HA	Polypectomy
11 D.Cantero ⁽¹⁰⁾	(1994)	72	M	chest pain	Mt	IV	20×12×7	cap HA	Polypectomy
12 Yoshikane ⁽¹¹⁾	(1995)	49	M	(-)	Lt	II	10×9×6	cav HA	EMR
13 Sekimata ⁽¹²⁾	(1996)	66	M	dysphagia	Mt	IV	30×20×15	cap HA	Polypectomy
14 Uchida ⁽¹³⁾	(1997)	70	F	dysphagia	Ut	III	8×7×6	cap HA	Polypectomy
15 Seki ⁽¹⁴⁾	(1997)	51	F	dysphagia	Lt	III	30×20	cav HA	Polypectomy
16 Suematsu ⁽¹⁵⁾	(1999)	69	M	loss of BW	Ut	III	15×7	cap HA	EMR
17 Araki ⁽¹⁶⁾	(1999)	60	M	(-)	Ut	III	15×15	cav HA	EMR
18 Tominaga ⁽¹⁷⁾	(2000)	59	M	(-)	Mt	II	30	cav HA	Polypectomy
19 Our case	(2003)	58	M	(-)	Lt	II	25	cav HA	EMR
20 Yamamoto ⁽¹⁸⁾	(2004)	44	M	(-)	Mt	III	6×5	cap HA	Polypectomy

cap HA : capillary hemangioma, cav HA : cavernous hemangioma, BW : body weight, Ce : cervical esophagus

Ut : upper thoracic esophagus, Mt : middle thoracic esophagus, Lt : lower thoracic esophagus

in the present patient. Locations consisted of the thoracic upper esophagus in 5 patients, thoracic middle esophagus in 5 patients, thoracic lower esophagus in 9 patients, and cervical esophagus in 1 patient. The macroscopic type was type II in 3 patients, type III in 10, and type IV in 7. The tumor size ranged from 5 to 30 mm. Histologically, cavernous hemangioma was suggested in 7 patients, and capillary hemangioma in 13 patients.

In diagnosing the presence of esophageal hemangioma, esophagography facilitates visualization in most patients. However, recent improvement in endoscopy has facilitated presence diagnosis. On esophagography, most lesions are visualized as submucosal tumors ; however, the characteristics of esophageal hemangioma remain to be clarified. For definitive diagnosis, endoscopy is needed, and blue white to red purple soft lesions with a submucosal tumor-like morphology may be readily diagnosed. Histological diagnosis by biopsy is useful; however, hemorrhage may occur after biopsy. Palchick *et al.* (19) and Hanel *et al.* (20) have reported that there was no hemorrhage. Recently, several studies classified hemangioma by its morphology and color, and indicated endoscopic polypectomy (2, 13). Sekimata *et al.* (13) classified patients with hemangioma into 5 groups, and reported that endoscopic polypectomy was not indicated for type I / II lesions (Groups 1 and 2),

considering the risks of morphology-associated incomplete resection and postoperative hemorrhage from the residual stump of hemangioma. Recent studies have reported qualitative diagnosis by magnetic resonance imaging (MRI) and EUS (10, 15, 16). The present patient was assigned to Group 1 according to the classification described by Sekimata *et al.* (13) However, pretreatment EUS facilitated confirming the main location of the lesion and the absence of continuity with blood vessels ; therefore, EMR could be performed, considering that hemorrhage may not occur.

To treat esophageal hemangioma, esophagectomy or tumor enucleation has been performed. Recently, endoscopic sclerotherapy (21, 22) and laser therapy (23) have been reported. The number of patients undergoing EMR or endoscopic polypectomy is increasing. Esophageal hemangioma frequently develops in the middle/lower esophagus. For surgery, thoracotomy may be performed, which is stressful. Furthermore, endoscopic sclerotherapy may cause hemorrhage on puncture, the side effects of infused agents, and complications. Endoscopic resection is less invasive than this sclerotherapy, and advances of endoscopic treatments and instruments may reduce the risk of serious complications. In the future, this procedure may be indicated for a larger number of patients. However, evaluation by various preoperative

examinations, and close management are needed, as complications, such as hemorrhage and perforation, may occur.

ACKNOWLEDGMENTS

We thank Satoshi Numoto (Departments of Pathology, Kochi Health Sciences Center) for pathological diagnosis.

REFERENCES

1. Moersch HJ, Harrington SW : Benign tumor of the. *Ann Otol Rhinol Laryngol* 53 : 800-817, 1994
2. Oguchi S, Nabeya K, Onozawa K, Kobayashi Y, Suzuki N : A case of esophageal hemangioma polypectomised endoscopically. *Gastroenterol Endosc* 29 : 96-100, 1987
3. Yoshioka Y, Sakai K, Hamanaka Y, Hirata S, Higashino S, Hai M, Ohsugi H, Itoh S, Koizumi H, Maekawa N, So H, Ueno T, Kobayashi Y: Three cases of the esophageal hemangioma. *Gastroenterological Surgery* 8 : 370-377, 1985
4. Arai K, Suzuki S, Tanio N, Fukushima M, Araidai O, Hataya K, Kawamura K, Koizumi K, Koike T, Ishii J, Sugiyama Y, Suzuki : A case of esophageal hemangioma. *Progress of Digestive Endoscopy* 29 : 190-194, 1986
5. Kudo M, Hirasa M, Takakuwa H, Ibuki Y, Hujimi K, Miyamura M, Tomita S, Komori E, Todou A, Shirane H : A case of esophageal hemangioma excised by endoscopic polypectomy. *Gastroenterol Endosc* 28 : 318-323, 1986
6. Sato K, Asagi S, Koseki Y : A case of endoscopically polypectomized capillary hemangioma of the esophagus. *Progress of Digestive Endoscopy* 28 : 215-218, 1986
7. Onozawa K, Nabeya K, Motojima T, Kaku C, Kawaguchi T, Oguchi S, Arai Y : Endoscopical Polypectomy for Esophageal Submucosal Tumors. *J Jpn Bronchoesophagol Soc* 39(in Japanese) : 374-378, 1988
8. Ohkubo K, Nakano K, Seto K, Yamamoto S, Uno J, Fujisawa Y : A case of esophageal hemangioma polypectomised endoscopically. *Ehime Igaku* 8(in Japanese) : 511-515, 1989
9. Inui M, Horie E : A case of esophageal hemangioma. *-Endoscopic Polypectomy-Gastroenterol Endosc* 32 : 554-562, 1990
10. D Cantero, Yoshida T, Suzumi M, Tada M, Okita K: Esophageal hemangioma: Endoscopic diagnosis and treatment. *Endoscopy* 26 : 250-253, 1994
11. Yoshikane H, Suzuki T, Yoshioka N, Ogawa Y, Ochi T, Hasegawa N: Hemangioma of the esophagus : endosonographic imaging and endoscopic resection. *Endoscopy* 27 : 267-269, 1995
12. Sekimata T, Usuki H, Okada S, Ishimura K, Yatida S, Wakabayashi H, Wakabayashi H, Maeba T, Utida Y : A case of esophageal hemangioma polypectomised endoscopically. *Gastroenterol Endosc* 41 : 1083-1089, 1999
13. Uchida N, Nagamachi Y, Takenoshita S, Hosouchi Y, Nakamura J, Fujita K : A case of esophageal hemangioma. *J Jpn Surg Assoc* 58: 1018-1022, 1997
14. Seki E, Gonda H, Fujii Y, Katsuura Y, Daibo M, Sakai Y, Okada T, Ouchi K, Iida A, Sakurai H, Tomiki Y, Urabe M, Sakakibara N : A case of hemangioma of esophagus safely resected with detachable snare. *Progress of Digestive Endoscopy* 50 : 240-241, 1997
15. Suematsu M, Takeshita S, Oda Y, Kiyozumi T, Akashi R, Sagara K : A case of esophageal angioma resected endoscopically. *Endoscopia Digestiva* 11 : 948-952, 1999
16. Araki K, Ohno S, Egashira A, Saeki H, Kawaguchi H, Ikeda Y, Kitamura K, Sugimachi K : Esophageal hemangioma : a case report and review of the literature. *Hepatogastroenterology* 46 : 3148-3154, 1999
17. Tominaga K, Arakawa T, Ando K, Umeda S, Shiba M, Suzuki N, Watanabe T, Takaishi O, Fujiwara Y, Uchida T, Fukuda T, Higuchi K, Kuroki T : Oesophageal cavernous haemangioma diagnosed histologically, not by endoscopic procedures. *J Gastroenterology and Hepatol* 15 : 215-219, 2000
18. Yamamoto S, Okazaki K: A case of esophageal hemangioma. *Clinical Gastroenterology* 19 : 1443-1435, 2004
19. Palchick BA, Alpert MA, Holmes RA, Tully RJ, Wilson RC : Esophageal Hemangioma ; Diagnosis with Computed Tomography and Radionuclide Angiography. *Southern Med J* 76 : 1582-1584, 1983
20. Hanel K, Talley NA, Hunt DR : Hemangioma of the esophagus ; An unusual case of upper gastrointestinal bleeding. *Dig Dis Sci* 26 : 257-263, 1981

21. Nagata-Narumiya T, Nagai Y, Kashiwagi H, Hama M, Takifuji K, Tanimura H : Endoscopic sclerotherapy for esophageal hemangioma. *Gastrointest Endosc* 52 : 285-287, 2000
22. Aoki T, Okagawa K, Nishioka K, Miyata H, Ukei T, Miyauchi K, Terashima T, Kaneko T, Mizunoya S : Successful treatment of an esophageal hemangioma by endoscopic injection sclerotherapy : report of a case. *Surg Today* 27 : 450-452, 1997
23. Shigemitsu K, Naomoto Y, Yamatsuji T, Ono K, Aoki H, Haisa M, Tanaka N : Esophageal hemangioma successfully treated by fulguration using potassium titanyl phosphate/yttrium aluminum garnet (KTP/YAG) laser : a case report. *Dis Esophagus* 13 : 161-164, 2000