

**ORIGINAL****Leukocytapheresis for the treatment of acute exacerbation of idiopathic interstitial pneumonias : a pilot study**

Akihiro Yamamoto, Kiyoshi Hashimoto, Akira Yamasaki, Miki Takata, Masato Morita, Yoshihiro Funaki, Kensaku Okada, Yasuhiko Teruya, Takehito Fukushima, and Eiji Shimizu

*Division of Medical Oncology and Molecular Respiriology, Department of Multidisciplinary Internal Medicine, Faculty of Medicine, Tottori University, Yonago, Japan*

**Abstract : Objective :** Idiopathic interstitial pneumonias (IIPs) are a group of heterogeneous diffuse parenchymal lung disorders of unknown etiology. An acute exacerbation (AE) is an acute respiratory deterioration that occurs in IIPs. The prognosis of AE of IIPs (AE-IIPs) is extremely severe ; however, no established therapies exist. We aimed to evaluate the efficacy of leukocytapheresis (LCAP) to treat patients with AE-IIPs. **Patients and Methods :** Six chronic IIPs patients who developed AE were enrolled in this study. We performed LCAP on days 2, 3, 9 and 10 in all six patients. All patients were also treated with high-dose corticosteroids and a continuous administration of low-molecular-weight heparin. We observed 30-day survival after the diagnosis of AE to evaluate the efficacy of LCAP. We also assessed oxygenation, high-resolution computed tomography (HRCT) findings, and certain chemical mediators in the peripheral blood. **Results :** Five of six patients survived more than 30 days. One patient died of progressive respiratory failure. Oxygenation and HRCT findings tended to improve in all survivors. The serum levels of lactate dehydrogenase, high mobility group box-1, and interleukin-18 were significantly decreased statistically post-LCAP. No severe adverse events occurred. **Conclusion :** We suggest that LCAP is a safe and effective therapy for treating patients with AE-IIPs. *J. Med. Invest.* 64 : 110-116, February, 2017

**Keywords :** acute exacerbation, idiopathic interstitial pneumonia, idiopathic pulmonary fibrosis, leukocytapheresis, nonspecific interstitial pneumonia

**INTRODUCTION**

Idiopathic interstitial pneumonias (IIPs) are a group of heterogeneous diffuse parenchymal lung disorders of unknown etiology. Idiopathic pulmonary fibrosis (IPF) is the most common form of IIP, and has an extremely poor prognosis (1, 2). Acute exacerbation (AE) of IPF (AE-IPF) is acute respiratory deterioration without clinically apparent left heart failure, pulmonary embolism, or other identifiable causes (3). Acute exacerbation occurs mostly in IPF, although it also occurs in other fibrosing interstitial pneumonias such as idiopathic nonspecific interstitial pneumonia (iNSIP) (2). The prognosis of AE-IPF is exceedingly severe. Some studies indicate that the in-hospital survival rate of AE-IPF is 40%-50% (4, 5). Corticosteroids and/or immunosuppressive agents are administered to patients with AE-IPF. However, there is no reliable data to support their efficacy.

Some papers indicate that direct hemoperfusion with polymyxin B-immobilized fiber (PMX) may improve oxygenation and survival in patients with AE-IPF or other rapidly progressive interstitial pneumonias (6, 7). Abe *et al.* reported that the 30-day survival rate of PMX treatment for AE-IPF was 70.1% (6). On the other hand, recombinant human thrombomodulin (rhTM) may also improve the survival of AE-IPF patients : Kataoka *et al.* reported that the 3-month survival rate of rhTM therapy was 70% (8). These treatments are greatly expected to be useful modalities for treating AE-IPF, although it is necessary to confirm their efficacy in further

large-scale prospective studies.

Leukocytapheresis (LCAP) is a procedure that removes leukocytes during extracorporeal circulation. It has been proven that LCAP effectively treats patients with rheumatoid arthritis and ulcerative colitis (9, 10). Moreover, some reports indicate its efficacy in patients with progressive interstitial pneumonia (IP) associated with polymyositis or dermatomyositis (11, 12). The effectiveness of LCAP is through the removal of activated leukocytes (13). Some investigators have observed activated leukocytes such as neutrophils and macrophages in patients with AE of IIPs (AE-IIPs) (3, 14). Therefore, we hypothesized that LCAP may improve the general and respiratory condition of patients with AE-IIPs.

In this study, we investigated whether LCAP could improve the 30-day survival of patients with AE-IIPs. To evaluate the efficacy of LCAP, we also observed oxygenation, high-resolution computed tomography (HRCT) findings, and the serum or plasma levels of certain chemical mediators.

**PATIENTS AND METHODS**

Six patients with AE-IPF or AE of iNSIP were enrolled in this open-label pilot study of LCAP therapy. Idiopathic pulmonary fibrosis was diagnosed, based on HRCT criteria alone in accordance with the 2011 official American Thoracic Society/European Respiratory Society/Japanese Respiratory Society/Latin American Thoracic Association statement (1). All four of the following HRCT findings were required for a diagnosis of IPF : (1) subpleural and basal predominance ; (2) reticular abnormalities ; (3) honeycombing with or without traction bronchiectasis ; and (4) absence of features inconsistent with usual interstitial pneumonia pattern. Surgical lung biopsies remain the gold standard for the differential

Received for publication May 16, 2016 ; accepted December 21, 2016.

Address correspondence and reprint requests to Akihiro Yamamoto, MD, Division of Medical Oncology and Molecular Respiriology, Department of Multidisciplinary Internal Medicine, Faculty of Medicine, Tottori University, 86, Nishi-machi, Yonago, Tottori 683-8504, Japan and Fax : +81-859-38-6539.

diagnosis of IIPs. However, it is difficult to perform this procedure in many patients with AE because of the severity of the disease. Therefore, in this study, we clinically defined iNSIP as IP with the typical HRCT pattern of NSIP and without any other causes of interstitial lung disease. According to previous reports, typical HRCT findings of NSIP are bilateral, symmetric, predominantly lower lung reticular opacities with traction bronchiectasis and lower lobe volume loss (2, 15, 16). In all patients, other causes of interstitial lung disease such as occupational or environmental exposure, connective tissue disease, and drug-induced pneumonia were strictly excluded, based on their medical histories and clinical examinations.

An AE was defined, as follows : worsening dyspnea within days to weeks ; evidence of abnormal gas exchange, as defined by a low partial pressure of arterial oxygen (PaO<sub>2</sub>)/percentage of inspired oxygen ratio (P/F ratio) or a decrease in the PaO<sub>2</sub> ; new radiographic opacities ; and the absence of an alternative explanation such as infection, left heart failure, or pulmonary embolism (3). All of the aforementioned criteria were satisfied in each patient in this study. Ultrasound cardiography was performed to rule out congestive heart failure. All patients had no evidence of left ventricular dysfunction. Cultures of sputum, blood, and urine were examined for bacteria, fungi and mycobacteria, and were negative in all patients.

Leukocytapheresis was performed using a leukocyte removal filter (CS-180S, Cellsorba ; Asahi Kasei Medical Co., Tokyo, Japan). For venous access, a double-lumen catheter was inserted into the internal jugular vein under ultrasound guidance. Leukocytapheresis was performed on days 2, 3, 9 and 10. During each apheresis procedure, 3000 mL of whole blood was filtered and processed for 60-90 minutes using a blood pump at a speed of 30-50 mL/min. All patients received a continuous intravenous infusion of low-molecular-weight heparin (i.e., dalteparin sodium) at a dose of 75 IU/kg/day between days 1 and 14. All patients were treated with intravenous methylprednisolone pulse therapy (1000 mg/day on days 1-3 and 8-10), followed by oral prednisolone (1 mg/kg/day on days 4-7). The dosage of corticosteroids was gradually tapered after the second methylprednisolone pulse therapy. Specific neutrophil elastase (i.e., sivelestat sodium) and immunosuppressive agents were prohibited on days 1-10.

To evaluate the severity of the patients' general condition, we used the Sequential Organ Failure Assessment (SOFA) score on the admission of each patient. To evaluate the efficacy of LCAP therapy, we observed 30-day survival after the diagnosis of AE. High-resolution computed tomography scans were performed in the pre- and post-LCAP terms. The alveolar-arterial difference in oxygen (AaDO<sub>2</sub>) and the P/F ratio were calculated, based on the arterial blood gas analysis in both LCAP terms. Furthermore, we measured the serum levels of lactate dehydrogenase (LDH), sur-

factant protein (SP)-A, SP-D, Krebs von der Lugen-6 (KL-6), which may be useful biomarkers of IIPs. In the pre- and post-LCAP terms, we also determined the serum levels of interleukin (IL)-6, IL-18, tumor necrosis factor-alpha, interferon-gamma, monocyte chemotactic protein 1 (MCP-1), and high mobility group box-1 (HMGB-1), and the plasma levels of IL-8 and transforming growth factor-beta 1, which may have roles in AE-IIPs (17-21). Furthermore, we validated the safety of LCAP therapy through the verification of adverse events.

Written informed consent was obtained from all patients. The study was approved by the Ethics Committee of Tottori University Medical Department (Yonago, Japan).

All data were analyzed using the IBM SPSS Statics software version 23.0 for windows (IBM SPSS, Tokyo, Japan). We used the Wilcoxon signed-rank test to calculate statistical significance. Values of p < 0.05 were defined as statistically significant.

## RESULTS

The clinical characteristics of the patients with AE-IIPs are shown in Table 1. Between February 20, 2014, and September 14, 2015, six patients (five men, one woman) were enrolled in this study. The median age was 70 years (range, 65-83 years). The diagnosis was IPF for five patients and iNSIP in the other patient. Case 1 and 2 had received no previous therapy. Pirfenidone (1800 mg/day) had been administered to Cases 3, 5 and 6. Cases 4 and 5 had received oral prednisolone (7 mg/day and 20 mg/day, respectively). The average duration from the first radiologic abnormality to AE was 53 months (range, 25-105 months). The median SOFA score was 2 points (range, 1-3 points). The median P/F ratio and AaDO<sub>2</sub> were 271 (range, 205-304) and 53.5 mmHg (range, 35.0-97.2 mmHg), respectively. Before LCAP, the serum levels of LDH (normal range, < 229 IU/mL), KL-6 (normal range, < 500 IU/mL) and SP-A (normal range, < 43.8 ng/mL) were elevated in all six patients.

The clinical course of each patient is summarized in Figure 1. For all patients, we performed LCAP therapy, corticosteroid therapy, and a continuous intravenous infusion of low-molecular-weight heparin in compliance with the protocol. Five of six patients (Cases 1, 2, 3, 4 and 6) survived for more than 30 days after the diagnosis of AE. One patient (Case 5) died of progressive respiratory failure on hospital day 16. In Case 6, the recurrence of AE-IPF was observed on day 49. He had been treated with intravenous methylprednisolone pulse therapy (1000 mg/day daily), followed by intravenous prednisolone (1 mg/kg/day) after the recurrence. He died of respiratory failure on day 57. No recurrence of AE-IIPs was observed in Case 1, 2, 3 and 4 at least for a year. The AaDO<sub>2</sub> improved after LCAP therapy, except for Case 5. In addition, the serum level of LDH decreased after LCAP therapy in all survivors. We

Table 1 Characteristics of patients with acute exacerbation of idiopathic interstitial pneumonias

Case	Age/Sex	Duration (months)	SOFA score	P/F	AaDO <sub>2</sub> (mmHg)	LDH (IU/mL)	KL-6 (IU/mL)	SP-A (ng/mL)	Diagnosis	Previous therapy
1	70/M	105	2	238	60.4	384	1377	221.0	IPF	None
2	83/F	48	1	304	41.3	318	524	80.8	IPF	None
3	65/M	35	2	297	35.0	250	611	60.8	IPF	PFD
4	67/M	25	2	264	71.0	340	712	96.0	iNSIP	PSL+CsA
5	70/M	83	3	205	97.2	400	1865	134.0	IPF	PSL+PFD
6	74/M	58	3	278	46.6	414	2669	82.7	IPF	PFD

AaDO<sub>2</sub> : alveolar-arterial difference of oxygen, AE-IIPs : acute exacerbation of idiopathic interstitial pneumonias, CsA : cyclosporine, Duration : Duration from diagnosis, F : female, iNSIP : idiopathic nonspecific interstitial pneumonia, IPF : idiopathic pulmonary fibrosis, KL-6 : Krebs von der Lugen-6, LDH : lactate dehydrogenase, M : male, P/F : partial pressure of arterial oxygen/percentage of inspired oxygen (PaO<sub>2</sub>/FiO<sub>2</sub>) ratio, PFD : pirfenidone, PSL : prednisolone, SOFA score : Sequential Organ Failure Assessment score, SP-A : surfactant protein-A

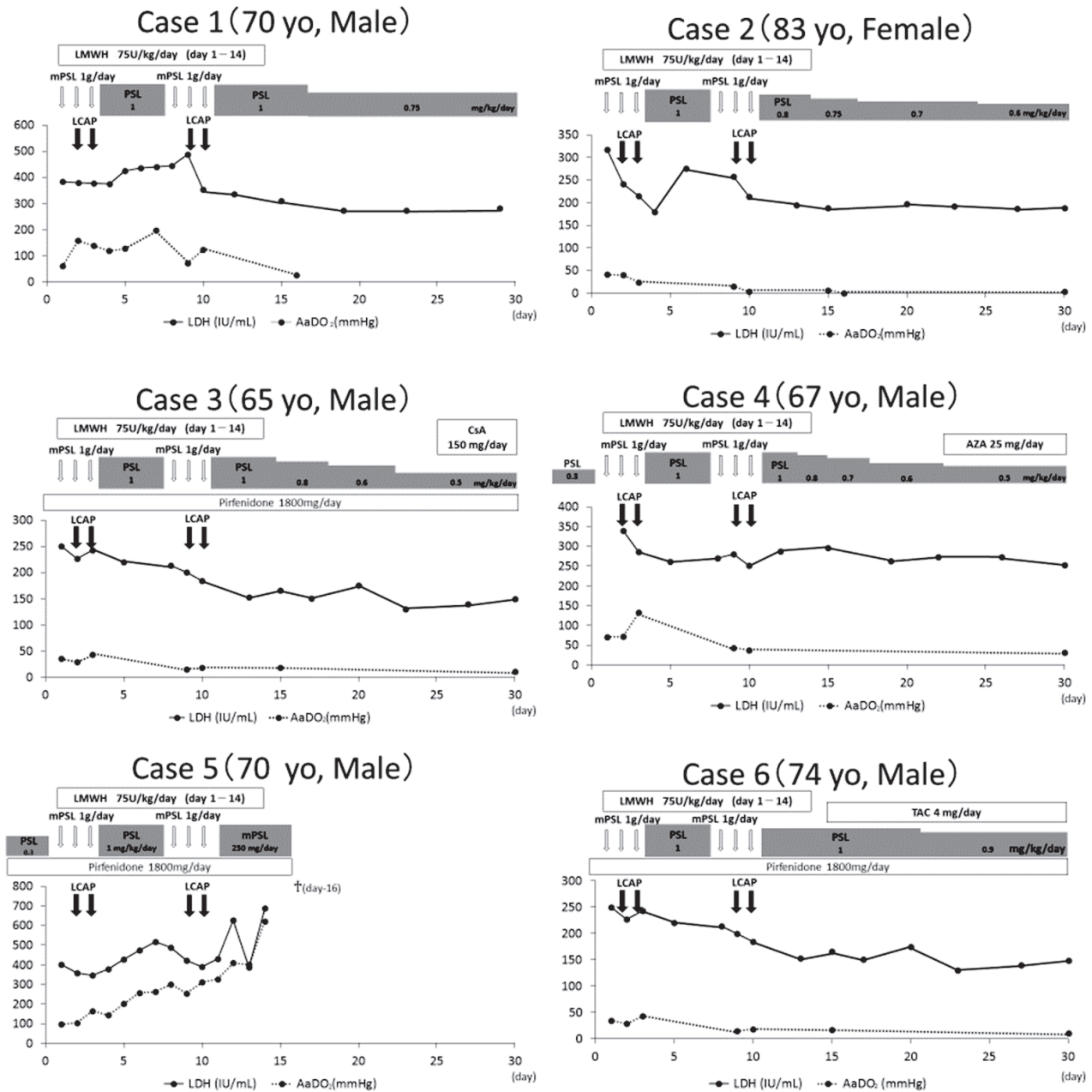


Figure 1. The clinical course of the patients. Five of six patients (Cases 1, 2, 3, 4 and 6) survived for more than 30 days after the diagnosis of AE. One patient (Case 5) died of progressive respiratory failure on hospital day 16. The AaDO<sub>2</sub> improved after LCAP treatment, except for the one fatal case. In addition, the serum level of LDH tended to decrease after LCAP treatment in all survivors. Corticosteroids were gradually decreased after LCAP therapy in all patients. After the 11<sup>th</sup> hospital day, CsA in Case 3, AZA in Case 4, and TAC in Case 6 were used. After the onset of AE, pirfenidone was continued in three patients (Cases 3, 5 and 6).

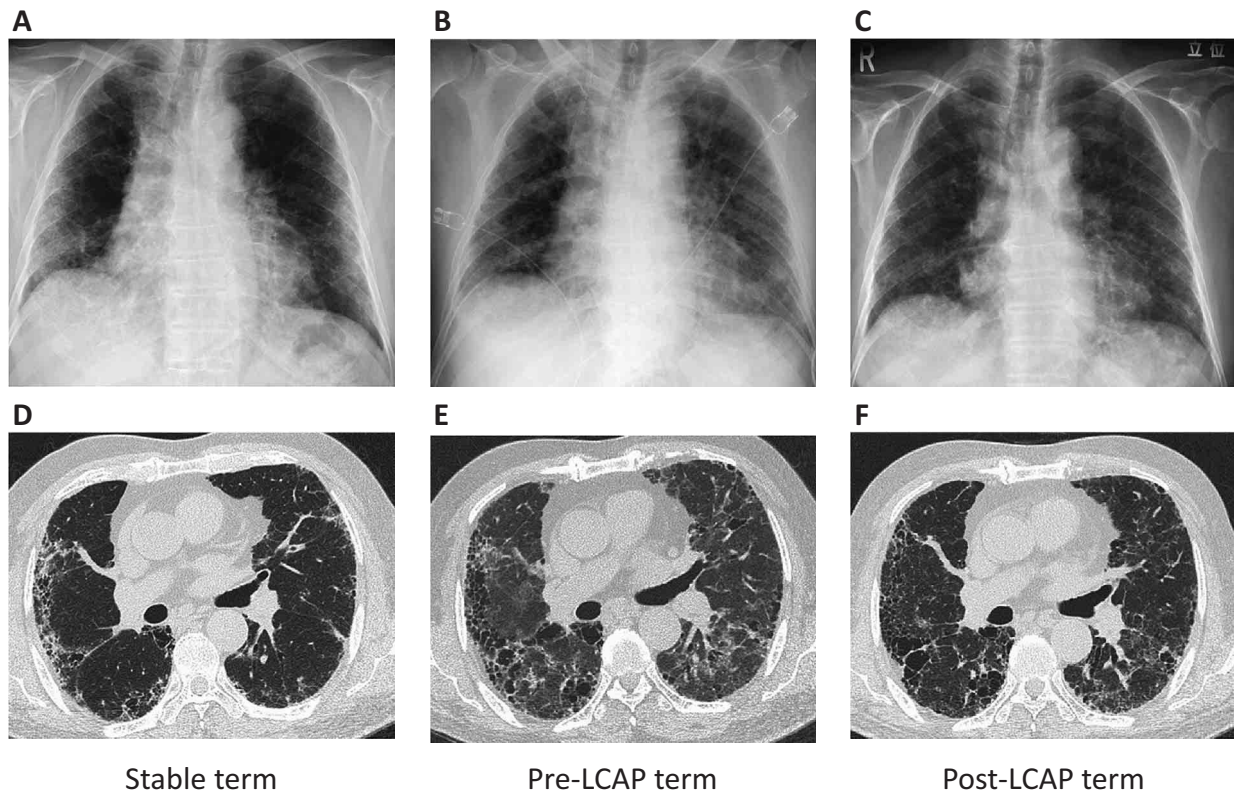
AaDO<sub>2</sub> : alveolar-arterial difference of oxygen, AE : acute exacerbation, AZA : azathioprine, CsA : cyclosporine, LCAP : leukocyapheresis, LDH : lactate dehydrogenase, LMWH : low-molecular-weight heparin, mPSL : methylprednisolone, PSL : prednisolone, TAC : tacrolimus, yo : years old

used immunosuppressive agents in three patients (Cases 3, 4 and 6) after hospital day 11. Pirfenidone was continued in all three patients after the onset of the AE (Cases 3, 5 and 6).

Diffuse parenchymal opacifications that were consistent with AE were newly observed on HRCT before LCAP in all patients. This finding tended to improve after LCAP therapy in the five survivors. We show a representative patient in Figure 2.

We validated the P/F ratio and the serum or plasma level of LDH, SP-A, SP-D, KL-6 and other chemical mediators in the pre- and

post-LCAP terms (Figure 3). In the post LCAP term, the P/F ratio was improved in all five survivors. The serum level of LDH significantly improved statistically in all patients in the post-LCAP term (p=0.028). The serum levels of SP-A and SP-D tended to improve in the survivors after LCAP therapy. In the post-LCAP term, the serum levels of HMGB-1 and IL-18 significantly decreased statistically in all patients (p=0.028 and p=0.027, respectively). By contrast, we could observe no such tendency in the level of KL-6, IL-6, IL-8, tumor necrosis factor- $\alpha$ , interferon- $\gamma$ , MCP-1, and



**Figure 2.** The CXR and HRCT images of a representative patient (Case 6). (A) The CXR image before AE shows bilateral and lower lung field-dominant reticular opacities. (B) The CXR image at the onset of AE shows newly developed bilateral infiltration. (C) The CXR image shows that the bilateral infiltrations tended to improve after LCAP treatment. (D) The HRCT image at the stable term before AE shows the features of subpleural reticular abnormalities and a honeycomb-like appearance with traction bronchiectasis, which are consistent with the UIP pattern. (E) The HRCT image at the onset of AE shows newly developed bilateral and nonsegmental ground glass opacities. (F) The HRCT image after LCAP treatment shows that the ground glass opacities tended to disappear.

AE : acute exacerbation, CXR : chest X-ray, HRCT : high-resolution computed tomography, LCAP : leukocytapheresis, UIP : usual interstitial pneumonia

transforming growth factor-beta 1 between the pre- and post-LCAP terms (data not shown).

We evaluated the safety of LCAP therapy in this study. Several mild adverse events were observed in four of six patients. Thrombocytopenia ( $< 100,000/\mu\text{L}$ ) was observed in four of six patients after LCAP. We had evaluated complete blood cell count after every 2 sessions of LCAP. Six instances of thrombocytopenia ( $< 100,000/\mu\text{L}$ ) were observed in total twelve evaluations. Severe thrombocytopenia ( $< 50,000/\mu\text{L}$ ) was observed in two instances. All four patients recovered at least seven days after LCAP sessions without any treatment. No major hemorrhage include intracranial and pulmonary bleeding was seen as a result of the thrombocytopenia. A decrease in the blood pressure occurred in three patients. Their blood pressure recovered after a reduction in the flow rate ; therefore, no patient required vasopressor treatment. One patient complained of chest discomfort during the first LCAP procedure. This complaint was improved by reducing the pump speed from 50 mL/min to 30 mL/min. No patient discontinued LCAP therapy because of any adverse events due to LCAP therapy.

## DISCUSSION

We investigated whether LCAP, which removes activated leukocytes, could be a promising candidate for treating AE-IIPs. In this open-label pilot study, five of six patients with AE-IIPs survived

for more than 30 days after the diagnosis of AE. Isshiki *et al.* reported that the 30-day survival rate of the similar severity AE-IPF patients treated by conventional corticosteroid treatment with low-molecular-weight heparin was a little less than 60% (22). In our study, the severity of the patients' disease was relatively mild. However, the survival rate of our study was not inferior to that of conventional corticosteroid treatment with low-molecular-weight heparin reported by Isshiki *et al.* Moreover, oxygenation and HRCT findings were recovered in all survivors. We performed LCAP therapy without any severe adverse effects. Therefore, LCAP appears to be a safe and effective therapy on AE-IIPs.

In our study, the peripheral blood platelets were decreased and recovered at least seven days after LCAP sessions without any treatments. This is similar to the previous studies in patients with rheumatoid arthritis and ulcerative colitis and healthy volunteers (23-25). It has been reported that the peripheral blood platelets were removed while passing through the column (26). We considered that thrombocytopenia was recovered by producing new platelets in bone marrow. Although it took several days for recovery of the thrombocytopenia, no hemorrhagic complications were seen as a result of it.

The serum level of LDH was elevated in the pre-LCAP term and significantly decreased in the post-LCAP term. The serum levels of SP-A and SP-D were also elevated in the pre-LCAP term and tended to decrease in the post-LCAP term. It has been reported that the serum level of LDH is a useful indicator of lung damage or

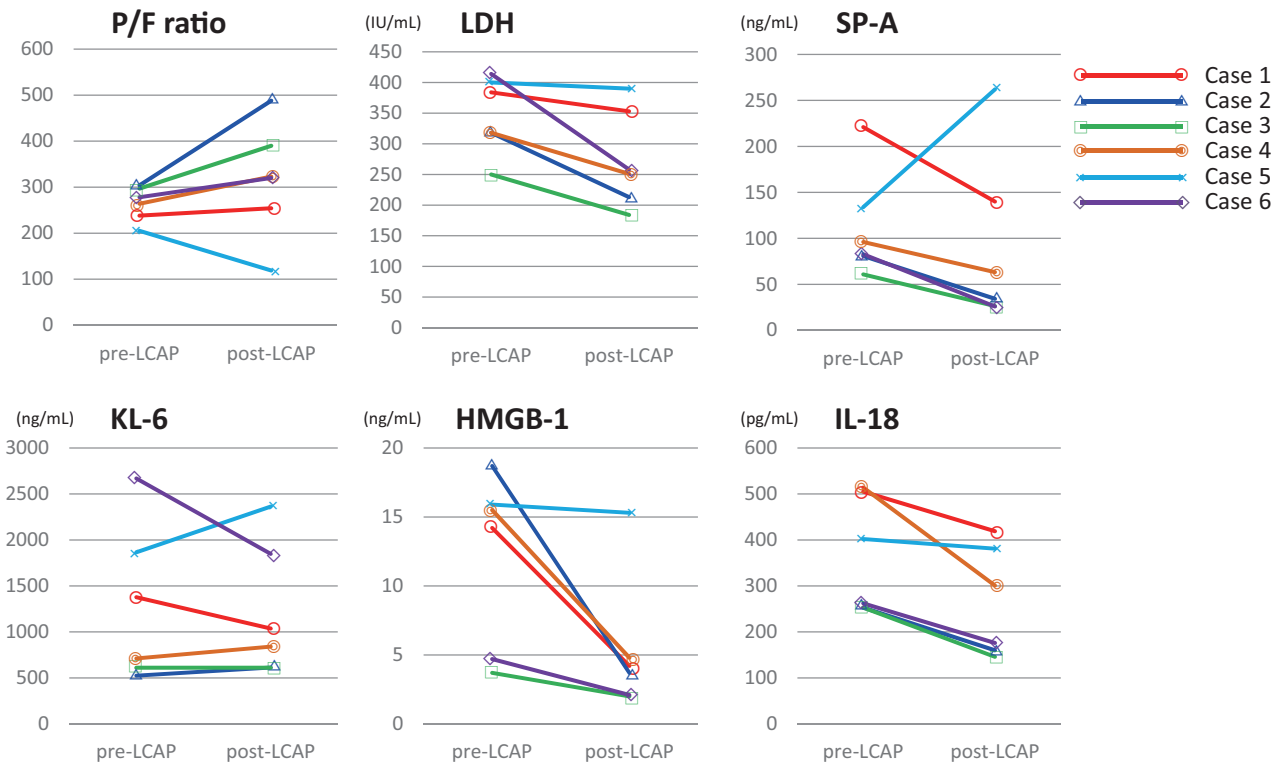


Figure 3. The change between the pre- and post-LCAP terms in the P/F ratio and in the serum levels of the chemical mediators LDH, SP-A, KL-6, HMGB-1 and IL-18. The serum level of LDH is significantly decreased in the post-LCAP term ( $p=0.028$ ). In the post-LCAP term, the P/F ratio and the serum level of SP-A tended to improve in all survivors (Cases 1, 2, 3, 4, and 6). No difference in the level of KL-6 exists between the pre- and post-LCAP terms. The serum levels of HMGB-1 and IL-18 are significantly decreased statistically in the post-LCAP term ( $p=0.028$  and  $p=0.027$ , respectively).

HMGB-1 : high mobility group box-1, IL-18 : interleukin-18, KL-6 : Krebs von der Lugen-6, LCAP : leukocytapheresis, LDH : lactate dehydrogenase, P/F ratio : partial pressure of arterial oxygen/percentage of inspired oxygen ( $\text{PaO}_2/\text{FiO}_2$ ) ratio, SP-A : surfactant protein-A

inflammation ; moreover, LDH is released into the peripheral blood after somatic cell death (27). On the other hand, SP-A and SP-D are proteins that are synthesized and secreted by type II alveolar epithelial cells (28). We believe that our results of LDH, SP-A and SP-D are owing to the suppression of parenchymal inflammation and damaged pulmonary epithelial cells by LCAP through the removal of activated leukocytes that produce proinflammatory/inflammatory cytokines. We believe that the improvement in the oxygenation and HRCT findings are caused by similar process of suppression of inflammation through LCAP therapy. However, we could observe no such tendencies in the level of KL-6 between the pre- and post-LCAP terms. The high-molecular-weight protein KL-6 (200 kDa and over) is expressed on human MUC-1 mucin and is quite abundant in intra-alveolar epithelial lining fluid (29). Because of its size and intra-alveolar distribution, the serum level of KL-6 may become elevated in the relatively late phase of inflammation after moderate to severe destruction of epithelial cells has occurred.

The mechanisms by which PMX treatment improves patients with AE are unclear ; however, various circulating molecules (e.g. MCP-1, HMGB-1, neutrophilic elastase, and IL-8) are decreased by the treatment (30-32). In this study, we also measured certain chemical mediators to investigate the mechanism of the efficacy of LCAP. We observed a statistically significant decrease in the serum level of HMGB-1 and IL-18 between the pre- and post-LCAP terms. The nuclear protein HMGB-1 (approximately 30 kDa) is actively secreted from leukocytes (20, 33), and may have important roles in modulating acute lung inflammation (20, 33, 34).

Furthermore, it has been demonstrated that intraperitoneal injections of anti-HMGB-1 antibody significantly attenuated lung inflammation in murine models (35). On the other hand, IL-18 is reportedly an inflammatory cytokine synthesized and secreted by leukocytes (36). It is expressed in most pulmonary cells, especially by fibroblastic foci, alveolar macrophages, and interstitial mononuclear cells of patients with IPF (21). He and colleagues reported that the secretion of IL-18 in THP-1 macrophages cultured with HMGB-1 and ATP showed significantly increased expression (37). In addition, HMGB-1 functions as a negative regulator of the inflammasome activation pathway in which caspase-1 is activated to promote the maturation of IL-18 (38). Therefore the linkage between HMGB-1 and IL-18 is not yet fully understood. However, it is possible that they have cooperative roles in pulmonary parenchymal inflammation. A significant decrease in the levels of HMGB-1 and IL-18 in the post-LCAP term can be caused by their anti-inflammatory cooperation during LCAP therapy. We also consider that HMGB-1 and IL-18 may be the therapeutic target molecules in patients with AE-IIPs.

Several researchers report that PMX treatment removed inflammatory cells-in particular, activated neutrophils and monocytes, which produce several inflammatory cytokines (32, 39). On the other hand, it has been confirmed that LCAP removes activated leukocytes that produce functional chemical mediators (13, 40). We believe that it is necessary to compare the efficacy of LCAP and that of PMX treatment in patients with AE-IIPs. Thrombomodulin can bind to HMGB-1, thereby inhibiting inflammation and coagulation (41, 42), although the previously reported efficacy of

rhTM in AE-IPF may be related to HMGB-1 inhibition. In the future, it is possible that the combined therapy of LCAP and rhTM will lead to a better prognosis for patients with AE-IIPs.

The recent study has several limitations. First, the number of patients in this study was very small. Second, although all patients met the diagnostic criteria for AE, the severity of the patients' disease was relatively mild. Third, it is difficult to exclude the effect of other treatments, especially high-dose corticosteroids, because this was a single-arm trial.

In this study, we concluded that LCAP could be a safe and effective procedure to treat the patients with AE-IIPs. A prospective study on PMX treatment is ongoing. However, we believe that our findings on LCAP therapy should also be validated in large-scale controlled trials because there are no established modalities to treat patients with AE-IIPs.

## COI

The authors declare that there are no conflicts of interest.

## ACKNOWLEDGMENTS

The authors thank anesthesiologists, medical engineers and nurses of Tottori University.

## REFERENCES

- Raghu G, Collard HR, Egan JJ, Martinez FJ, Behr J, Brown KK, Colby TV, Cordier JF, Flaherty KR, Lasky JA, Lynch DA, Ryu JH, Swigris JJ, Wells AU, Ancochea J, Bouros D, Carvalho C, Costabel U, Ebina M, Hansell DM, Johkoh T, Kim DS, King TE, Jr., Kondoh Y, Myers J, Muller NL, Nicholson AG, Richeldi L, Selman M, Dudden RF, Griss BS, Protzko SL, Schunemann HJ, Fibrosis AEJACoIP : An official ATS/ERS/JRS/ALAT statement : idiopathic pulmonary fibrosis : evidence-based guidelines for diagnosis and management. *Am J Respir Crit Care Med* 183 : 788-824, 2011
- Travis WD, Costabel U, Hansell DM, King TE, Jr., Lynch DA, Nicholson AG, Ryerson CJ, Ryu JH, Selman M, Wells AU, Behr J, Bouros D, Brown KK, Colby TV, Collard HR, Cordeiro CR, Cottin V, Crestani B, Drent M, Dudden RF, Egan J, Flaherty K, Hogaboam C, Inoue Y, Johkoh T, Kim DS, Kitaichi M, Loyd J, Martinez FJ, Myers J, Protzko S, Raghu G, Richeldi L, Sverzellati N, Swigris J, Valeyre D, Pneumonias AEColl : An official American Thoracic Society/European Respiratory Society statement : Update of the international multidisciplinary classification of the idiopathic interstitial pneumonias. *Am J Respir Crit Care Med* 188 : 733-748, 2013
- Collard HR, Moore BB, Flaherty KR, Brown KK, Kaner RJ, King TE, Jr., Lasky JA, Loyd JE, Noth I, Olman MA, Raghu G, Roman J, Ryu JH, Zisman DA, Hunninghake GW, Colby TV, Egan JJ, Hansell DM, Johkoh T, Kaminski N, Kim DS, Kondoh Y, Lynch DA, Muller-Quernheim J, Myers JL, Nicholson AG, Selman M, Toews GB, Wells AU, Martinez FJ, Idiopathic Pulmonary Fibrosis Clinical Research Network I : Acute exacerbations of idiopathic pulmonary fibrosis. *Am J Respir Crit Care Med* 176 : 636-643, 2007
- Song JW, Hong SB, Lim CM, Koh Y, Kim DS : Acute exacerbation of idiopathic pulmonary fibrosis : incidence, risk factors and outcome. *Eur Respir J* 37 : 356-363, 2011
- Agarwal R, Jindal SK : Acute exacerbation of idiopathic pulmonary fibrosis : a systematic review. *Eur J Intern Med* 19 : 227-235, 2008
- Abe S, Azuma A, Mukae H, Ogura T, Taniguchi H, Bando M, Sugiyama Y : Polymyxin B-immobilized fiber column (PMX) treatment for idiopathic pulmonary fibrosis with acute exacerbation : a multicenter retrospective analysis. *Internal medicine* 51 : 1487-1491, 2012
- Takada T, Asakawa K, Sakagami T, Moriyama H, Kazama J, Suzuki E, Narita I : Effects of direct hemoperfusion with polymyxin B-immobilized fiber on rapidly progressive interstitial lung diseases. *Internal medicine* 53 : 1921-1926, 2014
- Kataoka K, Taniguchi H, Kondoh Y, Nishiyama O, Kimura T, Matsuda T, Yokoyama T, Sakamoto K, Ando M : Recombinant Human Thrombomodulin in Acute Exacerbation of Idiopathic Pulmonary Fibrosis. *Chest* 148 : 436-443, 2015
- Ueki Y, Sagawa A, Tanimura K, Yamada A, Yamamoto K, Tsuda H, Tohma S, Suzuki K, Tominaga M, Kawabe Y, Mine M, Honda S, Tsukano M, Nakamura T, Hidaka T, Eguchi K : A multicenter study of leukocytapheresis in rheumatoid arthritis. *Clin Exp Rheumatol* 25 : 810-816, 2007
- Nishioka C, Aoyama N, Maekawa S, Shirasaka D, Nakahara T, Tamura T, Fukagawa M, Umezumi M, Abe T, Kasuga M : Leukocytapheresis therapy for steroid-naive patients with active ulcerative colitis : its clinical efficacy and adverse effects compared with those of conventional steroid therapy. *J Gastroenterol Hepatol* 20 : 1567-1571, 2005
- Nishide T, Matsumura R, Yamaguchi T, Moriwaki K, Matsugane T, Yamane S, Azuma N, Suzuki M : Long Term Efficacy of Leukocytapheresis (LCAP) Therapy in a Case of Interstitial Pneumonia Associated with Dermatomyositis. *Japanese Journal of Apheresis* 27 : 61-67, 2008
- Komeda M, Sanaka T, Hayashi M, Nishimura H, Higuchi C, Takeda H, Ootsuka K : Effect of leukocytapheresis on interstitial pneumonia with polymyositis. *Respiration Research* 28 : 1137-1142, 2009
- Hidaka T, Suzuki K, Matsuki Y, Takamizawa-Matsumoto M, Kataharada K, Ishizuka T, Kawakami M, Nakamura H : Filtration leukocytapheresis therapy in rheumatoid arthritis : a randomized, double-blind, placebo-controlled trial. *Arthritis Rheum* 42 : 431-437, 1999
- Schupp JC, Binder H, Jager B, Cillis G, Zissel G, Muller-Quernheim J, Prasse A : Macrophage activation in acute exacerbation of idiopathic pulmonary fibrosis. *PLoS One* 10 : e0116775, 2015
- American Thoracic Society, European Respiratory Society : American Thoracic Society/European Respiratory Society International Multidisciplinary Consensus Classification of the Idiopathic Interstitial Pneumonias. This joint statement of the American Thoracic Society (ATS), and the European Respiratory Society (ERS) was adopted by the ATS board of directors, June 2001 and by the ERS Executive Committee, June 2001. *Am J Respir Crit Care Med* 165 : 277-304, 2002
- Travis WD, Hunninghake G, King TE, Jr., Lynch DA, Colby TV, Galvin JR, Brown KK, Chung MP, Cordier JF, du Bois RM, Flaherty KR, Franks TJ, Hansell DM, Hartman TE, Kazerooni EA, Kim DS, Kitaichi M, Koyama T, Martinez FJ, Nagai S, Midthun DE, Muller NL, Nicholson AG, Raghu G, Selman M, Wells A : Idiopathic nonspecific interstitial pneumonia : report of an American Thoracic Society project. *Am J Respir Crit Care Med* 177 : 1338-1347, 2008
- Ohnishi H, Yokoyama A, Kondo K, Hamada H, Abe M, Nishimura K, Hiwada K, Kohno N : Comparative study of KL-6, surfactant protein-A, surfactant protein-D, and monocyte chemoattractant protein-1 as serum markers for interstitial lung diseases. *Am J Respir Crit Care Med* 165 : 378-381, 2002
- Pantelidis P, Fanning GC, Wells AU, Welsh KI, Du Bois RM : Analysis of tumor necrosis factor-alpha, lymphotoxin-alpha,

- tumor necrosis factor receptor II, and interleukin-6 polymorphisms in patients with idiopathic pulmonary fibrosis. *Am J Respir Crit Care Med* 163 : 1432-1436, 2001
19. Coker RK, Laurent GJ : Pulmonary fibrosis : cytokines in the balance. *Eur Respir J* 11 : 1218-1221, 1998
  20. Li LC, Gao J, Li J : Emerging role of HMGB1 in fibrotic diseases. *J Cell Mol Med* 18 : 2331-2339, 2014
  21. Kitasato Y, Hoshino T, Okamoto M, Kato S, Koda Y, Nagata N, Kinoshita M, Koga H, Yoon DY, Asao H, Ohmoto H, Koga T, Rikimaru T, Aizawa H : Enhanced expression of interleukin-18 and its receptor in idiopathic pulmonary fibrosis. *Am J Respir Cell Mol Biol* 31 : 619-625, 2004
  22. Isshiki T, Sakamoto S, Kinoshita A, Sugino K, Kurosaki A, Homma S : Recombinant human soluble thrombomodulin treatment for acute exacerbation of idiopathic pulmonary fibrosis : a retrospective study. *Respiration* 89 : 201-207, 2015
  23. Shirokaze J : Leukocytapheresis using a leukocyte removal filter. *Ther Apher* 6 : 261-266, 2002
  24. Sawada K, Ohnishi K, Kosaka T, Chikano S, Yokota Y, Egashira A, Izawa H, Yamamura M, Amano K, Satomi M, Shimoyama T : Leukocytapheresis with leukocyte removal filter as new therapy for ulcerative colitis. *Ther Apher* 1 : 207-211, 1997
  25. Yamaji K, Yang K, Tsuda H, Hashimoto H : Fluctuations in the peripheral blood leukocyte and platelet counts in leukocytapheresis in healthy volunteers. *Ther Apher* 6 : 402-412, 2002
  26. Mitsuyama K, Andoh A, Masuda J, Yamasaki H, Kuwaki K, Takedatsu H, Seki R, Nishida H, Tsuruta O, Sata M : Mobilization of bone marrow cells by leukocytapheresis in patients with ulcerative colitis. *Ther Apher Dial* 12 : 271-277, 2008
  27. Drent M, Cobben NA, Henderson RF, Wouters EF, van Dieijen-Visser M : Usefulness of lactate dehydrogenase and its isoenzymes as indicators of lung damage or inflammation. *Eur Respir J* 9 : 1736-1742, 1996
  28. Ley B, Brown KK, Collard HR : Molecular biomarkers in idiopathic pulmonary fibrosis. *Am J Physiol Lung Cell Mol Physiol* 307 : L681-691, 2014
  29. Ishizaka A, Matsuda T, Albertine KH, Koh H, Tasaka S, Hasegawa N, Kohno N, Kotani T, Morisaki H, Takeda J, Nakamura M, Fang X, Martin TR, Matthay MA, Hashimoto S : Elevation of KL-6, a lung epithelial cell marker, in plasma and epithelial lining fluid in acute respiratory distress syndrome. *Am J Physiol Lung Cell Mol Physiol* 286 : L1088-1094, 2004
  30. Hara S, Ishimoto H, Sakamoto N, Mukae H, Kakugawa T, Ishimatsu Y, Mine M, Kohno S : Direct hemoperfusion using immobilized polymyxin B in patients with rapidly progressive interstitial pneumonias : a retrospective study. *Respiration* 81 : 107-117, 2011
  31. Abe S, Hayashi H, Seo Y, Matsuda K, Kamio K, Saito Y, Usuki J, Azuma A, Kudo S, Gemma A : Reduction in serum high mobility group box-1 level by polymyxin B-immobilized fiber column in patients with idiopathic pulmonary fibrosis with acute exacerbation. *Blood Purif* 32 : 310-316, 2011
  32. Kushi H, Miki T, Okamoto K, Nakahara J, Saito T, Tanjoh K : Early hemoperfusion with an immobilized polymyxin B fiber column eliminates humoral mediators and improves pulmonary oxygenation. *Crit Care* 9 : R653-661, 2005
  33. Lotze MT, Tracey KJ : High-mobility group box 1 protein (HMGB1) : nuclear weapon in the immune arsenal. *Nat Rev Immunol* 5 : 331-342, 2005
  34. Ueno H, Matsuda T, Hashimoto S, Amaya F, Kitamura Y, Tanaka M, Kobayashi A, Maruyama I, Yamada S, Hasegawa N, Soejima J, Koh H, Ishizaka A : Contributions of high mobility group box protein in experimental and clinical acute lung injury. *Am J Respir Crit Care Med* 170 : 1310-1316, 2004
  35. Hamada N, Maeyama T, Kawaguchi T, Yoshimi M, Fukumoto J, Yamada M, Yamada S, Kuwano K, Nakanishi Y : The role of high mobility group box1 in pulmonary fibrosis. *Am J Respir Cell Mol Biol* 39 : 440-447, 2008
  36. Sedimbi SK, Hagglof T, Karlsson MC : IL-18 in inflammatory and autoimmune disease. *Cell Mol Life Sci* 70 : 4795-4808, 2013
  37. He Q, You H, Li XM, Liu TH, Wang P, Wang BE : HMGB1 promotes the synthesis of pro-IL-1beta and pro-IL-18 by activation of p38 MAPK and NF-kappaB through receptors for advanced glycation end-products in macrophages. *Asian Pac J Cancer Prev* 13 : 1365-1370, 2012
  38. Yanai H, Matsuda A, An J, Koshiba R, Nishio J, Negishi H, Ikushima H, Onoe T, Ohdan H, Yoshida N, Taniguchi T : Conditional ablation of HMGB1 in mice reveals its protective function against endotoxemia and bacterial infection. *Proc Natl Acad Sci U S A* 110 : 20699-20704, 2013
  39. Ono S, Tsujimoto H, Matsumoto A, Ikuta S, Kinoshita M, Mochizuki H : Modulation of human leukocyte antigen-DR on monocytes and CD16 on granulocytes in patients with septic shock using hemoperfusion with polymyxin B-immobilized fiber. *Am J Surg* 188 : 150-156, 2004
  40. Hibi T, Sakuraba A : Is there a role for apheresis in gastrointestinal disorders? *Nat Clin Pract Gastroenterol Hepatol* 2 : 200-201, 2005
  41. Abeyama K, Stern DM, Ito Y, Kawahara K, Yoshimoto Y, Tanaka M, Uchimura T, Ida N, Yamazaki Y, Yamada S, Yamamoto Y, Yamamoto H, Iino S, Taniguchi N, Maruyama I : The N-terminal domain of thrombomodulin sequesters high-mobility group-B1 protein, a novel antiinflammatory mechanism. *J Clin Invest* 115 : 1267-1274, 2005
  42. Conway EM : Thrombomodulin and its role in inflammation. *Semin Immunopathol* 34 : 107-125, 2012