

## CASE REPORT

# Arthroscopic excision of unstable *os acromiale* associated with impingement syndrome : a case report

Shinji Kawaguchi, Shoji Fukuta, Takahiko Tsutsui, Tetsuya Matsuura, Naoto Suzue, Daisuke Hamada, Tomohiro Goto, Ryo Miyagi, Keizo Wada, Kenichiro Kita, Shunsuke Tamaki, Toshihiko Matsumura, Akihiro Nagamachi, and Koichi Sairyō

\*Department of Orthopedics, Tokushima University, 3-18-15 Kuramoto-cho, Tokushima, Japan

**Abstract :** *Os acromiale* is a rare anatomical variant that is caused by failure of fusion of the acromial apophysis and is usually asymptomatic. We report a case of impingement syndrome of the left shoulder secondary to unstable *os acromiale*, which was initially overlooked and confirmed only during arthroscopic examination. Arthroscopic excision of the unstable fragment was successful without residual dysfunction of the deltoid muscle. *J. Med. Invest.* 63 : 131-134, February, 2016

**Keywords :** *os acromiale*, impingement, arthroscopic excision, shoulder

## INTRODUCTION

The acromial apophysis develops from four separate centers of ossification : pre-acromion, meso-acromion, meta-acromion, and basi-acromion (1). Complete union of all centers may occur by the age of 25 years (2). *Os acromiale* is a failure of union of the acromial apophysis of the scapula, with a reported incidence ranging from 1% to 18.2% (1, 3, 4). Bilateral involvement is found in 33.3-62% of cases. It is thought to be an anatomical variant of the scapula and rarely causes shoulder pain.

Although *os acromiale* is usually identified incidentally on plain axillary radiograph of the shoulders, shoulder pain has been reported in the literature (5-10). Conservative treatment with muscle strengthening, stretching, anti-inflammatory medications, and steroid injections is the first option for symptomatic *os acromiale*. However, surgical treatment may be required if conservative treatment fails. Several surgical treatments, including excision by open or arthroscopic procedure, arthroscopic acromioplasty, and internal fixation with or without bone graft, have been described with mixed clinical outcomes (5-10). The optimal surgical option is therefore controversial.

We present a case of unstable *os acromiale* in an elderly patient who was diagnosed with an impingement syndrome with intact rotator cuff. Unstable *os acromiale* was identified during arthroscopic examination. Retrospective review of the preoperative magnetic resonance imaging (MRI) and computed tomography (CT) arthrogram showed *os acromiale* between the meso-acromion and meta-acromion. Arthroscopic excision resolved the pain and improved the shoulder functions. Based on this case report, we recommend that clinicians include this pathology in the differential diagnosis of impingement syndrome of the shoulder.

## CASE REPORT

A 73-year-old, right-hand dominant woman presented with a 2-month history of pain in the left shoulder with no history of trauma. The pain was described to be moderate in severity and was associated with active flexion and abduction, but not at rest. Physical examination showed that she had no limited range of motion, with active forward flexion to 170°, abduction to 170°, external rotation to 70°, and internal rotation up to the eighth thoracic spine with the arm on the side. Passive range of motion findings was the same as those during active range of motion. Neer's impingement sign was positive. Plain radiographs at that time were interpreted by the orthopedic surgeon as mild arthritic change in the glenohumeral joint (Fig. 1).

The patient underwent physical therapy for 6 months, which failed to relieve the shoulder pain. Arthroscopic subacromial decompression was then planned. Moderate-grade chondrosis was noted in both the humeral head and glenoid surface of the glenohumeral joint. The long head of the biceps and the articular surface of the rotator cuff were normal. During examination of the subacromial bursa, abnormal mobility of the anterolateral acromion was seen. Retrospective review of the CT scan and MRI revealed the presence of *os acromiale* (Figs. 2 and 3) between the meso-acromion and the meta-acromion (*meso-acromiale*). Hypertrophy and degenerative changes at the junction of the *os meso-acromiale* and the acromion were also seen. Arthroscopically, the *os meso-acromiale* was carefully excised with a motorized shaver, leaving the periosteal sleeve and deltoid fascial insertion intact (Fig. 4). Rotator cuff tear was not identified from the bursal side.

Post-operatively, the left shoulder was placed in a sling for 2 weeks, followed by mild range of motion exercises. Three months post-operatively, CT scan showed complete excision of the *meso-acromiale* (Fig. 5). The patient regained full shoulder range of motion 3 months after arthroscopic excision. At the final follow-up 27 months post-operatively, she had no functional deficits and the UCLA shoulder score (11) improved from 14 to 35.

Received for publication October 5, 2015 ; accepted October 28, 2015.

Address correspondence and reprint requests to Shoji Fukuta, MD, PhD, Associate Professor, Department of Orthopedics, Tokushima University 3-18-15 Kuramoto, Tokushima 770-8503, Japan and Fax : +81-88-633-0178.

## DISCUSSION

*Os acromiale* results from a failure of osseous fusion between

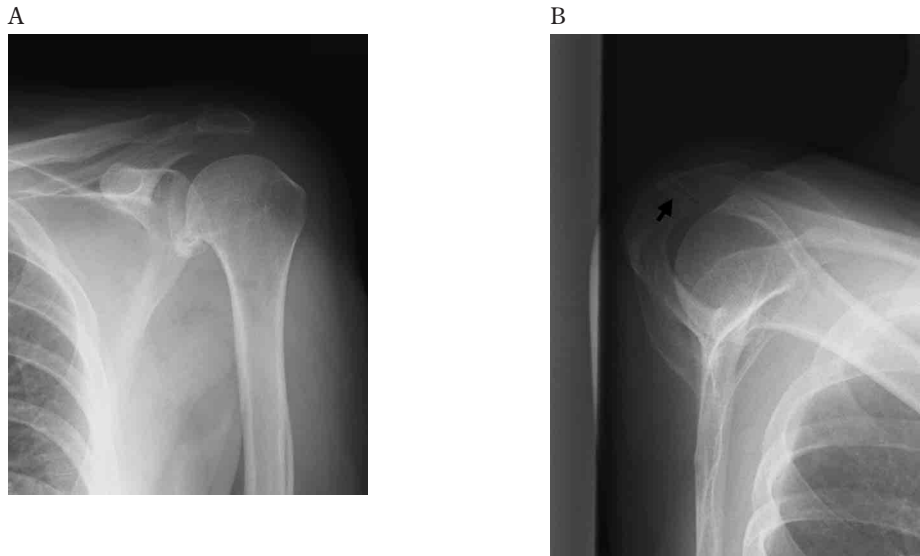


Fig. 1 Plain radiographs of the left shoulder of an elderly patient with *os acromiale*. Mild degenerative arthritis is demonstrated on the anteroposterior view (A). Non-union between the meso-acromion and the meta-acromion (arrow) is noted on the scapular outlet view (B).

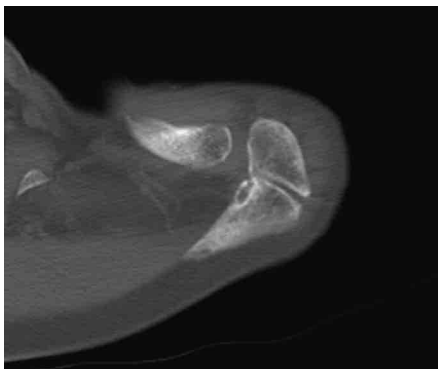


Fig. 2 Computed tomography scan of an elderly patient with *os acromiale* of the left shoulder. Sclerotic and cystic changes around the pseudoarthrosis are seen.

any two apophyses, most commonly between the meso-acromion and the meta-acromion. It is usually asymptomatic and discovered by chance on radiographs, CT, or MRI of the shoulder. Although *os acromiale* is often associated with rotator cuff tear and impingement syndrome (5), no clinical study has revealed that the presence of *os acromiale* results in a predisposition to rotator cuff disease (12).

Nevertheless, successful outcomes of surgical treatment for symptomatic *os acromiale* suggest that this pathology may still be clinically relevant. Bone marrow edema on MRI and increased uptake on bone scan strongly suggest that inflammation secondary to abnormal motion of the fragment at the non-union site may cause shoulder pain (12, 13). The pain may be due to inflammation or caused by abnormal motion at the site of non-union. Inferior tilting of the *os* fragment during contraction of the deltoid muscle may be another possible mechanism for subacromial impingement associated with this condition (6).

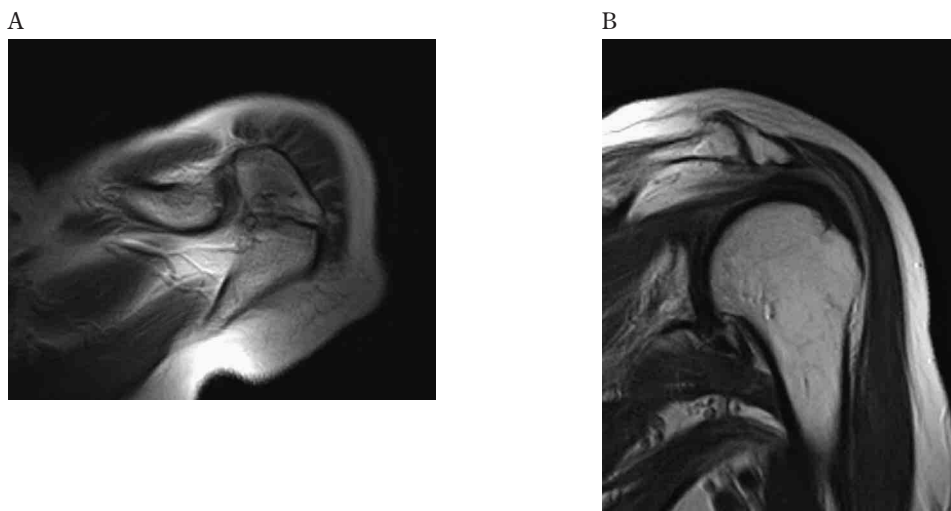


Fig. 3 Magnetic resonance imaging in an elderly patient with *os acromiale* of the left shoulder. T2-weighted axial image (A) and T2-weighted oblique coronal image (B) clearly demonstrate the *os acromiale* with irregular margins. There was no fluid-like signal within the interface. The rotator cuff is not torn.

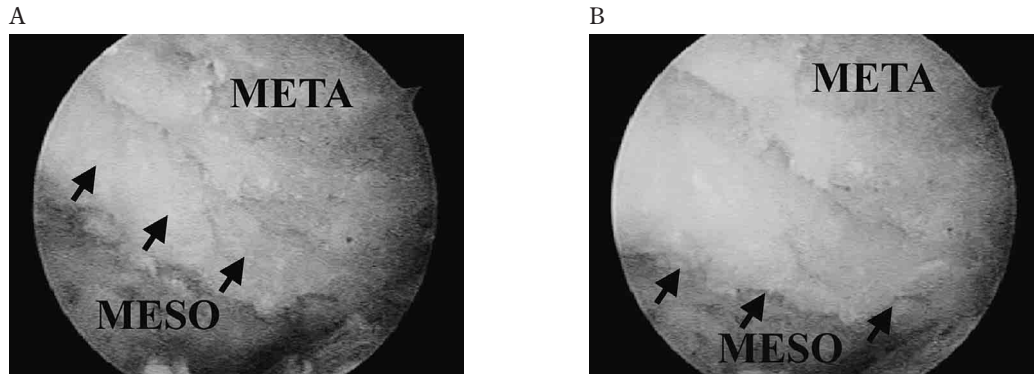


Fig. 4 Arthroscopy findings in an elderly patient with *os acromiale* of the left shoulder. Failure of union of the meso-acromion (MESO) and the meta-acromion (META) is demonstrated (A). The *meso-acromiale* was easily pushed down when the fragment was pressed over the skin (B) (black arrows)

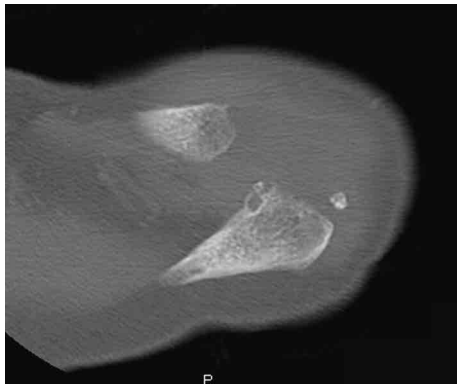


Fig. 5 Computed tomography scan of an elderly patient with *os acromiale* of the left shoulder after excision. Post-operative CT scan shows that *os acromiale* was completely excised.

Conservative therapies with non-steroidal anti-inflammatory drugs, physical therapy, and subacromial corticosteroid injection have been recommended for initial treatment of symptomatic *os acromiale*. If conservative management over a few months fails, surgical intervention may be warranted. Various surgical options have been reported with mixed clinical outcomes.

Open excision for unstable *os acromiale* is recommended only for pre-acromiale with a small fragment because in this case, the attachment of the deltoid muscle is not disrupted. Excision of a large fragment may lead to dysfunction of the deltoid muscle. Neer and Marberry described that radical acromionectomy weakened the deltoid by removing its lever arm and by encouraging retraction (7). Mudge *et al.* reported excellent clinical results of patients who underwent fragment excision and rotator cuff repair; however, two of six patients had unsatisfactory results (5). They concluded that large fragments should be retained and fixed.

Arthroscopic subacromial decompression is another option for symptomatic stable *os acromiale* associated with the impingement syndrome (8). Hutchinson and Veenstra described recurrence of pain after a period of symptom relief from arthroscopic decompression (9). Wright and associates described a modified subacromial decompression procedure with more aggressive bony resection than the typical arthroscopic acromioplasty (10). This procedure retained the superficial cortical shell of the *os acromiale* and its deltoid attachment and led to satisfactory results in 12 of 13 patients. However, residual instability of the fragment may result in

shoulder pain after subacromial decompression.

Open reduction and internal fixation with concomitant bone grafting may be the most ideal procedure because it allows preservation of both the large fragment and anterior deltoid function. The range of reported rates for successful union after surgical repair of *os acromiale* is wide. Peckett *et al.* reported a 96% union rate after tension band wiring and bone grafting in 26 patients (9), whereas Warner *et al.* observed a 58% rate of complete union in 12 patients (6). Furthermore, most of the patients required a second procedure of hardware removal, secondary to hardware-related discomfort or pain, even after the non-union healed.

In our case, arthroscopic excision of *meso-acromiale* was selected because of the patient's old age and low activity. By this method, the periosteal sleeve and deltoid attachment could be preserved to avoid dysfunction of the deltoid, which is the most common disadvantage of open excision. In addition, the minimally invasive arthroscopic procedure allowed the patient to move her shoulder earlier, which led to rapid post-operative functional recovery. Pangani *et al.* have reported satisfactory results of arthroscopic excision in 9 young athletes, with no deficits in abduction or rotation strength (10).

Although we initially misdiagnosed the condition as impingement syndrome, the pre-operative images clearly demonstrated the presence of *os acromiale*. The symptoms of a painful *os acromiale* may strongly resemble those seen in impingement syndrome; therefore, this anatomical variation should be considered in the differential diagnosis in patients with suspected impingement syndrome.

## CONCLUSION

We report a case of impingement syndrome of the shoulder secondary to unstable *os acromiale*. *Os acromiale* is rare but clinicians should be aware of this pathology.

## REFERENCES

1. Liberson F : *Os acromiale* - contested anatomy. *J Bone Joint Surg* 19 : 683-689, 1937
2. McClure JG, Raney RB : Anomalies of the scapula. *Clin Orthop* 110 : 22-31, 1975
3. Case DT, Burnett SE, Nielsen T : *Os acromiale* : population differences and their etiological significance. *Homo* 57 : 1-18, 2006

4. Sammarco VJ : Os acromiale : frequency, anatomy, and clinical implications. *J Bone Joint Surg Am* 82 : 394-400, 2000
5. Mudge MK, Wood VE, Frykman GK : Rotator cuff tears associated with os acromiale. *J Bone Joint Surg Am* 66 : 427-429, 1984
6. Warner JJ, Beim GM, Higgins L : The treatment of symptomatic os acromiale. *J Bone Joint Surg Am* 80 : 1320-6, 1998
7. Neer CS II, Marberry TA : On the disadvantages of radical acromionectomy. *J Bone Joint Surg Am* 63 : 416-9, 1981
8. Boehm TD, Matzer M, Brazda D, Gohlke FE : Os acromiale associated with tear of the rotator cuff treated operatively. Review of 33 patients. *J Bone Joint Surg Br* 85 : 545-9, 2003
9. Peckett WR, Gunther SB, Harper GD, Hughes JS, Sonnabend DH : Internal fixation of symptomatic os acromiale : a series of twenty-six cases. *J Shoulder Elbow Surg* 13 : 381-5, 2004
10. Pagnani MJ, Mathis CE, Solman CG : Painful os acromiale (or unfused acromial apophysis) in athletes. *J Shoulder Elbow Surg* 15 : 432-5, 2006
11. Amstutz HC, Sew Hoy AL, Clarke IC : UCLA anatomic total shoulder arthroplasty. *Clin Orthop* 155 : 7-20, 1981
12. Ouellette H, Thomas BJ, Kassarian A, Fritz B, Tétreault P, Palmer WE, Torriani M : Re-examining the association of os acromiale with supraspinatus and infraspinatus tears. *Skeletal Radiol* 36 : 835-9, 2007
13. Winfeld M, Rosenberg ZS, Wang A, Bencardino J : Differentiating os acromiale from normally developing acromial ossification centers using magnetic resonance imaging. *Skeletal Radiol* 44 : 667-72, 2015