

## ORIGINAL

# The effect of G-CSF in a myocardial ischemia reperfusion model rat

Kiyoshi Ieishi, Masahiro Nomura\*, Tomohito Kawano\*\*, Sayuri Fujimoto\*\*, Hiroyuki Ikefuji\*\*, Yoshiko Noda, Akiyoshi Nishikado, and Susumu Ito\*\*

*Division of Cardiology, Kagawa Prefectural Shirotori Hospital ; Kagawa, Japan \*Faculty of Integrated Art and Sciences, Department of Human and Social Sciences, and \*\*Department of Digestive and Cardiovascular Medicine, Institute of Health Biosciences, The University of Tokushima Graduate School, Tokushima, Japan*

**Abstract : Purpose :** It has been reported that G-CSF administration improves cardiac function by reducing the area of the infarct in a myocardial infarction model rat. In the present study, myocardial infarction model rats, produced by ligation of the left anterior coronary artery, were prepared. The G-CSF effect for treating cardiac muscle cell disorders by ischemia reperfusion was studied. **Methods :** Myocardial infarction model rats were produced by ligation of the left anterior descending coronary artery in 12-week-old Wistar rats. G-CSF was administered subcutaneously daily at a dose of 100  $\mu\text{g}/\text{kg}/\text{day}$  for 5 days to rats with a complete ligation (MI-G group, n=6) and rats in which the ligated coronary artery was reperfused 30 minutes after the ligation (R-G group, n=6). Physiological saline was subcutaneously administered to rats with a complete ligation and reperfusion (MI-C and R-C groups, respectively, n=6 each), as controls. After 4 weeks, the infarct area ratio (%), cardiac function on echocardiography (left ventricular ejection fraction), and a myocardial histopathological diagnosis were carried out and the results compared among the groups. **Results :** No significant differences were found in the proportion of the residual heart muscle in the infarct lesion, myocardial wall thickness, or left ventricular ejection fraction between the MI-G and MI-C groups. In contrast, the infarct area, myocardial wall thickness, and left ventricular ejection fraction were significantly improved in the R-G group compared to the R-C group ( $p < 0.05$ ). **Conclusions :** Any inhibitory effect of G-CSF on the infarct lesion was found in the myocardial infarction reperfusion model rat, but only a small effect was found in rats with a complete ligation-induced myocardial infarction. The findings in the present study, therefore, suggest that G-CSF is effective for treating cardiac muscle cell disorders by ischemia reperfusion. *J. Med. Invest.* 54 : 177-183, February, 2007

**Keywords :** G-CSF, myocardial infarction, reperfusion, coronary artery

## INTRODUCTION

It has been reported that G-CSF administration im-

---

Received for publication November 30, 2006 ; accepted January 10, 2007.

Address correspondence and reprint requests to Dr. Masahiro Nomura, M.D., Ph.D., Faculty of Integrated Art and Sciences, Department of Human and Social Sciences, The University of Tokushima, Minami Jyosanjima-cho, Tokushima 760-8502, Japan and Fax : +81-88-656-6173.

proves cardiac function by reducing the area of the infarct, leading to a decreased mortality in a rat myocardial infarction model. In 2001, inhibition of postinfarction cardiac remodeling, improvement in cardiac function, and a reduction in the mortality rate by the administration of granulocyte colony-stimulating factor (G-CSF) and stem cell factor (SCF) were reported (1).

In the present study, myocardial infarction model rats were prepared by ligation of the left anterior descending coronary artery, and G-CSF was administered to rats with a complete ligation and with reperfusion of the ligation-induced infarction. In the present study, the G-CSF effect for treating cardiac muscle cell disorders by ischemia reperfusion was studied.

## METHODS

### 1) Myocardial infarction and the reperfusion rat model

After the induction of general anesthesia by a intraperitoneal injection of 35 mg/kg pentobarbital (Nembutal<sup>®</sup>, Dainippon-Sumitomo Pharmaceutical Co., Ltd., Osaka, Japan) in Wistar rats (12-week-old, 250 g body weight), a midline skin incision was made in the anterior cervical region, and the sternohyoid muscle was divided in the middle to expose the trachea. Half circumference of an inter-tracheal cartilage region was incised, and an artificial respiration Y-piece (2.0Φ) was inserted and fixed by suturing. A respirator (SN-480-7, Shinano manufacturing Co., Ltd. Tokyo, Japan) was set to 1 ml/100 g body weight and a respiratory rate of 80 times/min. The thorax was opened via the left 4-5th intercostal region, using a rib spreader (retractor, MY-9454S, Matsuyoshi & Co., Ltd., Tokyo, Japan). Electrocardiography (ECG) electrodes were attached to the bilateral front legs and rear ankles with ECG paste (Keratin cream, Fukuda Denshi, Tokyo, Japan), and a limb-lead ECG was recorded (LABO-SYSTEM ZS-501, Fukuda ME, Tokyo, Japan). The retractor was detached during the ECG recording.

Fig. 1 shows an example of a limb-lead ECG before and after ligation of the left anterior descending coronary artery on thoracotomy under artificial res-

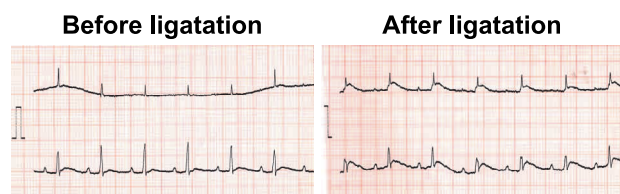


Fig. 1 Example of a limb-lead ECG before and after ligation of the left anterior descending coronary artery on thoracotomy under artificial respiration.

piration. No ST elevation was noted on the lead I and II ECG before the ligation. Myocardial ischemia-associated ST elevation was noted on the lead II ECG after the ligation. The success of the ligation of the anterior descending branch of the coronary artery was confirmed, as evidenced by ST elevation on the ECG in all rats.

The left anterior descending coronary artery was visually confirmed, and ligated using a suturing needle with thread (vascular round needle, No. 008 mm, black braid silk No. 6-0, Natsume Seisakusho, Tokyo, Japan). After ligation, ST elevation was confirmed on ECG, and 12 rats without removal of the ligation (complete ligation group; MI group) and 12 rats in which the ligation was removed for reperfusion 30 minutes after ligation (reperfusion group; R group) were prepared. For reperfusion of the coronary artery, a 0.6-mm rubber thread was placed under the ligation thread so that the ligation thread could be easily cut. The opened thorax was closed by suturing with 2.0 silk thread (alfresa, Tokyo, Japan), and the rats were maintained at the animal experiment facility of The University of Tokushima.

The present study was approved by The University of Tokushima Animal Experiment Committee, and performed in accordance with The University of Tokushima Guidelines for Animal Experiments (enforced on June 30, 1989, revised on April 15, 2005) in conformity with the Law concerning Animal Protection and Management (Law No. 105 in 1973, partially revised on December 22, 1999) and the Standards concerning Animal Maintenance and Storage for Animal Experiments (Notice from the Prime Minister's Office No. 6, March 1980, partially revised on May 28, 2002).

### 2) Grouping of animals for the administration of G-CSF and physiological saline

The MI and R groups were divided into two groups that received an intraperitoneal injection of 0.5 ml of physiological saline daily for 5 days (MI-C and R-C groups, n=6 each) and groups that received an intraperitoneal injection of recombinant G-CSF (nartograstim, Neu-up<sup>®</sup>, Kyowa Hakko Industry Ltd., Tokyo, Japan) at 100 µg/kg/day (single dose: 25 µg of G-CSF dissolved in 0.5 ml of physiological saline) daily for 5 days (MI-G and R-G groups, n=6 each). G-CSF was administered 60 min after the preparation of the myocardial infarction.

### 3) Echocardiography

For the ultrasonic instrument and probe, an Aplio

80 (Toshiba Medical Systems SSA-770A) and a 10 MHz linear transducer were used. Echocardiography was performed by the M and B modes 4 weeks after the administration of G-SCF or saline in the MI-G, MI-C, R-G, and R-C groups, and the left ventricular end-diastolic dimension (LVDD), left ventricular diameter at end systole (LVDs), interventricular septum thickness (LVST) and left ventricular posterior wall thickness (LVPWT) were calculated. These data were stored on a hard disc. For echocardiography, the minimum dose of pentobarbital (0.2 ml) was intraperitoneally injected for anesthesia. When the depth of anesthesia was insufficient, an additional 0.1 ml was administered. LVDD, the proportion of the left ventricular wall thickness ([infarct wall thickness]/[non-infarct wall thickness]), and the left ventricular ejection fraction (EF) were compared among the MI-G, MI-C, R-G, and R-C groups after 4 weeks. Echocardiography was measured under these conditions; room temperature, 20 degrees Celsius and a heart rate between 300 to 400/min.

#### 4) Histological examination

After echocardiography, the animals were sacrificed by an intraperitoneal injection of 2 ml of pentobarbital (overdose anesthesia). The heart was excised, a portion was fixed with 10% formalin, and paraffin-embedded sections were prepared. These sections were stained with hematoxylin-eosin (HE) and Azan for a histological examination. To measure the infarct area, one slice of the central part of the ventricle, was manually measured using ImageJ (Image Processing and Analysis in Java, Wayne Rasband, National Institutes of Health, USA). The infarct area ratio (%) on Azan staining were compared among the MI-G, MI-C, R-G, and R-C groups.

#### 5) Statistical analysis

The measured values are presented as the means  $\pm$  standard deviation (SD) and were analyzed using the unpaired t-test.  $P < 0.05$  was regarded as significant.

## RESULTS

### 1) Echocardiography findings

Fig. 2 shows examples of echocardiography findings for the MI-G (panel a), MI-C (panel b), R-G (panel c), and R-C (panel d) groups. In the MI-G group (panel a), the anterior wall was thinned on the

B mode, and akinetic motion was noted on the M mode. In the MI-C group (panel b), thinning of the anterior wall on the B mode was milder than that in the MI-G group, and the anterior wall motion remained hypokinetic on the M mode. In the R-G group (panel c), the thickness of the anterior wall was maintained on the B mode, and no abnormal wall motion was noted. In the R-C group (panel d), the anterior wall thickness was normal on the B mode, and the anterior wall motion was normal on the M mode.

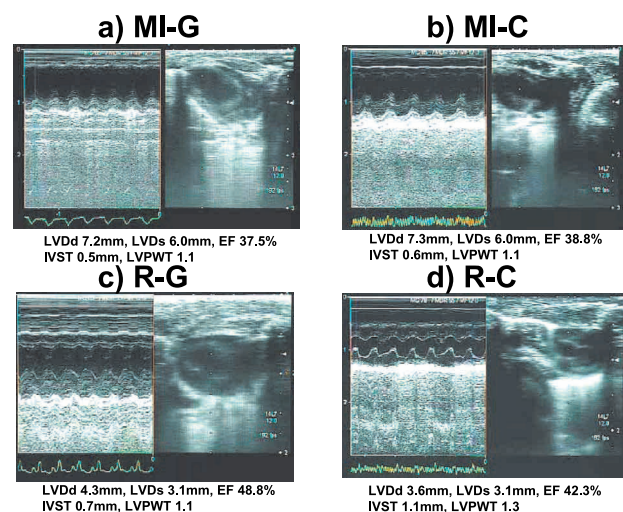


Fig. 2 Examples of echocardiography findings for the MI-G (panel a), MI-C (panel b), R-G (panel c), and R-C (panel d) groups.

LVDD, left ventricular end-diastolic dimension; LVDs, left ventricular diameter at end systole; IVST, interventricular septum thickness; LVPWT, left ventricular posterior wall thickness; EF, left ventricular ejection fraction.

Table 1 shows a comparison of the echocardiography findings among the MI-G, MI-C, R-G, and R-C groups. LVDD increased in the MI-G ( $7.1 \pm 1.4$  mm) and MI-C ( $7.1 \pm 1.1$  mm) groups, showing no significant difference between the groups. In contrast, LVDD in the R-G group ( $3.6 \pm 0.4$  mm) was significantly smaller than that in the R-C group ( $4.2 \pm 0.8$  mm).

LVDs showed a tendency similar to that for LVDD. LVDs increased in the MI-G ( $6.0 \pm 1.2$  mm) and MI-C ( $6.1 \pm 1.4$  mm) groups, showing no significant difference between the groups. In contrast, LVDs in the R-G group ( $1.4 \pm 0.4$  mm) was significantly smaller than that in the R-C group ( $2.1 \pm 0.6$  mm).

The proportion of left ventricular wall thickness (infarct wall thickness/non-infarct wall thickness) was  $0.5 \pm 0.1$  and  $0.4 \pm 0.2$  in the MI-G and MI-C groups, respectively, showing thinning of the interventricular septum, and no significant difference was

**Table 1** Comparison of the echocardiography findings among the MI-G, MI-C, R-G, and R-C groups

group	MI-G	MI-C	R-G	R-C
LVDd (mm)	7.1±1.4	7.1±1.1	3.6±0.4*	4.2±0.8
LVDs (mm)	6.0±1.2	6.1±1.4	1.4±0.4*	2.1±0.6
IVST/LVPWT	0.5±0.1	0.4±0.2	0.9±0.2*	0.7±0.4
EF(%)	38.6±10.2	35.4±8.8	64.4±12.4*	52.8±10.8

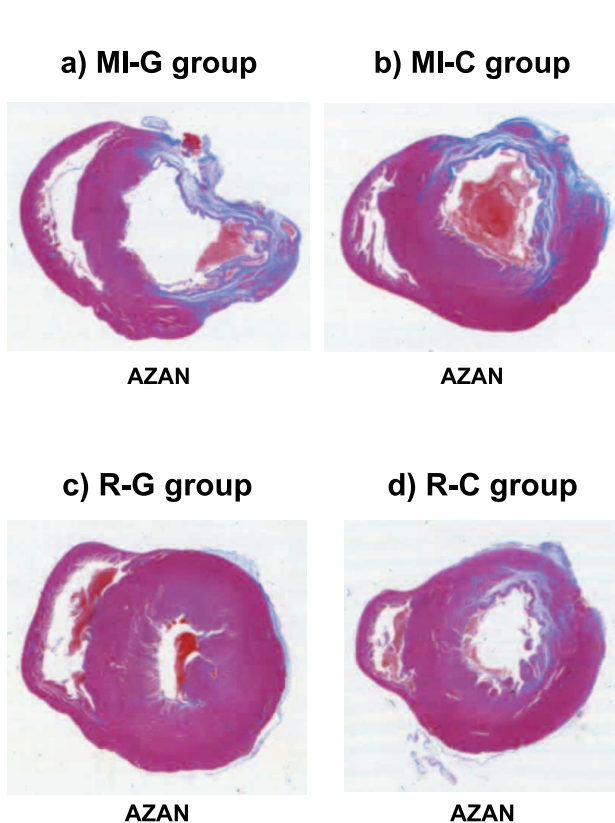
LVDd, left ventricular end-diastolic dimension ; LVDs, left ventricular diameter at end systole ; IVST, interventricular septum thickness ; LVPWT, left ventricular posterior wall thickness ; EF, left ventricular ejection fraction.  
mean ± SD, \* $p < 0.05$  vs R-C group

noted between the groups. In contrast, the proportion for the R-G group ( $0.9 \pm 0.2$ ) was significantly higher than that for the R-C group ( $0.7 \pm 0.4$ ).

EF was markedly decreased in the MI-G ( $38.6 \pm 10.2\%$ ) and MI-C ( $35.4 \pm 8.8\%$ ) groups, showing no significant difference between the groups. In contrast, sufficient EF was maintained in the R-G ( $64.4 \pm 12.4\%$ ) and R-C ( $52.8 \pm 10.8\%$ ) groups, and the EF in the R-G group was significantly higher than that in the R-C group.

## 2) Histological findings

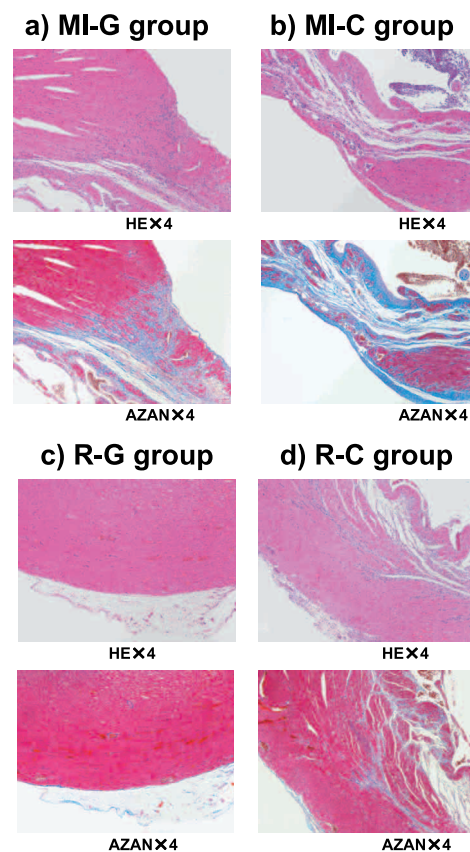
Fig. 3 shows a comparison of Azan-stained ven-



**Fig. 3** Comparison of Azan-stained ventricular cross sections among the MI-G (panel a), MI-C (panel b), R-G (panel c), and R-C (panel d) groups.

tricular cross sections among the MI-G (panel a), MI-C (panel b), R-G (panel c), and R-C (panel d) groups. In the MI-G and MI-C groups, blue-stained collagen fibers, considered to be the fibrosed region of myocardial infarction-associated necrosis, were noted. In contrast, the ventricular wall thickness was relatively maintained in the R-G and R-C groups, but collagen fibers were noted in spaces between cardiomyocytes.

Fig. 4 shows the histological findings on HE and Azan staining for the MI-G (panel a), MI-C (panel b), R-G (panel c), and R-C (panel d) groups. In the MI-C group, decreased cytoplasmic muscle fibers and the formation of many fissures between the heart muscle fibers were noted on HE staining. On Azan staining, numerous blue-stained collagen fibers were noted. In the MI-G group, the decrease in cytoplasmic muscle fibers was less than that in the MI-C group, but numerous fissures were formed between the heart muscle fibers. Azan staining showed numerous blue-stained collagen fibers, as in the MI-C group. In R-G group, the cytoplasmic muscle fibers stained red with eosin were homogeneously maintained on HE staining, and no fissure formation along cardiomyocytes was noted. No blue-



**Fig. 4** Histological findings on HE and Azan staining for the MI-G (panel a), MI-C (panel b), R-G (panel c), and R-C (panel d) groups.



stained collagen fibers were noted on Azan staining. In the R-C group, the cytoplasmic muscle fibers were stained red with eosin, numerous fissures were formed along the heart muscle fibers, and the interstitium was widely infiltrated by inflammatory cells dominated by monocytes on HE staining. Blue-stained collagen fibers were noted on Azan staining, but to a lesser degree than that noted in the MI-G and MI-C groups.

Fig. 5 shows the infarct area ratio (%). The infarct area ratio (%) was high in the MI-G ( $26.9 \pm 6.1\%$ ) and MI-C ( $25.2 \pm 6.3\%$ ) groups, showing no significant difference between the groups. In contrast, the ratio was significantly lower in the R-G group ( $2.6 \pm 1.0\%$ ) than in the R-C group ( $6.2 \pm 1.1\%$ ).

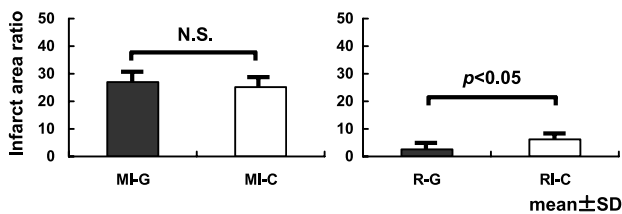


Fig. 5 Infarct area ratio (%).

## DISCUSSION

G-CSF administration did not change the infarct area ratio, left ventricular wall thickness, or left ventricular ejection fraction in rats with a complete ligation of the coronary artery, whereas G-CSF significantly reduced the infarct area ratio and left ventricular thickness and improved the left ventricular ejection fraction in rats with reperfusion of the ligation-induced infarction.

The areas of the myocardial infarction by ligation release and complete ligation are different in this animal model. Moreover, myocardial infarction is caused by different mechanisms, because the MI-C group and R-C group are coagulative necrosis and ischemia reperfusion models, respectively. The findings in the present study, therefore, suggest that G-CSF is effective for treating cardiac muscle cell disorders by ischemia reperfusion.

In recent years with the marked advances in regenerative medicine, the early clinical application of myocardial regenerative treatment would be expected to be promising for increasing myocardial contractility. Regenerative medicine for myocardial

infarctions is roughly divided into cellular treatments aimed at vascular regeneration (2-4) and myocardial regeneration in which cells are transplanted in the infarct region of the heart muscle (5, 6). As a clinical application of vascular regeneration, G-CSF administration has been reported to significantly increase collateral flow in patients with coronary arterial disease, showing a vascularization effect (7).

Various approaches for myocardial regeneration have been investigated, and studies of regenerated cardiomyocytes, pluripotent stem cells, and skeletal myoblasts using embryonic and bone marrow somatic stem cells as tools are currently underway. Myocardial sheets have been developed by tissue engineering groups (8-11). No regeneration of cardiomyocytes or arterialization in the border zone was found in this experiment and this does not prove that G-CSF does not have a regenerative effect.

The possibility of treatment with cytokines, such as G-CSF, during the acute phase of a myocardial infarction to induce the migration of stem cells to the infarct region and regeneration of the injured myocardial region has been reported (12). Orlic, *et al.* (1) reported that the concomitant administration of G-CSF and stem cell factor mobilized bone marrow cells to the infarct tissue at a high rate in a mouse acute myocardial infarction model, and that these cells regenerated cardiomyocytes and vascular endothelial cells, reducing the myocardial infarct size by 40% and the mortality rate by 68%.

Minatoguchi, *et al.* (13) reported that the administration of G-CSF alone at a dose close to the typical clinical dose after the preparation of a myocardial infarction had a therapeutic effect, in which G-CSF significantly increased cardiomyocytes, vascular endothelium, vascular smooth muscle, and myofibroblasts, which may have reduced the infarct area, inhibited cardiac remodeling, and improved cardiac function, but very few bone marrow-derived cardiomyocytes were found (13, 14), suggesting that G-CSF not only promotes myocardial regeneration by the migration of bone marrow cardiomyocytes but also directly protects existing cardiomyocytes.

Harada, *et al.* (15) also reported that G-CSF promotes survival of cardiac myocytes and prevents left ventricular remodeling after myocardial infarction through the functional communication between cardiomyocytes and noncardiomyocytes. Therefore, in this study, the mechanism of G-CSF effect for treating cardiac muscle cell disorders by ischemia reperfusion is not coronary arteries patency, but the direct action on cardiomyocytes after myocardial in-

fraction.

G-CSF is clinically used as a therapeutic drug for the treatment of leukemia and leucopenia after cancer chemotherapy. G-CSF has various actions, and the major actions are to promote the proliferation and differentiation of bone marrow precursor cells and to immobilize bone marrow stem cells. G-CSF administration promotes the induction of stem cells in the bone marrow and their release into the circulation in rats.

Since G-CSF can be readily administered, such as by subcutaneous and intravenous injection, it is less invasive for patients. In addition, fewer ethical problems are involved because it mobilizes the patient's own cells. Thus, G-CSF may become a new therapeutic strategy for treating myocardial infarctions in the near future (16). However, it has been reported that the stent re-stenosis rate increased after G-CSF administration, although it improved cardiac function after coronary arterial stenting for myocardial infarction (17).

In the present study, G-CSF was administered intraperitoneally, and a sufficient effect may be produced by intravenous administration, if the blood vessel responsible for the infarction is patent, although it cannot be directly injected into the heart muscle. Because of these possible actions, no significant differences were noted in the infarct area ratio, left ventricular wall thickness, or left ventricular ejection fraction between the MI-G and MI-C groups with a complete ligation of the coronary artery, whereas a significant reduction in the infarct area and improvement of the left ventricular wall thickness and left ventricular ejection fraction were noted in R-G and R-C groups with reperfusion. Based on these findings, G-CSF is effective for treating cardiac muscle cell disorders by ischemia reperfusion.

## REFERENCES

1. Orlic D, Kajstura J, Chimenti S, Limana F, Jakoniuk I, Quaini F, Nadal-Ginard B, Bodine DM, Leri A, Anversa P : Mobilized bone marrow cells repair the infarcted heart, improving function and survival. *Proc Natl Acad Sci USA* 98 : 10344-49, 2001
2. Takeshita S, Zheng LP, Brogi E, Kearney M, Pu LQ, Bunting S, Ferrara N, Symes JF, Isner JM : Therapeutic angiogenesis. A single intraarterial bolus of vascular endothelial growth factor augments revascularization in a rabbit ischemic hind limb model. *J Clin Invest* 93 : 662-70, 1994
3. Morishita R, Nakamura S, Hayashi S, Taniyama Y, Moriguchi A, Nagano T, Taiji M, Noguchi H, Takeshita S, Matsumoto K, Nakamura T, Higaki J, Ogihara T : Therapeutic angiogenesis induced by human recombinant hepatocyte growth factor in rabbit hind limb ischemia model as cytokine supplement therapy. *Hypertension* 33 : 1379-84, 1999
4. Losordo DW, Vale PR, Isner JM : Gene therapy for myocardial angiogenesis. *Am Heart J* 138 (2 Pt 2) : S132-41, 1999
5. Menasche P, Hagege AA, Scorsin M, Pouzet B, Desnos M, Duboc D, Schwartz K, Vilquin JT, Marolleau JP : Myoblast transplantation for heart failure. *Lancet* 357 : 279-80, 2001
6. Kamihata H, Matsubara H, Nishiue T, Fujiyama S, Tsutsumi Y, Ozono R, Masaki H, Mori Y, Iba O, Tateishi E, Kosaki A, Shintani S, Murohara T, Imaizumi T, Iwasaka T : Implantation of bone marrow mononuclear cells into ischemic myocardium enhances collateral perfusion and regional function via side supply of angioblasts, angiogenic ligands, and cytokines. *Circulation* 104 : 1046-52, 2001
7. Seiler C, Pohl T, Wustmann K, Hutter D, Nicolet PA, Windecker S, Eberli FR, Meier B : Promotion of collateral growth by granulocyte-macrophage colony-stimulating factor in patients with coronary artery disease : a randomized, double-blind, placebo-controlled study. *Circulation* 104 : 2012-7, 2001
8. Badylak SF, Kochupura PV, Cohen IS, Doronin SV, Saltman AE, Gilbert TW, Kelly DJ, Ignatz RA, Gaudette GR : The use of extracellular matrix as an inductive scaffold for the partial replacement of functional myocardium. *Cell Transplant* 15(Suppl 1) : S29-40, 2006
9. Miyahara Y, Nagaya N, Kataoka M, Yanagawa B, Tanaka K, Hao H, Ishino K, Ishida H, Shimizu T, Kangawa K, Sano S, Okano T, Kitamura S, Mori H : Monolayered mesenchymal stem cells repair scarred myocardium after myocardial infarction. *Nat Med* 12 : 459-65, 2006
10. Miyagawa S, Sawa Y, Sakakida S, Taketani S, Kondoh H, Memon IA, Imanishi Y, Shimizu T, Okano T, Matsuda H : Tissue cardiomyoplasty using bioengineered contractile cardiomyocyte sheets to repair damaged myocardium : their integration with recipient myocardium. *Transplantation* 80 : 1586-95, 2005
11. Menasche P, Hagege AA, Scorsin M, Pouzet

- B, Desnos M, Duboc D, Schwartz K, Vilquin JT, Marolleau JP : Myoblast transplantation for heart failure. *Lancet* 357 : 279-80, 2001
12. Lim SY, Kim YS, Ahn Y, Jeong MH, Rok LS, Kim JH, Kim KH, Park HW, Kim W, Cho JG, Park JC, Kang PM, Schwartz RS, Kang JC : The effects of granulocyte-colony stimulating factor in bare stent and sirolimus-eluting stent in pigs following myocardial infarction. *Int J Cardiol* 2006 ; [Epub ahead of print]
  13. Minatoguchi S, Takemura G, Chen XH, Wang N, Arai M, Misao Y, Lu C, Uno Y, Koda M, Goto K, Takahashi T, Kosai K : Myocardial infarction itself induces cardiomyocyte regeneration from bone marrow cells, and post-ischemic G-CSF treatment improves cardiac dysfunction via acceleration of the process. *Circulation* 106(suppl II) : II-132, 2002
  14. Minatoguchi S, Takemura G, Chen XH, Wang N, Uno Y, Koda M, Arai M, Misao Y, Lu C, Koji S, Goto K, Komada A, Takahashi T, Kosai K, Fujiwara T, Fujiwara H : Acceleration of the healing process and myocardial regeneration may be important as a mechanism of improvement of cardiac function and remodeling by postinfarction granulocyte colony-stimulating factor treatment. *Circulation* 109 : 2572-80, 2004
  15. Harada M, Qin Y, Takano H, Minamino T, Zou Y, Toko H, Ohtsuka M, Matsuura K, Sano M, Nishi J, Iwanaga K, Akazawa H, Kunieda T, Zhu W, Hasegawa H, Kunisada K, Nagai T, Nakaya H, Yamauchi-Takahara K, Komuro I : G-CSF prevents cardiac remodeling after myocardial infarction by activating the Jak-Stat pathway in cardiomyocytes. *Nat Med* 11 : 305-311, 2005
  16. Takano H, Ohtsuka M, Akazawa H, Toko H, Harada M, Hasegawa H, Nagai T, Komuro I : Pleiotropic effects of cytokines on acute myocardial infarction : G-CSF as a novel therapy for acute myocardial infarction. *Curr Pharm Des* 9 : 1121-7, 2003
  17. Kang HJ, Kim HS, Zhang SY, Park KW, Cho HJ, Koo BK, Kim YJ, Soo Lee D, Sohn DW, Han KS, Oh BH, Lee MM, Park YB : Effects of intracoronary infusion of peripheral blood stem-cells mobilised with granulocyte-colony stimulating factor on left ventricular systolic function and restenosis after coronary stenting in myocardial infarction : the MAGIC cell randomised clinical trial. *Lancet* 363 : 751-6, 2004