

CASE REPORT

A successful transatrial repair in redo surgery of postinfarction inferoposterior ventricular septal rupture

Takashi Tominaga, Hirotsugu Kurobe, Tamotsu Kanbara, Takeyuki Kanemura, Takashi Kitaichi, and Tetsuya Kitagawa

Department of Cardiovascular Surgery, Institute of Health Biosciences, The University of Tokushima Graduate School, Tokushima, Japan

Abstract : A successful transatrial repair in redo surgery of postinfarction posterior ventricular septal rupture (VSR) was performed after an infarct exclusion technique through left ventriculotomy incision of the infarcted area. For the infarct lesion, this approach provides excellent results with sufficient closure of the VSR and prevention of the ventricular remodeling for five years. A right atrial approach for postinfarction posterior VSR is very useful for avoiding any further ventriculotomy in an already impaired ventricle, securing a stable suture, and preserving the left ventricular geometry and function. *J. Med. Invest.* 54 : 184-186, February, 2007

Keyword : *postinfarction cardiac complications, reoperation, rupture*

INTRODUCTION

The goal of surgical management for postinfarction ventricular septal rupture (VSR) is not only to eliminate the left-to-right shunt but also to prevent ventricular remodeling and aneurysm formation. The myocardial infarction exclusion technique proposed by David and colleagues seems to have several theoretical advantages to the goal (1). Therefore, we have favored this repair technique for postinfarction VSR because of the advantages as well as the technical simplicity through left ventriculotomy of the infarct area. In our current infarction exclusion technique, a single heterogeneous pericardial patch is tailored and sutured to the intact ventricular muscle or fibrous annulus of the mitral valve (MV) around VSR doubly with 4-0 monofilaments thread without an intraventricular tie. However, this repair technique for posterior VSR occurring after

inferior myocardial infarction still remains having poor outcomes due to left ventricular access, mitral valve dysfunction, and dehiscence of closing stitches. We herein report a case who underwent a successful transatrial repair for problematic residual VSR after an early repair of infarct exclusion technique through the left ventriculotomy for posterior VSR.

PRESENTATION OF CASE

A 77-year-old man with cardiogenic shock caused by postinfarction VSR was transferred to our hospital. Echocardiography revealed extensive inferoposterior myocardial infarction and VSR with massive shunt. Coronary arteriography demonstrated 90% stenosis of the proximal left anterior descending artery and total occlusion of the right coronary artery. Pulmonary-to-systemic blood flow ratio (Q_p/Q_s) of 4.3 and pulmonary artery pressure of 64/17 mmHg were revealed. As serious heart failure developed, deteriorating despite intensive treatment, emergent operation with infarct exclusion technique was scheduled. A longitudinal incision parallel to the posterior descending artery was made in

Received for publication November 6, 2006 ; accepted December 15, 2006.

Address correspondence and reprint requests to Takashi Tominaga, Department of Cardiac Surgery, Kagawa National Children's Hospital, 2603, Zentsuji-cho, Zentsuji, Kagawa 765-8501, Japan and Fax : +81-877-62-5384.

the infarcted left inferior ventricle wall. The VSR extended widely from the posterior basal septum nearby the MV to the base of the posteromedial papillary muscles and to the apex of the septum. A heterogeneous pericardial patch tailored in a triangular shape was sutured with a continuous monofilament starting at the base of the posteromedial papillary muscles, and moving to noninfarcted endocardium nearby the fibrous annulus of the MV and to the anterolateral and inferior free wall of the left ventricle so as to exclude the infarcted lesion. Then, a coronary artery bypass grafting to the left anterior descending artery using a saphenous vein was performed. Weaning from the cardiopulmonary bypass was easy.

Echocardiography revealed residual shunt (Q_p/Q_s of 2.8) in the inferoposterior septum five days after operation. A second surgery was done on the 16th postoperative day. Re-ventriculotomy was too risky due to severe adhesions around the patent graft and the previous left ventriculotomy with felt strips, therefore, the residual VSR was tried to close through a right atrial approach. A right atriotomy was made, and to identify the margin of the VSR accurately, the left ventricle was filled with crystalloid cardioplegic solution by inducing temporary aortic valve incompetence through the ascending aorta. The endocardial patch could not be observed, which was previously placed to the left side of the ventricular septum through the right atrial approach. As compared to the left side aspect of the VSR lesion in the first operation with the right side aspect of that in the second operation, the former showed a large necrotic area, while the latter seemed to appear less compromised with the necrotic tissue limited barely at the inferoposterior septum. A new heterogeneous pericardial patch was sutured to the viable myocardium as far away from the rim of the VSR as possible with interrupted everting mattress sutures. Filling the left ventricle with crystalloid cardioplegic solution acknowledged the complete closure of the VSR.

Nevertheless, echocardiography showed residual shunt through the inferoposterior septum nearby the new patch, and Q_p/Q_s reached a peak of 2.5 on the 7th postoperative day. The third operation was done through the same atrial approach on the 23rd postoperative day after the first operation. The inferoposterior part of the patch was detached from the septum. This part of the patch was sutured to the inferoposterior wall using full-thickness bites and anchored the suture on felt strip applied on

the epicardial surface of inferoposterior free wall of the right ventricle (Fig. A, B). After this operation, the hemodynamics became stable and the pulmonary congestion improved on chest X-ray. The patient was discharged on the 75th day after the first operation.

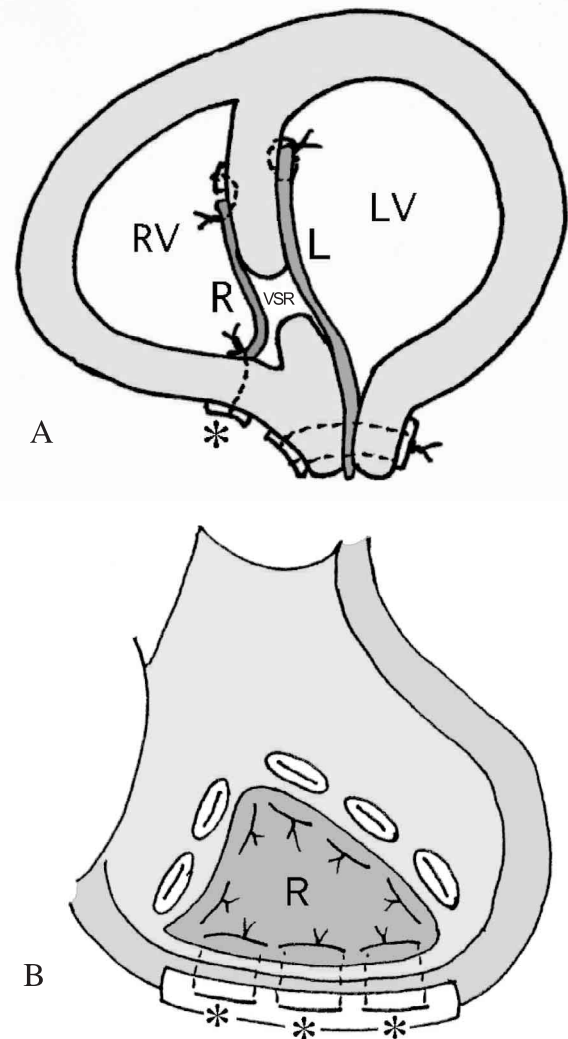


Fig. The repaired postinfarction ventricular septal rupture as seen through the short axis view (A) and through the right atriotomy (B). * : Full-thickness bites and anchoring suture on a felt strip is recommended. L=left side patch ; R=right side patch ; VSR=ventricular septal rupture ; RV=right ventricle ; LV=left ventricle.

DISCUSSION

The purpose of the present report is to show an alternative operative technique "a right atrial approach" for the treatment of the VSR. Especially in redo operation of VSR, this procedure allows avoidance of a problematic dissection with difficult access to the ventricular chamber and a further ven-

triculotomy in an already compromised ventricle.

Large postinfarction inferoposterior VSR involves extensive septum around the MV and posteromedial papillary muscle, and the margins of the defect may concern the inferior aspects of both ventricles, or of the left ventricle only. Although an extensive myocardial exclusion technique is commonly performed first for the patient with large postinfarction inferoposterior VSR like this case, it might occasionally result in the recurrence of VSR due to the sutures tearing out of the myocardium caused by its geometric complexity and undue tension. In this case, the posterior basal part of the ventricular septum was so friable beyond our expectation, and retrospectively speaking, the patch should be sutured to the sturdier endocardium involving the mitral annulus.

Recently others have reported that a posterior VSR could be repaired successfully through a right atrial approach in primary and redo cases with the advantage of less ventricular compromise (2-5). As the present case was very old and his general status had worsened after the first infarct exclusion, it was necessary not to expose him to excessive invasiveness in repairing the residual VSR. Also, there was a technical obstacle of difficult dissection with uneasy access to the previous left ventriculotomy, which was complicated by a patent coronary artery bypass graft. The VSR was mainly located on the posterior septum, and a good surgical view was expected by retraction of the tricuspid valve through a transatrial approach because of smooth septum with relatively few trabeculations.

The better indication of transatrial approach is a case with a large posterior infarction in which a transventricular approach may lead to increased operative complications (e.g., low cardiac output), and when a significant residual shunt after the infarct exclusion for the VSR through left ventriculotomy of infarcted area is present. Another indication is the case when the infarct is primarily of the posterior septum without the ventricular free wall.

Concerning suture technique to reinforce the thin inferoposterior rim of the VSR from the right side of the septum, suturing patch to the inferoposte-

rior wall of the right ventricle by going through the posterior free wall to the epicardial surface with anchoring on a felt strip was extremely useful to provide the suture integrity.

For the infarct lesion of the present case, a transatrial approach provides excellent results with sufficient closure of the VSR and prevention of the ventricular remodeling for five years after the last operation.

In conclusion, a right atrial approach for postinfarction inferoposterior VSR is very useful for avoiding any further ventriculotomy in an already impaired ventricle, securing a stable suture, and preserving the left ventricular geometry and function. Although the significant difference of late results between a right atrial approach and a left ventriculotomy approach for postinfarction VSR are uncertain, further follow-up and prudent evaluations of a large number of cases relevant to ventricular function and remodeling will elucidate the role and validity of this approach.

REFERENCES

1. David TE, Dale L, Sun Z : Postinfarction ventricular septal rupture : repair by endocardial patch with infarct exclusion. *J Thorac Cardiovasc Surg* 110 : 1315-1322, 1995
2. Frassani R, Gelsomino S : A right atrial approach in redo postinfarction ventricular septal defect. *Cardiovasc Surg* 7 : 656-658, 1999
3. Chan BB, Nolan SP, Kron IL : Transatrial approach to posterior postinfarct ventricular septal defects. *Ann Thorac Surg* 62 : 903-904, 1996
4. Rousou JA, Engelman RM, Breyer RH, Whittredge P, Schnider R : Transatrial repair of postinfarction posterior ventricular septal defect. *Ann Thorac Surg* 43 : 665-666, 1987
5. Massetti M, Babatasi G, Le Page O, Bhoyroo S, Saloux E, Khayat A : Postinfarction ventricular septal rupture : early repair through the right atrial approach. *J Thorac Cardiovasc Surg* 119 : 784-789, 2000