

A case of sarcoidosis associated with chronic eosinophilic pneumonia

Kenji Tani*, Makoto Kashio*, Nobuya Sano[†], Yoichi Nakamura*, Fumitaka Ogushi*, and Saburo Sone*

Third Department of Internal Medicine; and [†]Second Department of Pathology, The University of Tokushima School of Medicine, Tokushima, Japan

Abstract: A 38-year-old man was hospitalized in our university hospital because of pulmonary opacities with bilateral hilar and mediastinal lymphadenopathy seen on chest radiograph. Eosinophilia was observed in the circulation and bronchoalveolar lavage (BAL) fluid. Histological examination revealed noncaseating epithelioid granulomas and eosinophilic infiltration in the lung. Based on these findings, a diagnosis of sarcoidosis combined with chronic eosinophilic pneumonia was made. The infiltrates on chest radiograph and BAL eosinophilia were promptly reduced with corticosteroid therapy, but only mild reduction was observed in diffuse nodular shadows and hilar and mediastinal lymphadenopathy, and high amounts of lymphocytes in BAL fluid remained. Increased IFN- γ , IL-4 and IL-5 were detected in the BAL fluid, and corticosteroid therapy reduced IL-4 and IL-5 (Th-2 cytokines) but not IFN- γ (Th-1 cytokine). These cytokine levels in BAL fluid were intimately correlated with the clinical course of sarcoidosis and chronic eosinophilic pneumonia. *J. Med. Invest.* 45 : 131-136, 1998

Key words : *sarcoidosis, chronic eosinophilic pneumonia, cytokine, bronchoalveolar lavage*

INTRODUCTION

CD4+ lymphocytes can be subdivided into two distinct populations, Th1 and Th2, defined by the spectrum of cytokines produced by these cells in mice (1, 2) and humans (3). Th1 cells generate interleukin (IL)-2, interferon (IFN)- γ , and promote cellular immunity, whereas Th2 generate IL-4, IL-5, IL-6, and IL-10, and play a role in humoral responses and allergic diseases (4, 5). There is evidence that a balance of different cytokine producers is crucial for an effective immune response and the outcome of infectious, autoimmune, and allergic diseases (6, 7).

In granulomatous diseases including sarcoidosis, there is evidence for a predominant Th1 response. Indeed, lung lymphocytes from sarcoidosis patients produce excessive amounts of IFN- γ and IL-2 (8-11). However, in eosinophilic pneumonia, eosinophils

which are known to grow and be activated in the presence of Th2 cytokines are accumulated and activated in the lungs. Both Th1 and Th2 lymphocytes have been suggested to be responsible for the pathogenesis of this disorder (12, 13). Here, we report a patient with sarcoidosis associated with chronic eosinophilic pneumonia (CEP) along with a brief review of relevant literature.

CASE REPORT

A 38-yr-old man had complained of productive cough since August, 1996. A chest radiograph which was taken for a health check on July 4, 1997, revealed diffuse pulmonary opacities with bil hilar lymphadenopathy. He was admitted to Tokushima University Hospital on Dec. 18, 1997 for further examinations. He denied using any prescription medications, and there was no history of allergic diseases including bronchial asthma.

On admission, a physical examination revealed swelling of several lymph nodes in right (rt) cervical

Received for publication July 6, 1998 ; accepted July 29, 1998.

[†] Address correspondence and reprint requests to Kenji Tani, M.D., Ph.D., Third Department of Internal Medicine, The University of Tokushima School of Medicine, Kuramoto-cho, Tokushima 770-8503, Japan and Fax : +81-886-33-2134 .

and bil axillar regions. Leukocyte count, 5100 per μl with 13.0% of eosinophils. Erythrocyte sedimentation rate was within the normal range (2 mm/h), and serum C-reactive protein was slightly elevated (0.39 mg/dl; normal, <0.3). Slightly increased serum angiotensin-converting enzyme (ACE) (29.6 U/L; normal, 7.7-29.4) and lysozyme (17.6 $\mu\text{g/ml}$; normal, 4.2-11.5) were observed. Arterial blood gas analysis revealed mild hypoxemia (PaO_2 63.8 mmHg) with normal PaCO_2 level. Pulmonary function test revealed decreased $\text{FEV}_{1.0\%}$ (55.1%) and %DLco (57.7%). Chest radiograph and computed tomographic (CT) scan showed hilar and mediastinal lymphadenopathy, bil diffuse nodularity, and infiltrates with rt lobe predominance (Figure 1a). ^{67}Ga -citrate scintigraphy showed abnormal accumulations in bil supraclavicular regions, parotis, hilar regions, and rt lung. Ophthalmological examination revealed mild uveitis.

Bronchoscopy with bronchoalveolar lavage (BAL) and transbronchial lung biopsies (TBLB) was performed on Dec. 18, 1997. The BAL was performed in the segment of rt B5b with a total volume of 150 ml of sterile 0.9% saline in three 50-ml portions (Table 1).

Table 1. Bronchoalveolar lavage data

	Dec 18, 1997	Feb 25, 1998
BAL bronchus	rt B5b	rt B5b
Recovery rate (%)	88	67
Total cells, $\times 10^6$	55.0	21.0
AM, $\times 10^6$ (%)	6.7 (12.1)	2.1 (10.2)
Lymphocytes, $\times 10^6$ (%)	26.9 (48.9)	18.3 (87.1)
Neutrophils, $\times 10^6$ (%)	1.3 (2.3)	0.1 (0.7)
Eosinophils, $\times 10^6$ (%)	20.2 (36.8)	0.4 (2.0)
CD4/CD8	1.0	0.7

AM ; alveolar macrophages

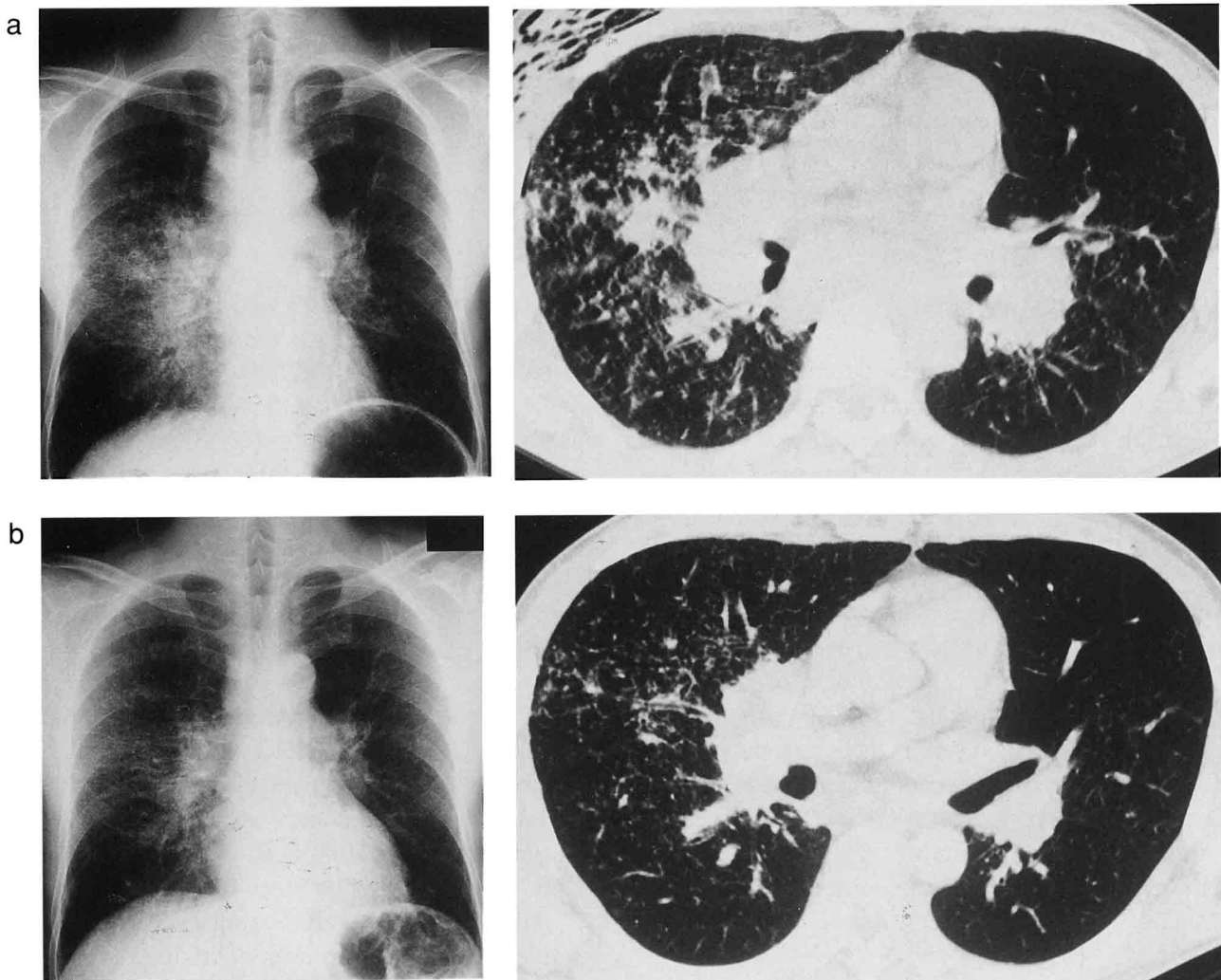


Fig.1. a) A chest radiograph (lt) and chest CT scan (rt) at the time of admission. Hilar and mediastinal lymphadenopathy, bil diffuse nodularity, and infiltrates with rt lobe predominance are seen.
b) A chest radiograph (lt) and chest CT scan (rt) after therapy with corticosteroid. A significant reduction is seen in the infiltrates, but only mild reduction is observed in diffuse nodular shadows and hilar and mediastinal lymphadenopathy.

The number of total cells was, 5.5×10^7 and the cell differential revealed increased percentages of lymphocytes and eosinophils. The ratio of CD4 to CD8 was 1.0. Histological examination for TBLB specimen revealed noncaseating epithelioid granulomas and eosinophilic infiltration (Figure 2). Findings of special stains for acid fast, fungal, and parasitic microorganisms were negative.

Based on these findings, a diagnosis of sarcoidosis combined with CEP was made. Therapy was initiated with prednisolone, 30 mg per day, from January 13, 1998, and maintained for a week. Then, 2.5mg of prednisolone dosage was reduced every two weeks. The clinical course is summarized in Figure 3. Cough symptoms rapidly decreased following the treatment, and the opacities in the peripheral infiltrates on chest radiograph were also promptly reduced. The swelling of lymph nodes observed in the rt cervical and bil axillar regions gradually decreased. The number of peripheral eosinophils and serum ACE level were reduced. PaO₂ and FEV_{1.0%} were improved. The BAL, which was performed on Day 42 after corticosteroid therapy had begun, showed a significantly decreased percentage of eosinophils but the high percentage of lymphocytes remained (Table 1). Follow-up chest radiograph and CT scan showed that the infiltrates with rt lobe predominance were significantly decreased, but only mild reduction was observed in hilar and mediastinal lymphadenopathy and diffuse nodular shadows (Figure 1b).

IFN- γ , IL-2, IL-4 and IL-5 in BAL fluid were measured using ELISA as previously described (14) (Table 2). IFN- γ , IL-4, and IL-5 were detected in the BAL fluid obtained before the corticosteroid therapy. After the therapy, IL-4 or IL-5 was not detectable (the detection limit was 20 pg/ml), but IFN- γ was detected at the a

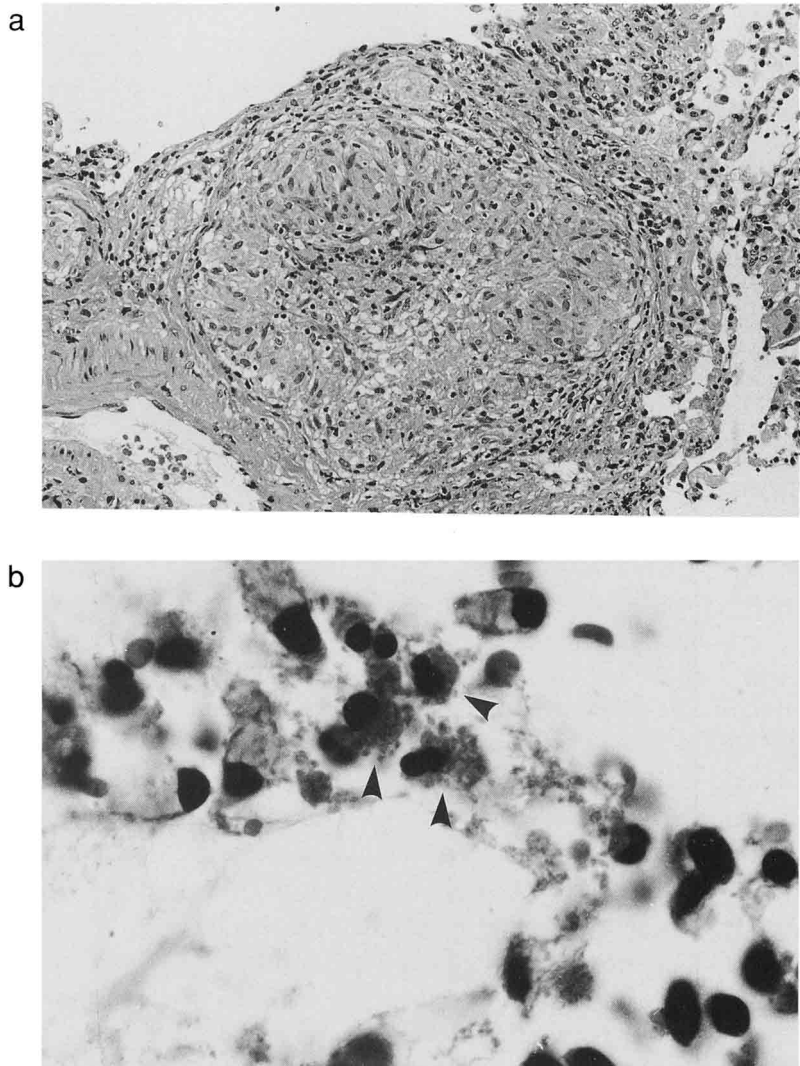


Fig.2. a) A small noncaseating epithelioid granuloma surrounded by mild lymphocytic infiltration (H.E., 66 x).
b) Eosinophilic infiltration (arrow heads) observed in bronchial epithelium (H.E., 250 x).

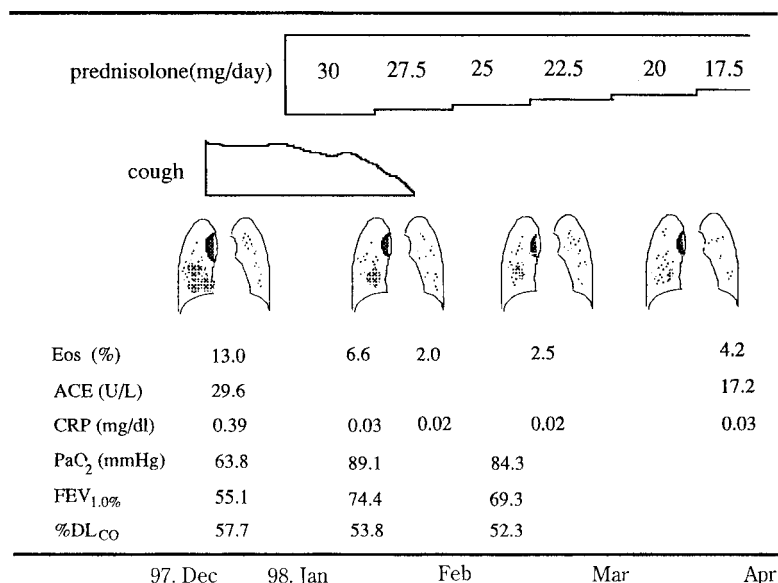


Fig.3. Summary of clinical course

Table 2. Cytokines in bronchoalveolar lavage fluid

Cytokines	Corticosteroid therapy	
	Before	After
interferon- γ	28 ^a	27
interleukin-4	49	<20
interleukin-5	179	<20

^aData are expressed as pg/ml

similar level as observed before therapy. No IL-2 was detected during the course.

DISCUSSION

Our patient had clinical, roentgenographic and immunological features of sarcoidosis associated with CEP. Chest radiograph and CT scan revealed hilar and mediastinal lymphadenopathy and bilateral diffuse nodularity. Lung lesions were histologically confirmed to be noncaseating epithelioid granulomas. Ophthalmological examination disclosed uveitis. Serum ACE and lysozyme levels were elevated. These findings were consistent with a diagnosis of sarcoidosis. However, in our patient the infiltrates showed right lobe predominance on chest radiograph and CT. Moreover, both lymphocytes and eosinophils were increased in the BAL fluid, and eosinophilic infiltration was histologically observed in the TBLB specimen of the lung. From these findings, the disease diagnosed was sarcoidosis associated with CEP.

Davis *et al.* showed that over 5% of BAL eosinophils were observed in 7% of patients with sarcoidosis (15). Allen *et al.* also reported that 6% of patients with sarcoidosis were found to have BAL eosinophilia, but all had relatively modest percentages (less than 8%) of eosinophils (16), indicating that BAL differentials from patients with sarcoidosis rarely include significant numbers of eosinophils. We know of only one report which showed a case diagnosed as CEP concomitant with sarcoidosis; the case had a prominently increased percentage (94.2%) of BAL eosinophils (17).

Corticosteroid therapy rapidly reduced peripheral pulmonary infiltrates with right lobe predominance on chest radiograph and the BAL eosinophil percentage. However, diffuse nodularity and hilar and mediastinal lymphadenopathy on chest radio-

graph and the BAL lymphocyte percentages did not respond well to the therapy. The early response of pulmonary sarcoidosis to corticosteroid has been known to be poorer when compared with that of CEP (18, 19). Therefore, the clinical course in our patient indicated that corticosteroid therapy predominantly reduced lung lesions caused by CEP, and the lesions which did not respond to the therapy might indicate a diagnosis of sarcoidosis.

In this case, increased IFN- γ , IL-4 and IL-5 were detected in the BAL fluid. Corticosteroid therapy reduced IL-4 and IL-5 to undetectable concentrations but not IFN- γ . The activation of Th1-type lymphocytes is known to have an important role in the development of sarcoidosis (20). IFN- γ is suggested to be important in the activation of macrophages, resulting in processing inflammatory cell accumulation, granuloma formation, and fibrogenesis (21, 22). Indeed, in the BAL fluid of active sarcoidosis, only Th1 cytokines can be found, but Th2 cytokines such as IL-4 and IL-5 cannot be detected (12, 20, 23). However, CEP is characterized by the accumulation of eosinophils in the alveolar spaces and the interstitium of the lung. In the BAL fluid from patients with CEP, IL-2, IFN- γ (Th1 cytokine) and IL-5 (Th2 cytokine) can be detected, indicating that both Th1 and Th2 cells may be responsible for the pathogenesis of this disorder (12, 13). IL-5, a cytokine known to induce eosinophil proliferation, differentiation and activation, is important in eosinophilia *in vivo* (24, 25). IL-4 is known to be the master cytokine of the Th2-type immune response (2), and can stimulate eosinophil transmigration to the airway mucosa by enhancing the expression of vascular cell adhesion molecule 1 (25) and the release of eosinophil-survival stimulating activity from bronchial epithelial cells (27). In this case, IL-4 and IL-5 were elevated in the BALF, but neither was detectable after the corticosteroid treatment, correlated with the clinical course of CEP, indicating that the Th2-related cytokines might be responsible for eosinophil infiltration into the lungs.

In this case, radiographical lesions of pulmonary sarcoidosis and IFN- γ levels in the BAL fluid did not respond well to corticosteroid therapy, but serum ACE levels were reduced by the therapy. Serum ACE level is higher in clinically active than in inactive disease. Since ACE is known to be produced by epithelioid cells of granulomas (28), serum ACE reflects the total-body granuloma burden and not just the degree of lung involvement (29, 30). From these observations, corticosteroid therapy

might partially improve granulomatous lesions due to sarcoidosis except in lungs.

ACKNOWLEDGMENTS

We thank Dr. Ohmoto (Otsuka Pharmaceutical Co., Tokushima, Japan) for help with the assay of cytokines.

REFERENCES

1. Fiorentino DF, Bond MW, Mosmann TR: Two types of mouse T helper cell. *J Exp Med* 179 : 2081-2095, 1989
2. Mosmann TR, Coffman RL: Th1 and Th2 cells: different patterns of lymphokine secretion lead to different functional properties. *Annu Rev Immunol* 7 : 145-173, 1989
3. Romagnani S: Human Th1 and Th2 subsets: doubt no more. *Annu Rev Immunol* 12 : 256-257, 1991
4. Romagnani S: Lymphokine production by human T cells in disease states. *Annu Rev Immunol* 12 : 227-257, 1994
5. King CL, Stupi RJ, Craighead N, June CH, Thyphronitis G: CD28 activation promotes Th2 subset differentiation by human CD4+ T cells. *Eur J Immunol* 25 : 587-595, 1995
6. Elias JA, Freundlich B, Kern JA, Rosenbloom J: Cytokine networks in the regulation of inflammation and fibrosis in the lung. *Chest* 97 : 1439-1445, 1990
7. Surcel HM, Troye-Blomberg M, Paulie S, Andersson G, Moreno C, Pasvol G: Th1/Th2 profiles in tuberculosis, based on the proliferation and cytokine response of blood lymphocytes to mycobacterial antigens. *Immunology* 81 : 171-176, 1994
8. Moseley PL, Hemken C, Monick M, Nugent K, Hunninghake GW: Interferon and growth factor activity for human lung fibroblasts. *Chest* 89 : 657-662, 1986
9. Robinson BWS, McLemore TL, Crystal RG: Gamma-interferon is spontaneously released by alveolar macrophages and lung T-lymphocytes in patients with pulmonary fibrosis. *J Clin Invest* 75 : 1488-1495, 1985
10. Pinkston P, Bitterman PB, Crystal RG: Spontaneous release of interleukin-2 by lung T-lymphocytes in patients with pulmonary sarcoidosis. *N Engl J Med* 308 : 793-800, 1993
11. Hoshino TK, Itoh R, Gouhara A, Yamada Y, Tanaka Y, Ichikawa M, Azuma M, Mochizuki M, Villiger B: Spontaneous production of various cytokines except IL-4 from CD4+ T cells in the affected organs of sarcoidosis patients. *Clin Exp Immunol* 102 : 399-405, 1994
12. Walker C, Bauer W, Braun RK, Menz G, Braun P, Schwarz F, Hansel TT, Villiger B: Activated T cells and cytokines in bronchoalveolar lavages from various lung diseases associated with eosinophilia. *Am J Respir Crit Care Med* 150 : 1038-1048, 1994
13. Pesci A, Bertorilli G, Manganelli P, Mori PA, Strinati F, Marangio E, Olivieri D: Bronchoalveolar lavage in chronic eosinophilic pneumonia: Analysis of six cases in comparison with other interstitial lung diseases. *Respiration* 54 : 16-22, 1988
14. Sone S, Yanagawa H, Nishioka Y, Orino E, Nii A, Ogura T: Interleukin-4 as a potent down-regulator for human alveolar macrophages capable of producing tumor necrosis factor-alpha and interleukin-1. *Eur Respir J* 5 : 174-181, 1992
15. Davis WB, Fells GA, Sun XH, Gadek JE, Vene A, Crystal RG: Eosinophil-mediated injury to lung parenchymal cells and interstitial matrix: A possible role for eosinophils in chronic inflammatory disorders of the lower respiratory tract. *J Clin Invest* 74 : 269-277, 1984
16. Allen JN, Davis WB, Pacht ER: Diagnostic significance of increased bronchoalveolar lavage fluid eosinophils. *Am Rev Respir Dis* 142 : 642-647, 1990
17. Shijubo N, Fujisawa T, Morita S, Nakata H, Satoh M, Uno E, Morikawa T, Abe S: Idiopathic chronic eosinophilic pneumonia associated with noncaseating epithelioid granulomas. *Eur Respir J* 8 : 327-330, 1995
18. Sharma OP: Pulmonary sarcoidosis and corticosteroids. *Am Rev Respir Dis* 147 : 1598-1600, 1993
19. Naughton M, Fahy J, Fitzgerald MX: Chronic eosinophilic pneumonia: A long-term follow-up of 12 patients. *Chest* 103 : 162-165, 1993
20. Baumer I, Zissel G, Schlaak M, Muller-Quernheim J: Th1/Th2 cell distribution in pulmonary sarcoidosis. *Am J Respir Cell Mol Biol* 16 : 171-177, 1997
21. Spiteri MA, Poulter LW, James DG: The macrophage in sarcoid granuloma formation.

- Sarcoidosis 6 : 12-14, 1989
22. Thomas PD, Hunninghake GW : Current concepts of the pathogenesis of sarcoidosis. *Am Rev Respir Dis* 135 : 747-760, 1987
 23. Garlepp MJ, Rose AH, Dench JE, Robinson BW : Clonal analysis of lung and blood T cells in patients with sarcoidosis. *Thorax* 49 : 577-585, 1994
 24. Lope AF, Sanderson CJ, Gamble JR, Cambell HR, Young NS, Vadas MA : Recombinant human interleukin-5 is a selective activator of human eosinophil function. *J Exp Med* 167 : 219-224, 1988
 25. Clutterbuck E J, Hirst EMA, Sanderson CJ : Human interleukin-5 (IL-5) regulates the production of eosinophils in human bone marrow cultures : Comparison and interactions with IL-1, IL-3, IL-6, and GM-CSF. *Blood* 74 : 1504-1512, 1989
 26. Weller PF, Rand TH, Goelz SE, Chi-Rosso GC, Lobb RR : Human eosinophil adherence to vascular endothelium mediated by binding to vascular cell adhesion molecule-1 and endothelial leukocyte adhesion molecule 1. *Proc Natl Acad Sci USA* 88 : 7430-7433, 1991
 27. Nakamura Y, Azuma M, Okano Y, Sano T, Takahashi T, Ohmoto Y, Sone S : Upregulatory effects of interleukin-4 and interleukin-13 but not interleukin-10 on granulocyte/macrophage colony stimulating factor production by human bronchial cells. *Am J Respir Cell Mol Biol* 15 : 680-687, 1996
 28. Gupta RG, Oparil S, Szidon JP : Clinical significance of serum angiotensin-converting enzyme levels in sarcoidosis. *J Lab Clin Med* 93 : 940-949, 1979
 29. Baughman RP, Fernandez M, Bosken CH, Mantil J, Hurtubise P : Comparison of gallium-67 scanning, bronchoalveolar lavage, and serum ACE levels in pulmonary sarcoidosis 129 : 676-681, 1984
 30. Turner-Warwick M, McAllister W, Lawrence R, Britten A, Haslam PL : Corticosteroid treatment in sarcoidosis : Do serial lavage lymphocyte counts, serum ACE measurements and gallium-67 scans help management ? *Thorax* 41 : 903-913, 1986