

CASE REPORT

Retrosternal salvage reconstruction of esophageal discontinuity for a necrotic gastric tube after esophagectomy : A novel procedure

Tetsuya Abe^{1,2}, Masahide Fukaya², and Masato Nagino²

¹Department of Gastroenterological Surgery, Aichi Cancer Center Hospital, Aichi, Japan

²Division of Surgical Oncology, Department of Surgery, Nagoya University Graduate School of Medicine, Aichi, Japan

Abstract : In patients with esophageal cancer, esophageal conduit necrosis is a catastrophic complication of esophagectomy that requires surgical restoration. Because such patients are generally fatigued, less-invasive surgery is encouraged whenever possible. Therefore, we trim the sternum minimally above the healthy part of the gastric conduit, expose its surface, and then make anastomoses between the remnant esophagus and the exposed gastric conduit using a free jejunal graft through a retrosternal-subcutaneous route. The risk involved with this procedure is low, because we avoid manipulation of the heavily inflamed lesion due to mediastinitis. *J. Med. Invest.* 65 : 296-298, August, 2018

Keywords : Esophageal cancer, Reoperation, Microvascular surgery

INTRODUCTION

Necrosis of an esophageal conduit is a dreaded complication of esophagectomy in patients with esophageal cancer. It is a life-threatening situation and requires a long recovery period. A secondary operation to restore bowel continuity is usually necessary. It is quite difficult to reverse esophageal discontinuity in the case of secondary reconstruction through the retrosternal space, because extreme adhesion occurs in the retrosternal space as a result of mediastinitis after conduit necrosis and anastomotic leakage. A safer surgical approach is needed in such a stressful condition.

TECHNIQUE

We describe an operative technique in which an esophageal discontinuity was successfully restored without resection of the gastric conduit. Our patient developed a partial necrosis of a reconstructed gastric conduit through the retrosternal space after subtotal esophagectomy for cancer of the upper thoracic esophagus in October 2008. Cervical lymph node dissection and upper abdominal lymph node dissection were performed before thoracotomy. Esophagectomy was performed through a right thoracotomy. A gastric conduit was brought up through the retrosternal space to the neck and anastomosed immediately with the cervical esophagus in an end-to-side fashion. Microscopically, the tumor was resected curatively.

On the 4th postoperative day, cervical wound developed mild redness. We suspected anastomotic leakage and opened the cervical wound 5 cm in length, but no dirty discharge was drained from the opened wound. Although contrast-enhanced CT revealed that there was little fluid retention around the anastomosis on the 7th postoperative day, the reconstructed gastric tube was enhanced and

esophagogastrostomy had kept its continuity. However, saliva was draining through the cervical wound on the 10th postoperative day. On the 14th postoperative day, contrast-enhanced CT showed that there was partial discontinuity of the esophagogastrostomy and that the contrast effect of the cervical part of the gastric tube was partially diminished. Although daily irrigation of the cervical wound was performed, the bad-smelling dirty discharge through the cervical wound did not improve. Contrast radiography through the cervical wound on the 20th postoperative day visualized only the cervical esophagus without visualization of the gastric tube. We suspected partial necrosis of the gastric tube, and we decided to perform the reoperation on the 21st postoperative day. When we opened the cervical wound under general anesthesia, the proximal portion of the gastric tube exhibited necrosis. We resected the necrotic portion of the gastric tube (about 7 cm in length) and made an open drainage of the cervical wound. After diversion surgery, we observed the lumen of the gastric tube directly through the cervical wound, and the gastric mucosal color seemed to be healthy. For persistent serious infection in the cervical space, daily irrigation of the wound was required. The cervical wound was gradually healed and the patient's general condition recovered. Then the proximal portion of the gastric tube was closed (Fig 1B), and a cervical wound developed into an esophago-cutaneous fistula (Fig 1A). We decided to perform salvage surgical restoration on the 92nd postoperative day after esophagectomy.

A neck incision was made around the fistula and on the previous incision. The cervical esophagus was exposed below the cricopharyngeal sphincter and dissected sharply from the surrounding tissues. Special care was taken to avoid dissociating the adhesions around the left recurrent laryngeal nerve. The cervical esophagus was trimmed for the preparation of the anastomosis. The right 3rd and 4th costal cartilages were removed, and the right internal thoracic vessels were preserved for the subsequent vessel anastomoses. The right side of the sternum at the level of the 3rd and 4th intercostal space was partly whittled to about 4×1.5 cm in size, and the surface of the reconstructed gastric tube was exposed. A free jejunal flap about 20 cm in length was made and brought up through the retrosternal-subcutaneous route and interposed between the cervical remnant esophagus and the surface of the gastric tube in

Received for publication May 11, 2018 ; accepted July 29, 2018.

Address correspondence and reprint requests to Tetsuya Abe, M.D., Department of Gastroenterological Surgery, Aichi Cancer Center Hospital, 1-1 Kanokoden, Chikusa-ku, Nagoya, 464-8681, Japan and Fax : +81-52-763-5233.

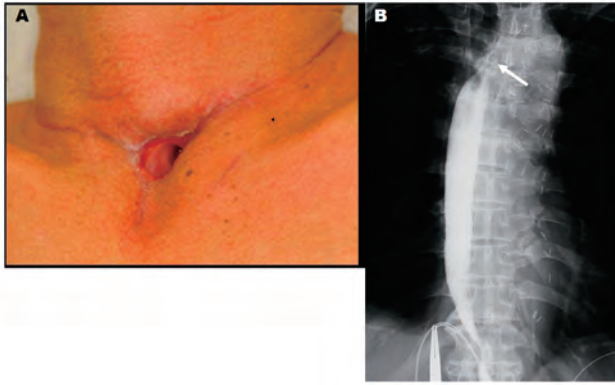


Fig 1. Patient's condition before salvage restoration
(A) External appearance of the cervical wound two months after debridement of the necrotic tissues. The cervical wound gradually healed after debridement and formed a fistula. The distal extremity of the cervical esophagus opened deeply in the cervico-esophageal fistula.
(B) Contrast radiogram from a gastrostomy tube disclosed that a superior extremity of the proximal gastric tube was closed (white arrow).

an end-to-side fashion. We planned the procedure preoperatively to use the right internal thoracic vessels for vessel anastomoses. However, a plastic surgeon abandoned the plan to use the prepared right internal thoracic vessels because of the anatomical positioning of the vascular pedicle and decided intraoperatively to use the left internal thoracic vessels. Therefore, the jejunal vessels were anastomosed with the left internal thoracic vessels microscopically (Fig 2A-C).

Necrosis of free jejunal graft was occurred on the postoperative 8 hours because of the congestive necrosis of venous thrombosis due to the flexion of the anastomosis of the veins. We re-transplanted a free jejunal graft on the postoperative day 1. Thereafter, the patient was recovered without any trouble postoperatively. The patient has remained alive without developing thoracic

deformity and well without any detectable cancer lesions for 8 years after resection of the esophageal cancer.

COMMENT

Orringer and Sloan first introduced retrosternal reconstruction after esophagectomy using a gastric conduit in 1975 (1). Although several cardiovascular complications have been reported, retrosternal reconstruction is cosmetically acceptable and can reduce postoperative esophageal reflux and gastrectasis (1-3). However, partial or total necrosis of the retrosternal gastric conduit infrequently occurs, because the narrow space of the thoracic inlet can lead to compression necrosis against the reconstructed gastric conduit. Once discontinuity of the alimentary tract occurs, salvage secondary reconstruction is extremely challenging.

Resection of the necrotic part of the gastric tube through the retrosternal space usually needs to occur with resection of the manubrium or via median sternotomy (4, 5). Moreover, excessive scar formation with tight adhesion in the retrosternal space usually occurs because of persistent inflammation caused by digestive juice, and a highly invasive operation may be inevitable in such situations. However, these patients are malnourished, and their general condition is compromised. Under these conditions, the surgeon is encouraged to perform less-invasive secondary salvage surgery whenever possible. Therefore, we planned to whittle away at the right side of the body of the sternum minimally above the normal part of the gastric conduit and expose the anterior surface of the gastric conduit, and then make an anastomosis between the remnant esophagus and the exposed gastric conduit with a free jejunal graft through a retrosternal-subcutaneous route. This procedure has low risk and is less invasive, because we can avoid operative manipulation of the extremely inflamed lesion that results from mediastinitis due to gastric conduit necrosis. Although similar procedure had been reported by Fukuda *C et al.* in a Japanese literature, this is the firstly reported in the English literature (6).

A free jejunal graft is a favorable choice for salvage restoration of bowel continuity. A free jejunal graft for pharyngo-esophageal

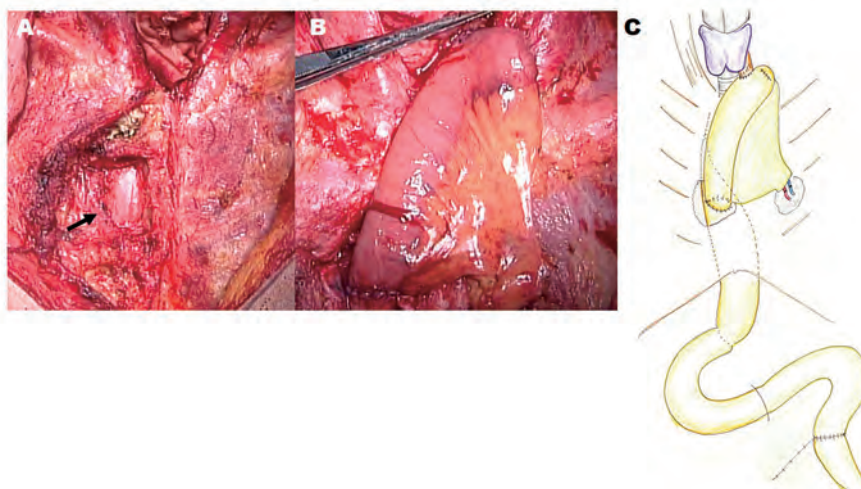


Fig 2. Methods of salvage reconstruction

(A) Black arrow shows the trimmed part of the sternum. The right side of the sternum with a level of 3rd and 4th intercostal space was partly whittled with bone rongeur forceps. The surface of the healthy part of the gastric tube was exposed.
(B) Reconstruction by a free jejunal flap about 20 cm in length through the retrosternal-subcutaneous route and interposed between the cervical remnant esophagus and the surface of the gastric tube. The jejunal vessels were anastomosed with the left internal thoracic vessels microscopically.
(C) Schema shows restored bowel continuity by a jejunal interposition with a free jejunal flap through a retrosternal-subcutaneous route.

reconstruction is a well-accepted, safe technique that provides a reliable functional reconstruction compared with musculocutaneous flap reconstruction (7). Although a free jejunal graft is unlikely to be used for post-esophagectomy patients who previously underwent surgery to restore bowel continuity through a retrosternal or post-mediastinal route, we circumvent this difficulty by trimming the sternum, which provides enough space to anastomose, and bowel continuity can be restored to make an anastomosis between the remnant esophagus and the exposed gastric conduit using a free jejunal graft through a retrosternal-subcutaneous route. Moreover, other methods of restoration, such as colonic interposition and musculocutaneous tube reconstruction, can be adapted later, if our method fails.

Although secondary esophageal restoration is challenging, it is a serious problem that must be overcome for patients with bowel discontinuity. We believe that free jejunal flap reconstruction is a first choice for secondary salvage reconstruction after necrosis of the esophageal conduit, if possible. We must avoid subjecting these exhausted patients undergoing secondary salvage reconstruction to unnecessarily invasive surgery. We must also identify the best strategy for improvement by making the decision on a case-by-case basis.

CONFLICT OF INTEREST

None of the authors have any financial disclosures or conflicts of interest to report.

ACKNOWLEDGEMENTS

The authors have no conflicts of interest and no financial relationships to disclose.

REFERENCES

1. Orringer MB, Sloan H : Substernal gastric bypass of the excluded thoracic esophagus for palliation of esophageal carcinoma. *J Thorac Cardiovasc Surg* 70 : 836-51, 1975
2. Ubukata H, Nakachi T, Tabuchi T, Nagata H, Takemura A, Shimazaki J, Konishi S, Tabuchi T : Gastric tube perforation after esophagectomy for esophageal cancer. *Surg Today* 41 : 612-9, 2011
3. Katsoulis IE, Robotis I, Kouraklis G, Yannopoulos P : Duodenogastric reflux after esophagectomy and gastric pull-up : the effect of the route of reconstruction. *World J Surg* 29 : 174-81, 2005
4. Kinoshita Y, Udagawa H, Tsutsumi K, Ueno M, Mine S, Ehara K : Surgical repair of refractory strictures of esophagogastric anastomoses caused by leakage following esophagectomy. *Dis Esophagus* 22 : 427-33, 2009
5. Barkley C, Orringer MB, Iannettoni MD, Yee J : Challenges in reversing esophageal discontinuity operations. *Ann Thorac Surg* 76 : 989-94 ; discussion 95, 2003
6. Fukuda C, Ide H, Sato Y, Nozaki M, Moriyama T, Narumiya K : A New device of jejunum interposition in a case of necrosed gastric tube after retrosternal gastric tube reconstruction. *J Jpn Surg Assoc* 67 : 2388-91, 2006
7. Okazaki M, Asato H, Takushima A, Nakatsuka T, Ueda K, Harii K : Secondary reconstruction of failed esophageal reconstruction. *Ann Plast Surg* 54 : 530-7, 2005