

## CASE REPORT

# The repeating dislodgement of an Amplatzer Septal Occluder device during recovery from general anesthesia in an adult undergoing transcatheter closure of atrial septal defect : a case report

Natsuki Abe<sup>1</sup>, Masanori Go<sup>2</sup>, Kaori Nakai<sup>2</sup>, Michihisa Kato<sup>2</sup>, and Katsuya Tanaka<sup>3</sup>

<sup>1</sup>Department of Anesthesiology, Tokushima Prefectural Central Hospital, Tokushima, Japan, <sup>2</sup>Department of Anesthesiology, Tokushima Red Cross Hospital, Tokushima, Japan, <sup>3</sup>Department of Anesthesiology, Tokushima University, Tokushima, Japan

**Abstract :** Transcatheter closure with an Amplatzer Septal Occluder (ASO) has become the standard treatment for secundum atrial septal defect (ASD). However, this procedure is associated with complications, such as device dislodgement. A 52-year-old woman was admitted with exertional dyspnea. Transesophageal echocardiography showed an ASD involving a 29 mm defect. Calculated Qp/Qs was 5.6 and all the rims were > 5 mm, with the exception of the posterior rim, which was 3 mm. Transcatheter ASD closure with an ASO was performed under general anesthesia. During emergence from anesthesia, tachycardia developed and the ASO device became dislodged. Hemodynamic changes associated with the end of anesthetic administration were believed to have led to device dislodgement. In a second transcatheter ASD closure, a low dose of propofol and remifentanyl was maintained during emergence from anesthesia to reduce hemodynamic changes. However, device dislodgement occurred with nonsustained ventricular tachycardia. Finally, surgical ASD closure was performed. The large defect size, high Qp/Qs, and rim deficiency may have predisposed to device dislodgement after transcatheter ASD closure with ASO. The risk of device dislodgement should be considered in advance of surgery and, in high-risk cases, the patient's cardiovascular status should be closely monitored. *J. Med. Invest.* 66 : 194-198, February, 2019

**Keywords :** Atrial septal defect, Amplatzer Septal Occluder, Device dislodgement, Arrhythmia

## INTRODUCTION

Atrial septal defect (ASD) is a common congenital heart disease. Recently, transcatheter closure has become the standard treatment for secundum ASD. The Amplatzer Septal Occluder (ASO ; AGA Medical Corp, Golden Valley, MN, USA) is the most widely used device for transcatheter ASD closure, due to its unique design, easy handling, and high success rate. However, well known complications include device dislodgement and embolization, which account for approximately 51.1% of the adverse events associated with ASO closure (1). Here, we reported a case of repeated ASO dislodgement during recovery from general anesthesia following transcatheter ASD closure.

## CASE PRESENTATION

A 52-year-old woman was admitted to our hospital with exertional dyspnea. Electrocardiogram (ECG) showed right axis deviation and an incomplete right bundle branch block. On chest X-ray, the cardiothoracic ratio was 59% and increased pulmonary vascular markings were seen. Transesophageal echocardiography (TEE) demonstrated a defect of the secundum atrial septum with

left-to-right shunts. The defect size was approximately 29 mm. Calculated Qp/Qs was 5.6. All the rims were > 5 mm, except for the posterior rim, which was 3 mm.

The defect size seen in this patient was large enough to warrant surgery and also considered suitable for transcatheter ASD closure with an ASO, i.e., the defect size was < 38 mm and distances between the defect and the coronary sinus, atrioventricular valve, and right superior pulmonary vein were > 5 mm. Although the posterior rim was rather small, cases of successful transcatheter ASD closure in patients with posterior, inferior, or superior rim deficiency have been reported (2). In our case, the patient requested a treatment with shorter hospitalization and transcatheter ASD closure with an ASO was scheduled.

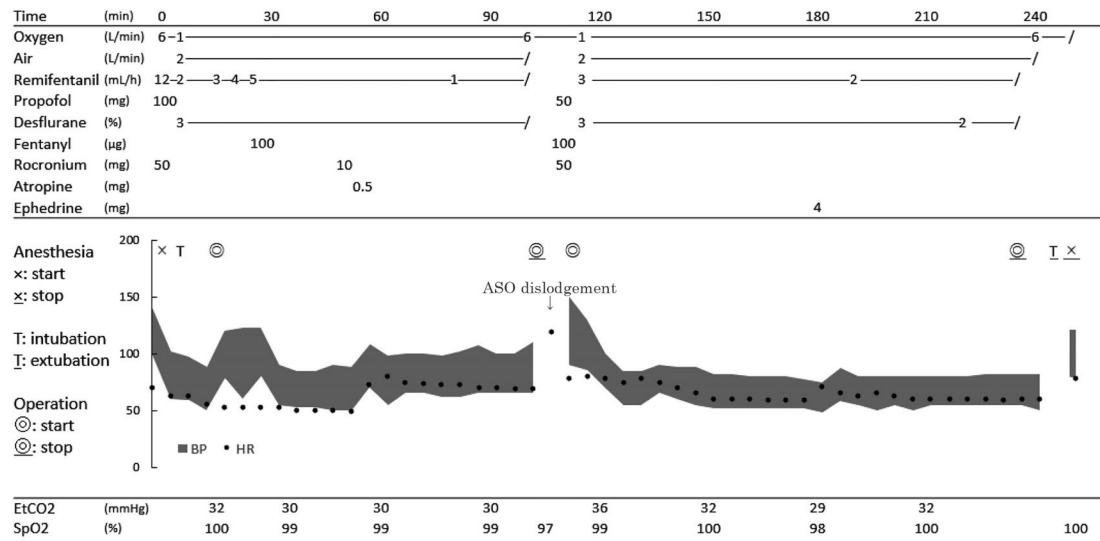
Defect closure was performed under general anesthesia and continuous TEE monitoring. General anesthesia was induced with propofol 100 mg and remifentanyl 0.4 µg/kg/min. The tracheal tube was inserted following administration of rocuronium 50 mg. Anesthesia was maintained with 3-3.5% desflurane and 0.05-0.15 µg/kg/min remifentanyl. Rocuronium was added approximately to maintain muscular relaxation. The patient's vital sign during procedure was showed in an anesthetic record (Figure 1A).

In balloon sizing, a 31 mm stretched balloon diameter allowed a small amount of leakage. A 32 mm ASO device was selected and the disk was deployed under fluoroscopic guidance. Before the device was released from the delivery cable, the cable was moved a little to ensure that the device was securely in place. TEE and intra cardiac echo (ICE) confirmed the appropriate positioning of the device with no residual shunt, and showed that it was holding at the posterior rim between the two disks (Figure 2A). The device was

Received for publication September 18, 2018 ; accepted October 22, 2018.

Address correspondence and reprint requests to Natsuki Abe, M.D., Department of Anesthesiology, Tokushima Prefectural Central Hospital, 1-10-3 Kuramoto, Tokushima 770-8539, Japan and Fax : +81-88-631-8354.

A.



B.

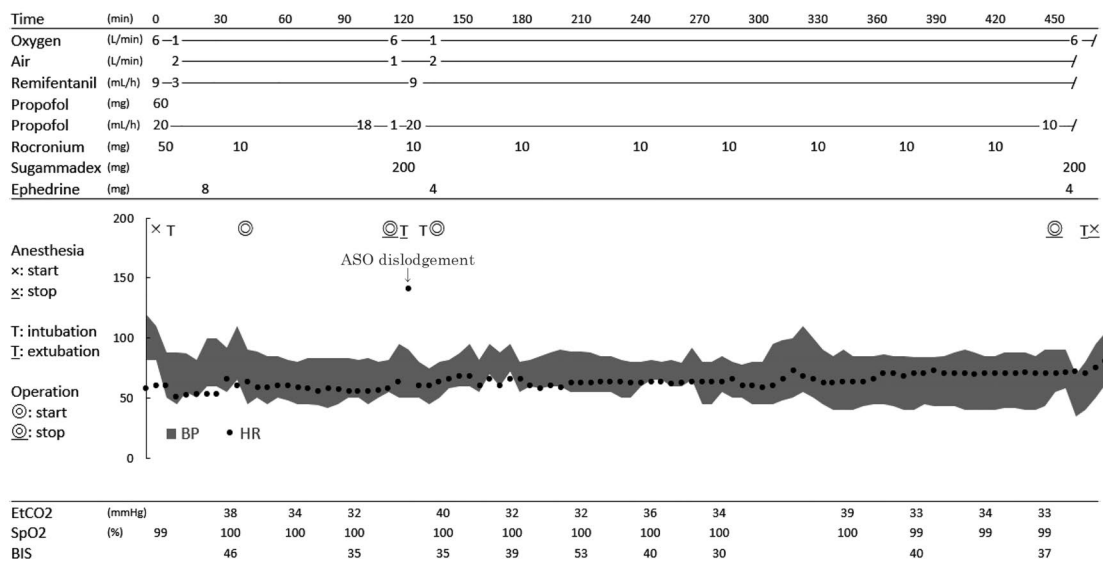


Figure 1. Anesthetic records

A : Anesthetic record of the first transcatheter ASD closure. There were some blanks in blood pressure paragraph because of an omission.

B : Anesthetic record of the second transcatheter ASD closure. After the extubation, tachycardia occurred with HR over 140/min.

BP = blood pressure, HR = heart rate.

A slash mark indicate to end the administration of each medication.

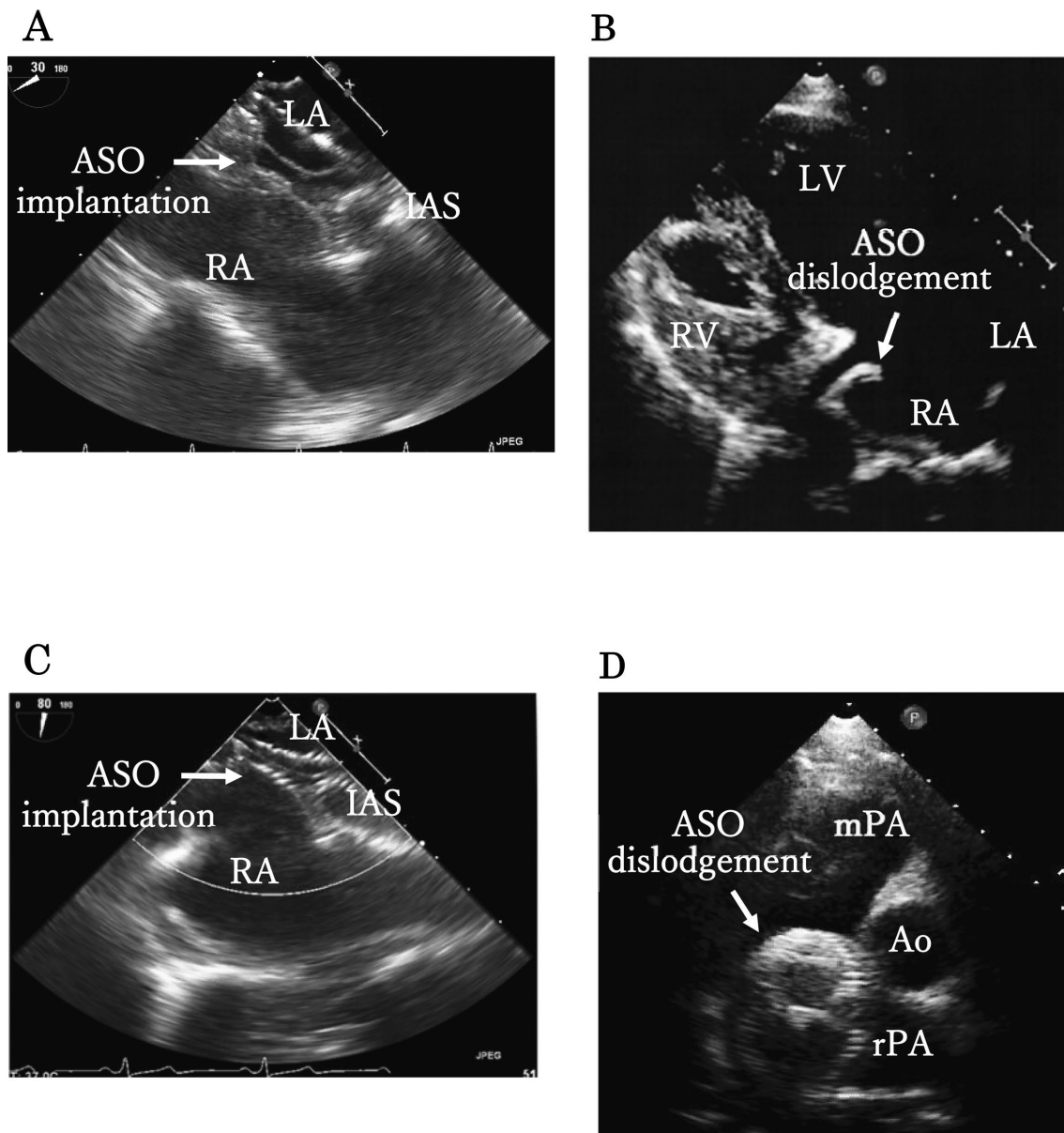
then released. There were no findings of changes in the position of the device until the end of surgery.

Ahead of waking from anesthesia, remifentanyl and desflurane were discontinued. Prior to sugammadex administration, ECG monitoring showed tachycardia (Figure 3A) and we considered that the arrhythmia was an indication of ASO dislodgement. Transthoracic echocardiography (TTE) confirmed that the device was located in the right atrium (Figure 2B). General anesthesia with propofol and remifentanyl was reintroduced, along with rocuronium to maintain muscle relaxation. Transcatheter removal of the device was subsequently performed with no adverse event.

The patient recovered well from the procedure and requested a

repeat transcatheter approach. A second transcatheter ASD closure with an ASO was scheduled. As the cause of the first device dislodgement may have been hemodynamic changes, such as temporary elevation of blood pressure during recovery from sedation, we planned to continue low dose anesthetic administration until extubation to stabilize the patient's hemodynamics.

Defect closure was performed for the second time 2 months after the first. Anesthesia was maintained with 3-4 mg/kg/h propofol instead of desflurane (Figure 1B). We attempted to position a 34 mm Amplatzer device, but this appeared to be too large, pushing the posterior heart wall, so a 32 mm ASO device was again selected. Positioning was monitored by TEE and ICE before finally being



**Figure 2.** Echograms during the transcatheter ASD closure procedure

A : TEE image indicates the implantation device holding the IAS at the first time procedure.

B : TTE image indicates the dislodgement device in the right atrium at the first time procedure.

C : TEE image indicates the implantation device holding the IAS at the second time procedure.

D : TTE image indicates the dislodgement device in the pulmonary artery at the second time procedure.

Ao = aorta, ASO = Amplatzer Septal Occluder, IAS = interatrial septum, LA = left atrium, LV = left ventricle, mPA = main pulmonary artery, RA = right atrium, RV = right ventricle, rPA = right pulmonary artery.

released (Figure 2C). The dose of propofol and remifentanyl was maintained at 10 mg/h and 0.09  $\mu\text{g}/\text{kg}/\text{h}$ , respectively, after completion of the procedure to extubation. Sugammadex was administered and the patient was extubated; then, ECG monitoring showed nonsustained ventricular tachycardia (Figure 3B). TTE detected the ASO device in the pulmonary artery (Figure 2D). Anesthesia was reintroduced and reintubation was conducted. The device was retrieved under transcatheter management.

We concluded that transcatheter ASD closure in this patient was too challenging and surgical ASD was conducted by cardiac surgeons in our hospital 4 months later after the second transcatheter ASD closure. Surgery was completed successfully and the patient continues to do well.

## DISCUSSION

The first report of a transcatheter ASD closure was published by King and Millis in 1976 (3). Transcatheter approaches have proved to be as effective as surgical ASD closure, and offer significant benefits in terms of low invasiveness, shorter hospitalization, and fewer complications (4). In a comparison of outcomes following transcatheter and surgical ASD closure, Du *et al* reported a procedural attempt success rate, complication rate, and mean length of hospital stay of 95.7%, 7.2%, and  $1.0 \pm 0.3$  days for patients in the device group versus 100%, 24.0%, and  $3.4 \pm 1.2$  days for the surgical group (5). However, there are a number of complications associated with transcatheter ASD closure, such as heart wall erosion, cardiac perforation, arrhythmia, and device dislodgement (1).

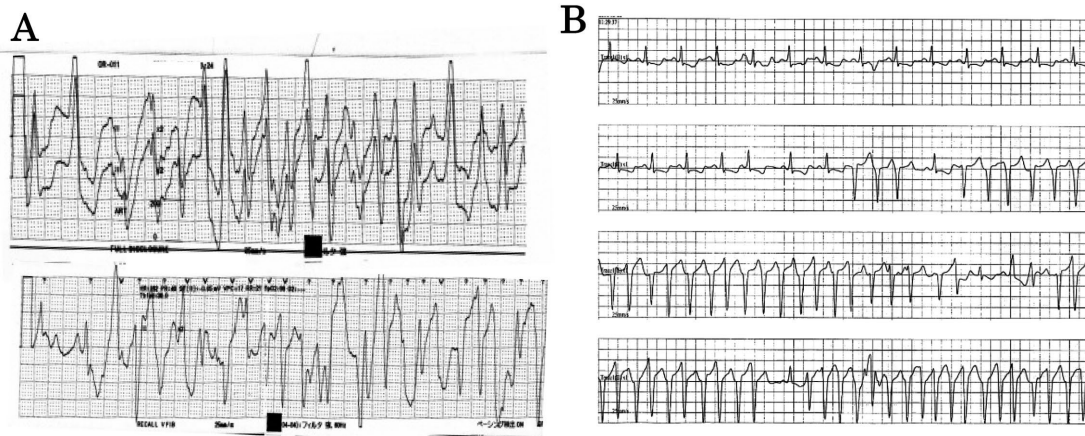


Figure 3. ECG waveform during emergence from general anesthesia  
 A : ECG during the first transcatheter ASD closure, suggesting tachycardia.  
 B : ECG during the second transcatheter ASD closure, showing typical nonsustained ventricular tachycardia.

Device dislodgement may cause valvular disease with rupture of the chordae tendinae or device embolization, and subsequent heart failure or infarction can prove fatal. Previous studies have shown the rate of device dislodgement to be 0.5-5.5% (1, 6), generally occurring in the first 24 hours after the procedure (5). However, dislodgement may also occur many years after the intervention.

Lee *et al* reported that a Qp/Qs ratio > 3.13, interatrial septum erosion, and floppiness or aneurysm formation post-implantation may be predictors of ASO dislodgement in adults and children (7). In particular, high Qp/Qs ratios may be related to greater changes in intracardiac pressure, which affects device imbalance. Other reports have shown that ASD size, superior posterior rim or aortic rim deficiency, and septal rim length < 5 mm may also be predictors of possible device dislodgement. Ueda *et al* reported that transcatheter closure in patients with relatively large ASDs, a poor aortic rim, and an inferoposterior rim < 5 mm was associated with greater procedural difficulty and required a longer procedure time (8).

In another report, ST elevation in V1-V5 was seen in a patient with dislodgement of the ventricular septal occluder device (9). DiBardino *et al* also noted that a secondary arrhythmia, such as NSVT, atrial flutter, and premature ventricular contraction, occurred with embolization (1). The arrhythmia and other ECG changes are often the 'warning sign' of an adverse event. On the other hand, the arrhythmia can induce the device dislodgement and subsequent embolization in itself.

In our case, we experienced repeated device dislodgement in an adult patient undergoing transcatheter ASD closure with an ASO. The Qp/Qs ratio was 5.6, ASD size was 29 mm, and inferoposterior rim was < 5 mm, factors that could have predicted a high risk of device dislodgement. On both attempts, dislodgement occurred during recovery from general anesthesia, suggesting that this period poses a particularly high risk. At recovery from anesthesia, hemodynamics can be unstable. In most cases, blood pressure and heart rate will rise due to the end of anesthetic administration suppressing cardiac output and vascular resistance or the activation of the sympathetic nervous system with awakening. Hemodynamic changes may affect the ASO device stability, and result in the device dislodgement. However, attempting to decrease hemodynamic changes during recovery from general anesthesia is unlikely to result in a reduced incidence of device dislodgement as hemodynamic changes also occur during exercise and stimulation in

daily life. In both transcatheter ASD closure attempts, the tachycardiac arrhythmia possibly indicated the device dislodgement. The 12-lead ECG monitor may have been useful to notice the arrhythmia immediately.

Minimizing the risk of complications is dependent on careful case selection, size of the defect, use of the appropriately sized device, and TEE monitoring during the transcatheter procedure. In addition, it is important that anesthesiologists, cardiologists, and cardiac surgeons anticipate the risk of device dislodgement, particularly during deployment and emergence from anesthesia, and plan appropriate treatment strategies in advance. In high-risk cases, we should monitor the patient's cardiovascular status constantly.

## CONCLUSIONS

In this case, we experienced the repeated dislodgement of an ASO device during emergence from general anesthesia in a patient undergoing transcatheter ASD closure. We suggest that the risk of device dislodgement should be anticipated in advance of surgery and that the cardiovascular status of high-risk patients should be monitored continuously during the procedure.

## COMPETING INTERESTS

The authors declare no conflicts of interest associated with this manuscript.

## ACKNOWLEDGEMENTS

We would like to thank Bioedit (<https://www.bioedit.jp/>) for the English language editing.

## REFERENCES

1. DiBardino DJ, McElhinney DB, Kaza AK, Mayer JE Jr : Analysis of the US Food and Drug Administration Manufacturer

and User Facility Device Experience database for adverse events involving Amplatzer septal occluder devices and comparison with the Society of Thoracic Surgery congenital cardiac surgery database. *J Thorac Cardiovasc Surg* 137 : 1334-41, 2009

2. Baruteau AE, Petit J, Lambert V, Gouton M, Piot D, Brenot P, Angel CY, Houyel L, Le Bret E, Roussin R, Ly M, Capderou A, Belli E : Transcatheter closure of large atrial septal defects : feasibility and safety in a large adult and pediatric population. *Circ Cardiovasc Interv* 7 : 837-43, 2014
3. King TD, Thompson SL, Steiner C, Mills NL : Secundum atrial septal defect. Nonoperative closure during cardiac catheterization. *JAMA* 235 : 2506-9, 1976
4. Omeish A, Hijazi ZM : Transcatheter closure of atrial septal defects in children & adults using the Amplatzer Septal Occluder. *J Interv Cardiol* 14 : 37-44, 2001
5. Du ZD, Hijazi ZM, Kleinman CS, Silverman NH, Larntz K : Comparison between transcatheter and surgical closure of secundum atrial septal defect in children and adults : results of a multicenter nonrandomized trial. *J Am Coll Cardiol* 39 : 1836-44, 2002
6. Behjati M, Rafiei M, Soltani MH, Emami M, Dehghani M : Transcatheter closure of atrial septal defect with amplatzer septal occluder in adults : immediate, short, and intermediate-term results. *J Tehran Heart Cent* 6 : 79-84, 2011
7. Lee WC, Fang CY, Huang CF, Lin YJ, Wu CJ, Fang HY : Predictors of Atrial Septal Defect Occluder Dislodgement. *Int Heart J* 56 : 428-31, 2015
8. Hideaki U, Sadamitsu Y, Daiki M, Tatsunori H, Seiyu Y, Yuuko T, Toshihide A : Efficacy and Safety of Atrial Septal Defect Closure with Amplatzer Septal Occluder in Japan : Comparison between cardiac catheter interventions and surgical procedures. *Ped Cardiol Card Surg* 28 : 250-7, 2012
9. Sorgente A, Pedrazzini GB, Faletra FF, Moccetti T, Auricchio A : Dislodgement of an Amplatzer occluder device causing iatrogenic pulmonary embolism in a patient with post-infarction ventricular septal defect. *Eur Heart J* 29 : 2698, 2008