

ORIGINAL

Short-term pre-operative systemic administration with low-dose of steroid does not make a false-negative diagnosis of definite eosinophilic chronic rhinosinusitis after endoscopic sinus surgery

Chisa Fujimoto^{a,b}, Koichi Tamura^b, Shizuka Takaishi^b, Ikuji Kawata^a, Yoshiaki Kitamura^c, and Noriaki Takeda^c

^aDepartment of Otolaryngology, Yoshinogawa Medical Center, Tokushima, Japan

^bDepartment of Otolaryngology, Tokushima Municipal Hospital, Tokushima, Japan

^cDepartment of Otolaryngology, Institute of Biomedical Sciences, The University of Tokushima Graduate School, Tokushima, Japan

Abstract : According to JESREC criteria, definite eosinophilic chronic rhinosinusitis (ECRS) is postoperatively diagnosed based on over 70 eosinophils in high power magnification fields of the resected nasal polyps in patients with probable ECRS. Preoperative systemic administration with steroid is a standard practice, because it reduced intraoperative bleeding during endoscopic sinus surgery (ESS) in patients with ECRS. However, it was recently reported that systemic administration with steroid decreased the number of eosinophils in the nasal polyps, leading to a false negative diagnosis of definite ECRS. To overcome the risk, we have adopted short-term pre-operative systemic administration with low-dose of steroid and examined if our steroid administration makes a false-negative diagnosis. We performed a retrospective chart review of 42 patients with probable ECRS. Eleven patients were administered with 0.5 mg of bethametasone for 7 days before ESS, and other 31 patients were not administered. The average number of eosinophils in nasal polyps in patients who were administered with steroid was 188 ± 167 , which was not different from 199 ± 149 in the patients who were not administered. These findings suggest that short-term preoperative administration with low-dose of steroid has few risk of a false-negative diagnosis of definite ECRS. *J. Med. Invest.* 66:233-236, August, 2019

Keywords : eosinophilic chronic rhinosinusitis (ECRS), chronic rhinosinusitis with nasal polyps, preoperative systemic steroids, endoscopic sinus surgery (ESS), Japanese Epidemiological Survey of Refractory Eosinophilic Chronic Rhinosinusitis (JESREC).

INTRODUCTION

Chronic rhinosinusitis (CRS) is a common otorhinolaryngological disease, and classified into CRS with or without nasal polyps (1). In CRS with nasal polyps, eosinophil infiltration is dominant in Western countries (2). However, until the 1990s in Japan and East Asia, neutrophil infiltration had been dominant in CRS with nasal polyps, which was successfully treated with endoscopic sinus surgery (ESS) (3). Recently, the incidence of CRS with nasal polyps with eosinophilic infiltration increased gradually in Japan and East Asia (4,5). The CRS with nasal polyps with eosinophilic infiltration is refractory, because nasal polyps often recur soon after ESS (3). To differentiate from CRS with nasal polyps of neutrophil infiltration, CRS with nasal polyps of eosinophilic infiltration was denominated as eosinophilic CRS (ECRS) in Japan (6), and the JESREC (Japanese Epidemiological Survey of Refractory Eosinophilic Chronic Rhinosinusitis) Study has published the diagnostic criteria of ECRS (4). According to the criteria, probable ECRS is clinically diagnosed, and is classified into three severities : mild, moderate or severe. Definite ECRS is postoperatively diagnosed based on the number of eosinophils in the resected nasal polyps.

Besides, intraoperative bleeding increases the risk of severe

complications after ESS in patients with CRS. Perioperative managements such as the inverse Trendelenburg position, topical vasoconstrictor and controlled hypotension are usually used to reduce bleeding during ESS. Recently, it was reported that preoperative systemic administration with steroid in the patients with CRS with nasal polyps improved the visibility of the operative field with reduced bleeding during ESS (7) followed by better surgical outcomes after ESS (8). Thus, in Japan preoperative systemic administration with steroid is now becoming a standard practice of otolaryngologist performing ESS for ECRS.

According to JESREC diagnostic criteria, definite ECRS is diagnosed after ESS, based on the histological findings of more than 70 eosinophils in high power magnification fields of the resected nasal polyps. But, it was reported that systemic administration with steroid decreased the number of eosinophils in the nasal polyps in patients with CRS with nasal polyps (9). Therefore, there is a risk that preoperative systemic administration with steroid makes a false negative diagnosis of definite ECRS in patients with probable ECRS after ESS. To overcome this problem, we have adopted to administer low dose of steroid to patients with probable ECRS for short-term before ESS.

In the present study, an attempt was made to clarify if short-term preoperative systemic administration with low-dose of steroid in patients with probable ECRS makes to a false-negative diagnosis of definite ECRS after ESS. For this purpose, we examined the effects of oral administration with 0.5 mg/day of bethametasone for 7 days before ESS on the number of eosinophils in the resected nasal polyps of patients with probable ECRS.

Received for publication January 7, 2019 ; accepted February 18, 2019.

Address correspondence and reprint requests to Chisa Fujimoto, M.D. Ph.D. Department of Otolaryngology, Yoshinogawa Medical Center, Tokushima, Japan. 120 Chiejima Aza Nishichiejima, Kamojima, Yoshinogawa, Tokushima, Japan and Fax : +81-883-26-2300.

PATIENTS AND METHODS

We performed a retrospective chart review of 92 patients with CRS (60 males and 32 females; 11 to 82 years old, average age: 49.3 years old) who received ESS at Tokushima Municipal Hospital, Tokushima, Japan from July 2013 to September 2015. According to JESREC diagnostic criteria, probable ECRS and non-ECRS were diagnosed in 42 and 50 patients respectively. Eleven patients with probable ECRS were administered a daily dose of 0.5 mg bethametasone tablet for 7 consecutive days and the last one on the day before ESS, and another group of 31 patients received no preoperative pharmacological treatments. The present study was approved by the Committee for Medical Ethics of Tokushima Municipal Hospital.

Nasal polyps obtained during ESS were immediately fixed in 10% formalin, embedded in paraffin, and cut in thin sections of 2 μ m. The sections were stained with hematoxylin-eosin, and the number of eosinophils in nasal polyps was measured at high power ($\times 400$) magnification fields in the densest area with cellular infiltrate beneath the epithelial surface.

Data were analyzed using χ^2 test, Student's *t*-test, Mann-Whitney's U test. *P*-value < 0.05 was considered statistically significant.

RESULTS

According to JESREC diagnostic criteria of ECRS, probable ECRS was diagnosed in 42 of 92 patients with CRS. Of the 42 patients with probable ECRS, 31 were males and 11 were females (15 to 77 years old, average age: 52.9 years old). And among the 50 patients with non-ECRS, 29 were males and 21 were females (11 to 82 years old, average age: 46.3 years old). Probable ECRS were further subdivided into 3 groups as follows: 10 mild, 20 moderate and 12 severe. The prevalence of probable ECRS increased with age and reached a maximum at the sixth decade, and non-ECRS developed irrespective of age (Figure 1). Definite ECRS (25 males and 9 females; 29 to 77 years old, average age: 54.8 years old) was postoperatively diagnosed in 34 of the 42 patients with probable ECRS, based on the number of eosinophils in the resected nasal polyps according to JESREC diagnostic criteria.

Eleven of 42 patients with probable ECRS were administered low-dose of steroid orally for 7 days before ESS. No differences in sex, age or severity were noted between patients with or without preoperative treatment (Table 1). The number of eosinophils

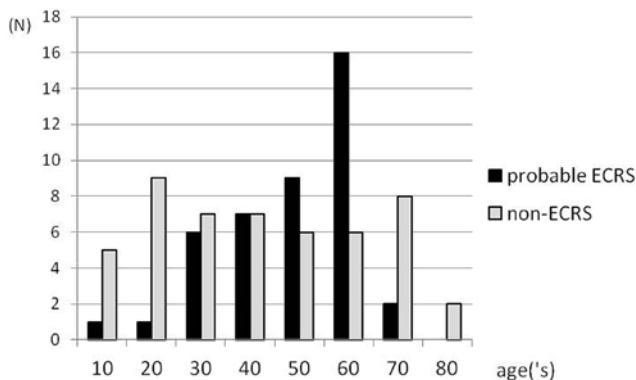


Figure 1 The prevalence of probable ECRS and non-ECRS at each decade. ECRS: eosinophilic chronic rhinosinusitis.

Table 1 Characteristics of patients with probable ECRS

	Steroid (n = 11)	Non-steroids (n = 31)	<i>P</i> -value
Sex			
Male	10	21	0.13*
Female	1	10	
Age	54.0 \pm 17.1	52.5 \pm 12.7	0.77**
Severity			
Mild	3	7	0.49***
Moderate	3	17	
Severe	5	7	

*: χ^2 test **: Student's *t*-test ***: Mann-Whitney U test

was 188 ± 167 in high power magnification fields in the nasal polyps of patients with short-term preoperative systemic administration of low-dose of steroid. The number of eosinophils in the nasal polyps of the remaining 31 patients who were received no pharmacological treatment was 199 ± 149 in high power magnification fields, which was not different from that with short-term preoperative systemic administration with low-dose of steroid (Figure 2). In addition, among mild, moderate and severe groups, there were no differences of distribution of eosinophil number in the nasal polyps between patients with or without short-term preoperative administration with low-dose of steroid (Figure 3).

DISCUSSIONS

In the present study, according to JESREC diagnosis criteria, about half of patients with CRS were given the diagnosis of probable ECRS, probably because of increasing incidence of CRS with nasal polyposis that is infiltrated by eosinophils in Japan and East Asia (4,5). The prevalence of ECRS, but not non-ECRS

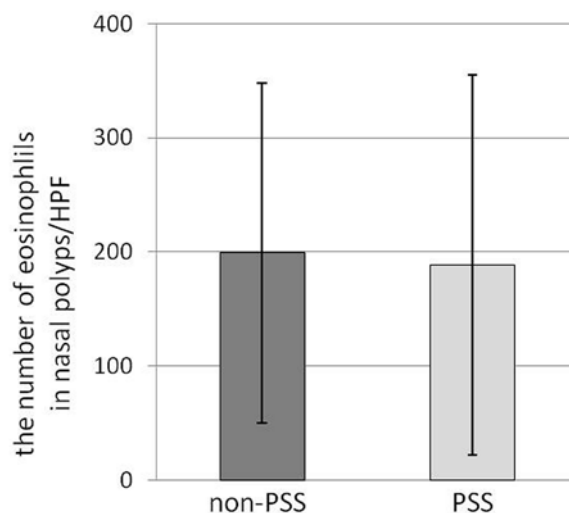


Figure 2 The number of eosinophils in the nasal polyps in patients with probable ECRS with or without PSS. Columns and bars represent average and standard deviation. ECRS: eosinophilic chronic rhinosinusitis. PSS: preoperative systemic steroid. HPF: high power magnification fields.

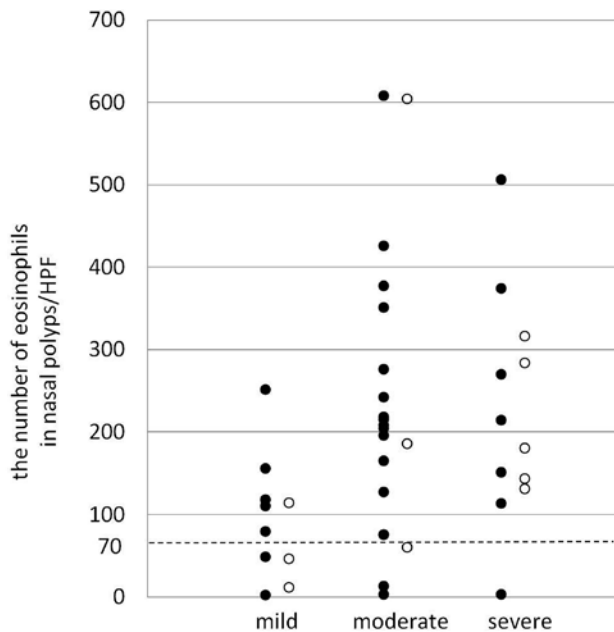


Figure 3 The distribution of eosinophil number in the nasal polyps in patients with mild, moderate and severe probable ECRS. Definite ECRS is diagnosed in patients with probable ECRS when their nasal polyps contain more than 70 eosinophils (dotted line) in high power magnification field (HPF). ECRS : eosinophilic chronic rhinosinusitis. Open circles : PSS. Closed circles : non-PSS. PSS : preoperative systemic steroid.

increased with age with the maximum prevalence at the sixth decade. ECRS is often associated with asthma, probably because of the same underlying pathophysiology of eosinophilic inflammation of the respiratory tracts (4). Therefore, it is suggested the prevalence of ECRS is similar to that of asthma with the maximum prevalence at the early seventh decade (10).

It was reported that daily administration with prednisolone at a dose of 15 mg for 10 days or 20 mg for 14 days reduced the number of eosinophils in the nasal polyps of patients with CRS with nasal polyps (9,11). Accordingly, there was a possibility that preoperative administration with steroid reduced the number of eosinophils in the nasal polyps, resulting in a false negative diagnosis of definite ECRS after ESS, because definite ECRS is diagnosed based on the microscopic findings of more than 70 eosinophils in high power magnification fields of the resected nasal polyps. But, the possibility is unlikely, because as shown in the present study, the number of eosinophils in the nasal polyps in patients with ECRS who received preoperative systemic administration with 0.5 mg of betamethasone that is equivalent to 5 mg of prednisone for 7 days was not different from that without any preoperative pharmacological treatment. Moreover, three patients (2 of mild and 1 of moderate) may have been given a false negative diagnosis of definite ECRS. But, the risk is also unlikely, because the distribution of eosinophil number in the nasal polyps after short-term preoperative systemic administration with low-dose of steroid was not different from that without any preoperative pharmacological treatment among mild and moderate groups. Taken together, these findings suggest that short-term preoperative systemic administration with low-dose of steroid did not make a false-negative diagnosis of definite ECRS after ESS.

Limitations : The present study was a retrospective chart review, but not randomized controlled one. Because individual operative methods varied among ESS with/without septoplasty

and/or submucosal turbinotomy, we cannot compare amount of intraoperative blood loss and surgical time with low dose of steroid to those without one.

CONCLUSION

In the present study, systemic administration with 0.5 mg of bethametasone for 7 days did not decrease the number of eosinophils in the nasal polyps in patients with probable ECRS. Thus, it is suggested that short-term preoperative administration with low-dose of steroid has few risk of a false-negative diagnosis of definite ECRS after ESS. However, a randomized prospective controlled study should be undertaken to confirm our conclusion. Furthermore, there is also a need to evaluate how short-term preoperative administration with low-dose steroid reduces the risk of complication after ESS.

CONFLICT OF INTEREST

The authors declare no conflicts of interest.

ACKNOWLEDGEMENTS

We would like to acknowledge the support of Hiroshi Kiyoku and colleagues of the Department of Pathology of Tokushima Municipal Hospital.

REFERENCES

1. Fokkens WJ, Lund VJ, Mullol J, Bachert C, Alobid I, Baroody F, Cohen N, Cervin A, Douglas R, Gevaert P, Georgalas C, Goossens H, Harvey R, Hellings P, Hopkins C, Jones N, Joos G, Kalogjera L, Kern B, Kowalski M, Price D, Riechelmann H, Schlosser R, Senior B, Thomas M, Toskala E, Voegels R, Wang de Y, Wormald PJ : European Position Paper on Rhinosinusitis and Nasal Polyps 2012. *Rhinol* 23 Suppl 3, 1-298, 2012.
2. Van Zele T, Claeys S, Gevaert P, Van Maele G, Holtappels G, Van Cauwenberge P, Bachert C : Differentiation of chronic sinus diseases by measurement of inflammatory mediators. *Allergy* 61 : 1280-1289, 2006
3. Nakayama T, Yoshikawa M, Asaka D, Okushi T, Matsuwaki Y, Otori N, Hama T, Moriyama H : Mucosal eosinophilia and recurrence of nasal polyps - new classification of chronic rhinosinusitis. *Rhinology* 49 : 392-396, 2011
4. Tokunaga T, Sakashita M, Haruna T, Asaka D, Takeno S, Ikeda H, Nakayama T, Seki N, Ito S, Murata J, Sakuma Y, Yoshida N, Terada T, Morikura I, Sakaida H, Kondo K, Teraguchi K, Okano M, Otori N, Yoshikawa M, Hirakawa K, Haruna S, Himi T, Ikeda K, Ishitoya J, Iino Y, Kawata R, Kawauchi H, Kobayashi M, Yamasoba T, Miwa T, Urashima M, Tamari M, Noguchi E, Ninomiya T, Imoto Y, Morikawa T, Tomita K, Takabayashi T, Fujieda S : Novel scoring system and algorithm for classifying chronic rhinosinusitis: the JESREC Study. *Allergy* 70 : 995-1003, 2015
5. Kim SJ, Lee KH, Kim SW, Cho JS, Park YK, Shin SY : Changes in histological features of nasal polyps in a Korean population over a 17-year period. *Otolaryngol Head Neck Surg* 149 : 431-437, 2013
6. Haruna S, Nakanishi M, Otori N, Moriyama H : Histopathological features of nasal polyps with asthma association : an immunohistochemical study. *Am J Rhinol*

- 18 : 165-172, 2004
7. Sieskiewicz A, Olszewska E, Rogowski M, Grycz E : Preoperative corticosteroid oral therapy and intraoperative bleeding during functional endoscopic sinus surgery in patients with severe nasal polyposis : a preliminary investigation. *Ann Otol Rhinol Laryngol* 115 : 490-494, 2006
 8. Wright ED, Agrawal S : Impact of perioperative systemic steroids on surgical outcomes in patients with chronic rhinosinusitis with polyposis : evaluation with the novel Perioperative Sinus Endoscopy (POSE) scoring system. *Laryngoscope* 117 : 1-28, 2007
 9. Hong SJ, Lee JK, Lee HS, Lee JY, Pyo JS, Lee KC : Availability of preoperative systemic steroids on endoscopic sinus surgery for chronic rhinosinusitis with nasal polyposis. *Yonsei Med J* 55 : 1683-1690, 2014
 10. Ichinose M, Sugiura H, Nagase H, Yamaguchi M, Inoue H, Sagara H, Tamaoki J, Tohda Y, Munakata M, Yamauchi K, Ohta K : Japanese guidelines for adult asthma 2017. *Allergol Int* 66 : 163-189, 2017
 11. Won TB, Jang E, Min SK, Kim SW : Treatment outcomes and predictors for systemic steroids in nasal polyposis. *Acta Otolaryngol* 132 Suppl 1 : 82-87, 2012