

**ORIGINAL****Surgical training in video-assisted neck surgery-based thyroidectomy using fresh frozen human cadavers**Mariko Aoyama<sup>1</sup>, Hiromitsu Takizawa<sup>1</sup>, Mitsuhiro Tsuboi<sup>1</sup>, Shinichi Yamasaki<sup>2</sup>, Yoshihiro Tsuruo<sup>3</sup>, and Akira Tangoku<sup>1</sup><sup>1</sup>Department of Thoracic, Endocrine Surgery, and Oncology; Institute of Health; Biosciences; The University of Tokushima, Tokushima, Japan, <sup>2</sup>Department of Surgery, Tokushima Municipal Hospital, Tokushima, Japan, <sup>3</sup>Department of Anatomy and Cell Biology; Institute of Biomedical Science; Tokushima University Graduate School, Tokushima, Japan

**Abstract :** Endoscopic surgery has been introduced in various surgical fields. Endoscopic surgery requires different skills from open surgery due to the restricted surgical field and difficulty in identifying anatomical structures from certain viewpoints. Therefore, surgeons need to undergo sufficient surgical training before performing such surgery in the clinical setting. We examined the utility of fresh frozen human cadavers for surgical training aimed at introducing video-assisted neck surgery (VANS) at our department. First, we performed surgical training using fresh human cadavers four times. Next, we performed hemi-thyroidectomy with VANS in 5 clinical patients. After the cadaver training and the actual surgery, the surgeons evaluated each step of the surgical procedure using a 3-point scale. In the cadaver training, the scores for steps : creation of a subcutaneous tunnel and lifting up the skin flap and pre-thyroid muscles were higher than other steps. And a tracheal injury occurred as a complication. However, we were able to recognize anatomical structures under the endoscopic view. And it was also useful for confirming the role of surgical staff and simulating the placement of surgical equipment. Surgical training using fresh frozen human cadavers was effective at introducing a new surgical method. *J. Med. Invest.* 66: 293-296, August, 2019

**Keywords :** video-assisted neck surgery, fresh frozen human cadaver, thyroidectomy

**BACKGROUND**

Video-assisted neck surgery (VANS) for the treatment of thyroid tumors was reported by Shimizu in 1999 (1), and VANS for thyroid disease has been covered by the Japanese health insurance system since 2016. Compared with open surgery, VANS produces superior cosmetic results because the surgical wound is not noticeable (1, 2). As thyroid disease exhibits a predilection for female patients, VANS is expected to become a standard surgical method in future.

The endoscopic approach requires different skills from open surgery because it involves a restricted surgical field and difficulty in identifying anatomical structures from certain viewpoints. In order to allow surgeons to learn how to perform endoscopic surgery safely, skill-training laboratories and simulation models, for example, box trainers, virtual reality simulations, and animal models, have been developed (3-5). Fresh frozen human cadavers are a useful resource for endoscopic surgical training, as they offer excellent handling fidelity and normal anatomical relationships. Our institution has some facilities that offer training in basic endoscopic skills and simulations that closely match the situations found during clinical surgery.

We evaluated the usefulness of surgical training using fresh frozen human cadavers as a tool for VANS training.

**SUBJECTS AND METHODS**

We (three certified board surgeons of the Japan Surgical Society) performed VANS training using two fresh frozen human cadavers. The cadaver training was undertaken with the approval of our institution's ethics committee and was conducted according to the Guidelines for Cadaver Dissection in Education and Research of Clinical Medicine (Japan Society and Japanese Association of Anatomists).

After the training, we performed VANS in 5 patients. All of the patients were female, and their mean age was 40 (range : 17 to 68). The preoperative diagnosis was adenomatous goiter in 3 cases and follicular tumor in 2 cases. All patients underwent hemi-thyroidectomy. All surgical procedures involved the same procedure as was performed on the cadavers. After the cadaver training and the actual surgery, the three surgeons evaluated each step of the surgical procedure using a 3-point scale (1 : the cadaver training was not useful, 2 : neither 1 nor 3, 3 : the cadaver training was useful).

**SURGICAL PROCEDURE**

Training models were established using fresh human cadavers. The two fresh cadavers, one female and one male, were placed in the supine position. The surgical team consisted of a surgeon, an assistant, and a scopist. The surgeon stood on the affected side, and the assistant and the scopist stood on the other side. A monitor was placed over the head of the cadaver. A 3.0-cm subclavian incision was made for the main operation. A 1-cm incision was made within the boundaries of the original incision, and a 5-mm trocar and a 5-mm, 30° rigid scope (Karl-Storz, Germany) were inserted.

Eight steps evaluated for the surgical procedure are the following.

Received for publication April 9, 2019 ; accepted June 12, 2019.

Address correspondence and reprint requests to Mariko Aoyama, Department of Thoracic, Endocrine Surgery, and Oncology; Institute of Health; Biosciences; The University of Tokushima; 3-18-15; Kuramoto-cho; Tokushima; 770-8509; Japan and Fax : +81-88-633-7144.

1) Creation of a subcutaneous tunnel : Surgical dissection, including the release of connective tissue and the division of blood vessels, was performed using a 20-cm-long THUNDERBEAT (inline grip type ; OLYMPUS, Japan). A subcutaneous tunnel to the anterior neck region was created over the clavicle. The pre-thyroid muscles were exposed. The surface of the thyroid lobe was identified and separated from the muscles. 2) Lifting up the skin flap and pre-thyroid muscles : The skin-muscle flap was lifted up using a Kirschner wire and a suture to create a working space. 3) Separating the thyroid lobe from the pre-thyroid muscle : The lateral surface of the thyroid lobe was exposed, and the middle thyroid vein was cut. 4) Dissecting the superior thyroid pole and blood vessels : Next, the blood vessels of the superior thyroid pole were dissected, and the superior parathyroid gland was identified. 5) Identifying and preserving the recurrent laryngeal nerve : The recurrent laryngeal nerve was identified and preserved. 6) Identifying and preserving the parathyroid glands : We continued towards the inferior pole, and the inferior parathyroid gland was identified. 7) Dissecting the isthmus : The isthmus was separated from the trachea and dissected. 8) Resecting the thyroid lobe from the trachea : The thyroid lobe was removed from the trachea. The released thyroid gland was removed through the 3.0-cm-long incision.

## RESULTS

We performed hemi-thyroidectomy via VANS a total of four times ; i.e., twice in each fresh frozen human cadaver. The scores awarded for each step of the surgical procedure by the three expert surgeons are shown in Table 1. The scores for steps 1 and 2 were higher than those for the other steps. The skin and muscles of the fresh frozen human cadaver models were in almost the same state as those of the clinical patients (Figure 1). The scores for step 5 were also high. In one of the four training procedures, the recurrent laryngeal nerve could not be clearly identified. However, in the rest of the training procedures, it could be identified and preserved (Figure 2). The scores for steps 7 and 8 were lower than those for the other steps. A tracheal injury occurred during the cadaver training.

We performed hemi-thyroidectomy via VANS in 5 patients (Table 2). None of the patients underwent conversion to open surgery. The mean operative time was 159 minutes (120–190 minutes). In all cases, the recurrent laryngeal nerve and parathyroid glands were identified and preserved. No complications were encountered, and the mean duration of the patients' hospital stays was 5 days (4–7 days). And we compared the outcome of surgery between VANS and conventional open surgery at the similar period (Table 3). The mean tumor sizes in the conventional open surgery was bigger than in the VANS. And the mean operation time was shorter than VANS.

Table 1. The scores awarded by the three expert surgeons for each step of the surgical procedure

Steps of the surgical procedure	Surgeon 1	Surgeon 2	Surgeon 3	Total score
1) Creation of a subcutaneous tunnel	3	3	3	9
2) Lifting up the skin flap and the pre-thyroid muscles	3	3	3	9
3) Separating the thyroid lobe from the pre-thyroid muscle	2	2	1	5
4) Dissecting the superior thyroid pole and blood vessels	2	1	2	5
5) Identifying and preserving the recurrent laryngeal nerve	3	2	3	8
6) Identifying and preserving the parathyroid glands	3	1	2	6
7) Dissecting the isthmus	1	1	1	3
8) Resecting the thyroid lobe from the trachea	1	1	1	3

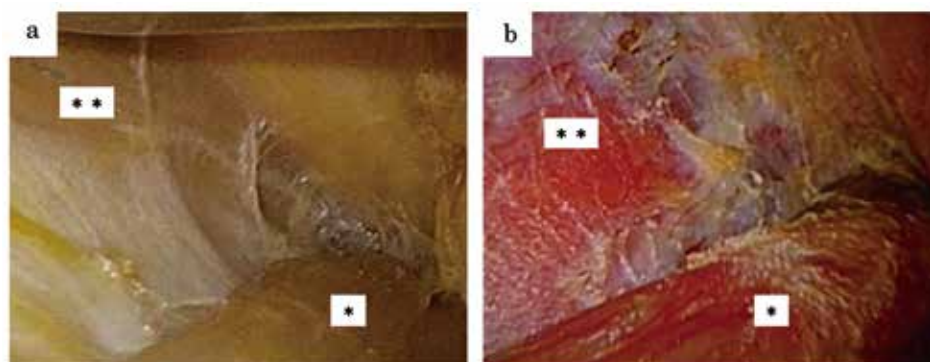


Figure 1. Left hemi-thyroidectomy  
a) Endoscopic view of a fresh frozen cadaver model b) Endoscopic view of a clinical patient  
\* : sternocleidomastoid muscle, \*\* : pre-thyroid muscles

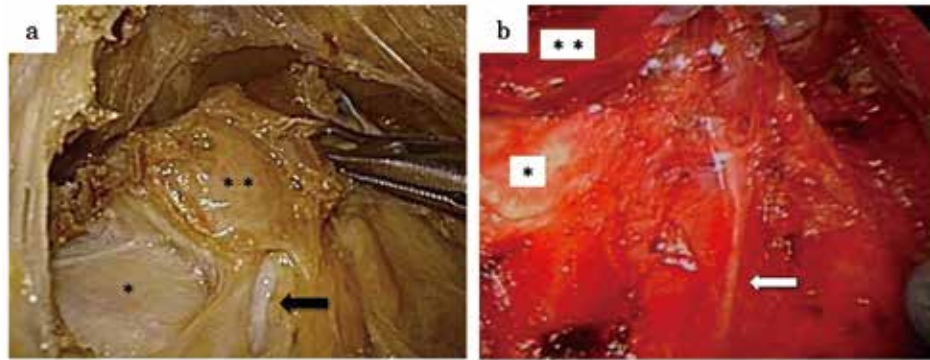


Figure 2. Left hemi-thyroidectomy. The arrow points to the recurrent laryngeal nerve. a) Endoscopic view of a fresh frozen cadaver model b) Endoscopic view of a clinical patient  
\* : trachea, \*\* : left thyroid lobe

Table 2. Five patients in which hemi-thyroidectomy was performed using VANS

Age	Sex	Type	Operative time (minutes)	Bleeding volume (ml)	Hospital stay (days)	Complications
42	Female	Follicular tumor	162	10	4	-
17	Female	Adenomatous goiter	190	5	6	-
68	Female	Adenomatous goiter	120	5	4	-
38	Female	Follicular tumor	162	30	5	-
38	Female	Adenomatous goiter	165	5	7	-

Table 3. The outcome of VANS and conventional open surgery

	VANS(n=5)	Conventional(n=5)
<b>Tumor size(cm)</b>	2.7(2-3)	7.0(4-9)
<b>Operation time(min)</b>	159.8(120-190)	114.2(87-164)
<b>Blood loss(ml)</b>	11(5-30)	16(5-40)
<b>Post operative hospital stay(day)</b>	5.4(4-8)	6.2(4-8)
<b>Complications</b>	0	0

DISCUSSION

Endoscopic surgery requires different skills from conventional surgery, and training programs that allow surgeons to learn such technical skills are needed. Skill-training laboratories and various simulation models have been developed, such as dry box simulators, virtual reality simulators, and animal models (3-10). In Japan, the publication of the “Guidelines for Cadaver Dissection in Education and Research of Clinical Medicine” in 2012 confirmed that surgical training using cadavers is lawful, providing it is conducted under adequate supervision and appropriate rules (3, 6). Therefore, some medical universities have started to perform surgical training using human cadaver models (3). Due to their fidelity and anatomy, human cadavers are a useful resource for surgical training (4, 6-8).

There are various methods that can be used to preserve human cadavers. Compared with cadavers subjected to other preservation methods, such as formalin fixation and Thiel’s method, fresh frozen cadavers exhibit a more life-like color and greater softness and pliability (3). In addition, surgical training using fresh frozen cadavers is more realistic in terms of the proximity of other viscera, tissue compliance, and depth percep-

tion (3). Many studies have used fresh frozen cadavers, and the validity of laparoscopic training using fresh frozen cadavers has been confirmed (5, 8).

VANS for benign thyroid disease and cancer has been covered by the Japanese health insurance system since 2016 and 2018, respectively. We performed VANS training using fresh frozen human cadavers and evaluated its usefulness.

The fresh human cadavers were preserved in a good condition, and their tissues and organs exhibited flexibility and plasticity, especially the skin and muscles. In fact, they were in almost the same state as those of the clinical patients. Therefore, training using cadaver models seemed to be very useful for learning how to perform certain procedures ; i.e., creating a subcutaneous tunnel and lifting up the skin flap and pre-thyroid muscles. A sufficient working space was provided (similar to that found in in vivo conditions) during the cadaver training. The scores for two steps (forming the subcutaneous tunnel and lifting up the flap) were higher than those for the other steps. In the cadaver models, the recurrent laryngeal nerve could be clearly identified, and the tissue around it was preserved in a good condition. Thus, the use of cadavers was useful for training regarding the identification of the anatomical position of the recurrent laryngeal

nerve. It was also useful for confirming the role of surgical staff and simulating the placement of surgical equipment.

In the actual surgical cases, there were no complications, and so simulations using cadaver models might reduce the risk of surgical complications.

However, there are some issues with the use of fresh frozen cadavers. First, the thyroid tissue of cadaver models is denatured compared with that found in clinical patients. The boundary between the thyroid gland and the surrounding tissue is also unclear. Therefore, it is difficult to separate the thyroid from the surrounding organs, such as the pre-thyroid muscles and trachea, and to expose the superior thyroid pole. In the present study, the scores for two steps; i.e., the separation between the thyroid gland and the surrounding tissue and dissecting the superior thyroid pole, were lower than those for the other steps. As cadavers undergo rapid putrefaction after thawing, freezers are required for their storage, and it is necessary to perform the planned training within a limited period (3). In addition, the cost of fresh frozen cadaver model training is higher than training using cadaver models that are preserved using other methods, such as formalin fixation, Thiel's method, or the saturated salt solution method (3). We should consider combining other training methods to reduce costs and ensure that training time is used effectively.

## CONCLUSION

Fresh frozen human cadavers are an excellent tool for surgical training aimed at teaching the VANS technique. Furthermore, such training could be used to introduce new surgical methods safely.

## CONFLICT OF INTERESTS

The authors declare that there is no conflicts of interests regarding the publication of this paper.

## REFERENCES

1. Shimizu K, Akira S, Jasmi AY, Kitamura Y, Kitagawa W, Akasu H, Tanaka S : Endoscopic resection of thyroid tumors with a very minimal neck wound. *J Am Coll Surg* 188 : 697-703, 1999.
2. Shimizu K, Kitagawa W, Akasu H, Tanaka S : Video-assisted endoscopic endocrine neck Surgery with a benefit of cosmesis : A new technique using a totally gasless anterior neck skin lifting method. *J Nippon Med Sch* 69 : 2-3, 2002
3. Hayashi S, Naito M, Kawata S, Qu N, Hatayama N, Hirai S, Itoh M : History and future of human cadaver preservation for surgical training : from formalin to saturated salt solution method. *Anat Sci Int* 91 : 1-7, 2016
4. Gilbody J, Prasthofer AW, Ho K, Costa ML : The use and effectiveness of cadaveric workshops in higher surgical training : a systematic review. *Ann R Coll Engl* 93 : 347-352, 2011
5. Sharma M, Horgan A : Comparison of fresh-frozen cadaver and high-fidelity virtual reality simulator as methods laparoscopic training. *World J Surg* 36 : 1732-1737, 2012
6. Usami T, Fujioka T, Yoshida A, Miyae H, Yasuoka T, Uchikura Y, Takagi K, Matubara Y, Matsumoto K, Sugiyama T : Assessment of laparoscopic training for gynecological malignancies using Thiel-embalmed human cadavers. *Mol Clin Oncol* 9 : 511-514, 2018
7. Imakuma ES, Ussami EY, Meyer A : Laparoscopic training model using fresh human cadavers without the establishment of pneumoperitoneum. *J Minim Access Surg* 12 : 190-193, 2016
8. Sharma M, Macafee D, Pranesh N, Horgan AF : Construct validity of fresh frozen human cadaver as a training model in minimal access surgery. *JSLs* 16 : 345-352, 2012
9. Dure J, Kluka E, Walvekar RR : Minimally invasive video-assisted thyroidectomy for treatment of benign solitary thyroid nodules in pediatric patients. *Ochsner J* 11 : 128-131, 2011
10. Phillips HN, Fiorelli RK, Queiroz MR, Oliveira AL, Zorron R : Single-port unilateral transaxillary totally endoscopic thyroidectomy : A survival animal and cadaver feasibility study. *J Minim Access Surg* 12 : 63-67, 2016