

ORIGINAL**The risk of hemorrhage in stereotactic biopsy for brain tumors**

Yoshifumi Mizobuchi⁽¹⁾, Kohei Nakajima⁽¹⁾, Toshitaka Fujihara⁽¹⁾, Kazuhito Matsuzaki⁽²⁾, Hideo Mure⁽¹⁾, Shinji Nagahiro⁽¹⁾, and Yasushi Takagi⁽¹⁾

⁽¹⁾Department of Neurosurgery, Institute of Biomedical Sciences Tokushima University Graduate School, Tokushima, Japan, ⁽²⁾Department of Neurosurgery, Tokushima Red Cross hospital, Tokushima, Japan

Abstract : Objective : One major complication associated with STB is intratumoral hematoma, which is also the most common cause of morbidity related to permanent paralysis and mortality in STB. The risk of perioperative hemorrhage is generally between 1% and 10%, but this could be an underestimation since it is not common for many neurosurgeons to perform CT scans after uncomplicated STBs. In this study, we describe the incidence of cerebral hemorrhage, including asymptomatic cerebral hemorrhage. **Methods :** We recently reviewed data on the diagnosis rate and occurrence of complications, including symptomatic and asymptomatic cerebral hemorrhage, in 80 patients who underwent STB at our facility between 2005 and 2014. **Results :** Histological diagnosis was established for 75 cases (93.8%), glioma was the most frequently encountered tumor. Symptomatic hemorrhage was observed in two cases (2.6%), with the symptoms subsiding within two days. The morbidity and mortality rate was 0%. However, asymptomatic hemorrhages were observed in 23 cases (28.8%). **Conclusion :** Stereotactic biopsy is a less invasive procedure for obtaining samples of brain tumors for diagnosis. The bleeding of the tissue-resection cavity that includes asymptomatic hemorrhage occurs at a constant rate. It is important to reduce the symptomatic bleeding associated with stereotactic biopsy. *J. Med. Invest.* 66:314-318, August, 2019

Keywords : stereotactic biopsy, silent hemorrhage, intratumoral hematoma

INTRODUCTION

Therapeutic strategies for intracranial mass lesions are most effective when based on histopathological diagnoses, rather than upon clinical and radiographic findings alone(4). When the lesions are strongly suspected to be malignant tumors, direct surgical resection should be considered, because massive tumor excision has a significant positive impact on prognosis and facilitates histopathological analysis (13). Sometimes, direct surgical resection is difficult because of multiple lesions, deep-seated cerebral lesions, and the patient's age or general condition. However, obtaining tissue for analysis is critical for guide therapy and the prevention of unnecessary interventions. Presently, stereotactically guided biopsy is commonly used to obtain samples for the histopathological diagnosis of tumors located in deep or eloquent areas within the brain. Stereotactic biopsy (STB) has reduced the morbidity associated with open cranial surgery and nonstereotactic techniques and has minimized disruption to normally functioning neural structures (1, 5). In fact, computed tomography (CT)/magnetic resonance imaging (MRI)-assisted STB is now routinely used for diagnosis and is considered an accurate and relatively safe procedure. Such neuroimaging-based STB procedures are less invasive, especially for surgically inaccessible lesions and for patients who cannot undergo craniotomy because of their general condition (9, 11, 14, 17, 20). However, the risk of perioperative complications remains, with data from a large meta-analysis revealing a major morbidity rate of 3.5% and a mortality rate of 0.7% (6, 19). In some reports, complication rates have ranged from 6% to 12% and permanent morbidity and mortality from 0% to 6.4% (12). Brain edema, seizure, and

infection have been reported, although the major complication associated with STB was intratumoral hematoma. The risk for perioperative hemorrhage was generally found to range from 1% to 10% (1, 3, 5, 9, 14, 17, 21). However, these results may be an underestimation because it is uncommon for neurosurgeons to obtain routine CT scans after uncomplicated/asymptomatic STBs (2). In several studies, silent hemorrhage following uncomplicated STBs was reported to range from 8% to 53.9% (10).

We have performed STBs using a Leksell system in patients with multifocal, deep-seated cerebral lesions, as well as in elderly patients or patients whose conditions had deteriorated. During these STBs, we inserted a drainage tube into the site of tissue resection after the tissue sample was removed. We use this protocol to prevent morbidity and mortality due to cerebral hemorrhage as a complication by the astringency of extraction cavity and the draining of the bleeding and to enable the identification of the resected site using postoperative CT scan. Upon completion of the biopsy, a CT scan is performed in all cases, regardless of the symptomatic status, to check for complications such as hemorrhages and to confirm the accuracy in targeting the resection site. We recently reviewed data on the diagnosis rate and complications, specifically symptomatic and asymptomatic (silent) cerebral hemorrhage, in 80 patients who underwent STB with the Leksell system at our facility between 2005 and 2014. In this study, we describe the complications and diagnostic benefits of neuroimaging-guided STB.

CLINICAL MATERIAL AND METHODS

A retrospective study was conducted with institutional review board approval from University of Tokushima. Patients were admitted to the Division of Neurosurgery at the Tokushima University hospital between November 2005 and December 2014. Data from 80 patients (44 men and 36 women) with a mean age of 63.3 years (range : 14–86 years), who underwent stereotactic biopsy using a Leksell apparatus and prospective CT scanning

Received for publication May 8, 2018 ; accepted July 1, 2019.

Address correspondence and reprint requests to Yoshifumi Mizobuchi Department of Neurosurgery, Institute of Biomedical Sciences Tokushima University Graduate School Tokushima, 3-18-15, Kuramoto-cho, Tokushima 770-8503, Japan and Fax : +81-88-632-9464.

within hours of their procedure, were analyzed. Their lesions were either multifocal, diffuse, or seated in deep intrinsic cerebral areas, and were considered inaccessible for direct removal. Routine blood tests, including platelet count, prothrombin time (PT), and active partial thrombin time (APTT) were performed for all patients. The following medical conditions were included for statistical analysis: hypertension, history of diabetes, recent aspirin use, and procedures performed under local or general anesthesia.

STEREOTACTIC BIOPSY TECHNIQUE

All biopsies were performed at our institution by three neurosurgeons who were specialized and experienced in performing stereotactic techniques and were certified by the Japan Neurosurgical Society. A Leksell model G stereotactic frame system (AB Elekta Instruments, Stockholm, Sweden) was used, with MRI guidance for stereotactic lesion localization. After placement of the head-frame, all patients underwent MRI with a slice thickness of 1 mm. For biopsy, we usually select one site on a contrast-enhanced lesion, or a lesion with hyperintensity on T2-weighted MR images or fluid attenuated inversion recovery (FLAIR). The patient was put under local or general anesthesia and a burr hole was drilled. The dura was incised in a cruciate fashion, and whenever possible, biopsy trajectories were designed to avoid entrance through a sulcus, cortical artery, venous structure, or ventricle. The pia-arachnoid was coagulated with bipolar forceps, and then an incision was made with a small scalpel. A Sedan type, side-cutting aspiration biopsy needle (outer diameter 2.5 mm) was inserted at the target site, and four tissue samples were obtained from four different directions. After obtaining the tissue samples, portions of the resected tissue were submitted to a pathologist for rapid examination. After the tissue was histologically identified, a silicon drain tube with an outer diameter of 2.5 mm was inserted into the resection cavity with a Kirschner stainless steel wire (inner sheath) and connected to the drainage circuit to stop bleeding through the astriction of the extraction cavity and the draining of the blood (Figure 1 *left*).

All patients underwent postoperative CT scanning immediately to confirm that the sample was from the target site, and to identify complications such as intracranial bleeding (Figure 1 *right*). New hemorrhages were classified by size (maximum intraparenchymal diameter) (Figure 2). The following day, all

patients underwent CT scanning and the drainage tubes were removed without cerebral hemorrhage.

Statistical analysis

In each case, medical charts and laboratory results were reviewed to identify factors that may have increased the risk of post-biopsy intracranial hemorrhage associated with the procedure. Fisher's exact probability test was used to evaluate the relationship between hemorrhagic complications and potential risk factors in a univariate model, using $P = 0.05$ as the threshold of statistical significance. Odds ratios were calculated to estimate the magnitude of risk associated with each significant categorical variable. Factors evaluated included age and sex of patients, platelet count, history of hypertension, diabetes, use of anticoagulant or antiplatelet medications, location of lesion, partial thromboplastin time, historical diagnosis, and procedures under local or general anesthesia. All analyses were conducted using EZR (Saitama Medical Center, Jichi Medical University, Saitama, Japan) (7).

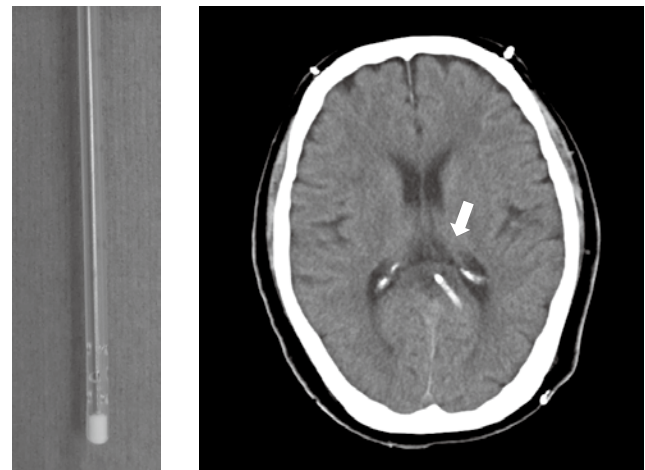


Figure 1. Drainage tube insertion protocols and sample images. A silicon drainage tube with an outer diameter of 2.5 mm was inserted using a Kirschner stainless steel wire (inner sheath) into the resection cavity (*left*). Postoperative computed tomography (CT) can be used to confirm whether the sample was from the target site (*right*).

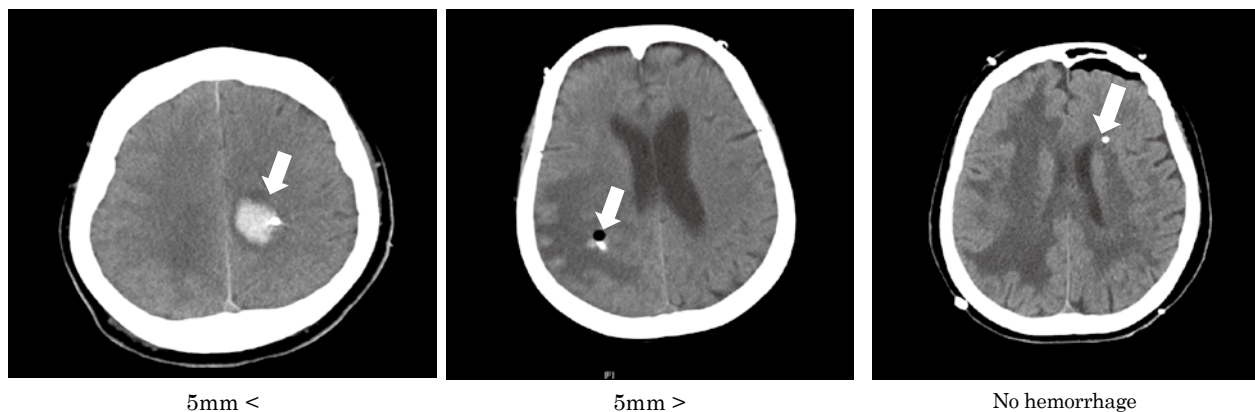


Figure 2. Representative images of stereotactic biopsy-related hemorrhages. Representative computed tomography (CT) images of hemorrhages > 5 mm in size (left panel), hemorrhages < 5 mm (middle panel), and no hemorrhages (right panel).

RESULTS

Patient population

We analyzed data from 80 patients and their clinical data are summarized in Table 1. The age of patients ranged from 14 to 86 years, with a mean age of 63.3 years at biopsy. Forty-four patients (55.0%) were male and 36 patients were female. The mean platelet count was $25.5 (10.9-72.9) \times 10^4 /\mu\text{l}$ and the mean prothrombin time was 11.5 (9.1-31.4) seconds. Pre-existing medical conditions were identified in 35 patients (43.8%), including a history of hypertension (n = 25) and diabetes (n = 10). In six patients, antiplatelet agents had already been administered 48 hours before surgery. Twenty-one patients (26.3%) underwent biopsy under local anesthesia.

Table 1. Prebiopsy characteristics of 80 patients undergoing stereotactic brain biopsy

Characteristic	mean (range)
Age (yrs)	63.3 (14-86)
Sex (% male)	55.0%
Platelet count	$25.5 (10.9-72.9) \times 10^4 /\mu\text{l}$
Prothrombin time (secs)	11.5 (9.1-31.4)
History of hypertension	31.3%
History of diabetes	12.5%
Recent aspirin use	7.5%
Local anesthesia	26.3%

N=80

Target lesion

The stereotactically biopsied sites are summarized in Table 2. Forty cases (50.0%) involved tumors that were localized in the cerebral hemispheres : 20 cases (25%) involved tumors in the frontal lobe, 7 cases (8.8%) involved tumors in the temporal lobe, 7 cases (8.8%) involved tumors in the parietal lobe, and 6 cases (7.5%) involved tumors in the occipital lobe. For forty patients (50.0 %), the lesions were located deep in the brain. Lesions were located in the basal ganglia, corpus callosum, cerebellum, and brain stem.

Table 2. Sites of stereotactic biopsies

Location	No. of cases (%)
Frontal lobe	20 (25.0)
Temporal lobe	7 (8.8)
Parietal lobe	7 (8.8)
Occipital lobe	6 (7.5)
Cerebellum	2 (2.5)
Basal ganglia	30 (37.5)
Brain stem	1 (1.3)
Corpus callosum	7 (8.8)

N=80

HISTOLOGICAL DIAGNOSIS

Histological diagnosis was established for 75 cases (93.8%) following STB. Of the 67 neoplasm cases, 65 were diagnosed as primary brain tumors. Histologically, glioma was encountered frequently (35 patients ; 43.8%), with 24 tumors (30%) determined to be glioblastoma, six (7.5%) determined to be low-

grade glioma, and five (6.3%) diagnosed as anaplastic glioma. Thirty tumors (37.5%) were malignant lymphomas and two (2.5%) were metastatic brain tumors (Table 3).

Table 3. Histological diagnosis

Lesion Type	No. of Patients (%)
Low-grade astrocytoma	6 (7.5)
Anaplastic astrocytoma	5 (6.3)
Glioblastoma multiforme	24 (30.0)
Metastasis	2 (2.5)
Malignant lymphoma	30 (37.5)
Gliosis	2 (2.5)
Inflammatory	5 (6.3)
Demyelination	1 (1.3)
Nondiagnostic	5 (6.3)

N=80

COMPLICATIONS AND INCIDENCE OF HEMORRHAGE ON ROUTINE POSTOPERATIVE CT SCAN

In the present study, no death was attributable to the stereotactic procedure. The only two minor complications associated with STB were transient motor weakness caused by hemorrhage in the tissue-resection cavity and low level of consciousness caused by postoperative hemorrhage (2.6%). In the case involving the low level of consciousness, hydrocephalus, caused by intraventricular hemorrhage, occurred. However, these symptoms were temporary and completely disappeared within 48 hours. The total operative mortality and morbidity rate was 0% upon discharge (Table 4).

Table 4. Complications directly induced by stereotactic brain biopsy

	Minor/Transient	Permanent
Weakness	1 (1.3%)	0
Seizure	0	0
Infection	0	0
Lowering of consciousness	1 (1.3%)	0
Total	2 (2.6%)	0

In the 25 patients (31.3%) in whom hemorrhage was detected on routine postoperative CT scan, intraparenchymal hemorrhages were smaller than 5 mm in diameter in 22 patients (27.5%) and larger than 5 mm in three patients (3.8%). In the 23 patients, there were no hemorrhage-related neurological deficits (i.e., all hemorrhages that occurred were silent hemorrhages) (Table 5).

Table 5. Incidence of hemorrhage on routine postoperative computed tomography scans in 80 patients who underwent stereotactic brain biopsy

	No. of Patients (%)	
	All Hemorrhages	Asymptomatic hemorrhages
< 5 mm	22 (27.5)	22 (27.5)
> 5 mm	3 (3.8)	1 (1.3)
total	25 (31.3)	23 (28.8)

RISK FACTORS INFLUENCING HEMORRHAGE

The results following univariate analysis of the risk of post-biopsy hemorrhage revealed a significant correlation with the degree to which the prothrombin time was longer than 12.7 seconds ($P = 0.014$). These patients had a 7.43-fold risk of cerebral hemorrhage including asymptomatic hemorrhage compared to those with a normal prothrombin time. On the other hand, patients with malignant glioma had a 0.37-fold reduced risk of hemorrhage ($P = 0.049$). Variables which were not significantly correlated with risk include age and sex of patients, platelet count (< 150000), history of hypertension, history of diabetes, use of anticoagulant or antiplatelet medications, location of lesion, patients with malignant lymphoma, and procedures performed under local anesthesia or general anesthesia (Table 6).

Table 6. Risk factors that influence hemorrhage

Risk Factor	Hemorrhage Gr	No hemorrhage Gr	ODDs Ratio	P-Value
Age (70 <)	11/32	21/32	1.15	0.811
Gender (male)	16/44	28/44	1.48	0.477
PLT (< 150)	2/5	3/5	0.72	1.0
Hypertension	5/25	20/25	0.41	0.129
Diabetes	3/10	7/10	0.877	1.0
Antiplatelet agents	4/7	3/7	3.04	0.206
Deep-seated lesion	14/38	24/38	0.69	0.48
PT > 12.7s	6/8	2/8	7.43	0.014
Malignant glioma	14/30	16/30	0.37	0.049
Malignant lymphoma	7/30	23/30	2.00	0.221
Local Anesthesia	5/21	16/21	0.57	0.42

Abbreviations : PLT, platelet count ; PT, prothrombin time

DISCUSSION

As specified above, we analyzed data from 80 patients who underwent STBs using the Leksell system, with insertion of a drainage tube according to our standard protocol. Many of these patients were at an advanced age, and the resected tissues were histologically diagnosed as lymphoma in many cases (37.5%). In a study by Franzini *et al.*, 100 out of 940 patients had multiple lesions, which comprised malignant gliomas (37%), primary lymphomas (15%), brain metastases (15%), and low-grade gliomas (12%) (3). The prevalence of malignant lymphomas in our study is higher than that in the study by Franzini *et al.*, possibly because our patient population comprised patients with multiple or deep lesions, systemic conditions and therefore cannot undergo tumor resection by open craniotomy, and advanced age.

The pathological diagnosis rate using tissue samples acquired using the Leksell system in our institute is 93.8%, which is comparable to the values reported in the literature. However, with brain tumor biopsy, only part of the entire tumor can be collected. Particularly, in cases involving heterogeneous tumors such as gliomas, the site of resection does not always represent the tumoral region of high malignancy (15). To improve the precision of resection and sampling, and thus the diagnostic accuracy, it may be useful to identify an area with relatively high malignancy by performing 11 C-methionine positron emission tomography

(met-PET) or thallium scintigraphy. With the precision provided by the Leksell system, it is quite possible to target the high-density areas visualized using met-PET or thallium scintigraphy. Alternatively, diagnostic accuracy could be improved by setting multiple targets or collecting multiple tissue specimens, though this is viewed negatively by many investigators because of its increased risk of biopsy-related hemorrhage. At our facility, we select a single target and collect four tissue samples from the targeted area.

The incidence of complications has been reported to range from 6% to 12% after STB, consisting mostly of reports of intracranial symptomatic hemorrhage. Malone *et al.* reported that patients with intracranial hemorrhage were significantly more likely to die in the hospital or experience a non-routine discharge. These patients have an in-hospital mortality rate that is six-fold higher than that for patients without hemorrhage (12). In this study, the mortality and morbidity rate, including infection and postoperative convulsions, was 0% excluding two cases (2.6%), but the symptoms subsided within two days. In the literature, the risk of perioperative hemorrhage ranges from 1% to 10% (1, 3, 5, 9, 14, 17, 21). However, these results do not include asymptomatic hemorrhage. Asymptomatic hemorrhage was observed in 23 cases (28.8 %) at our facility. The incidence of asymptomatic hemorrhage has been reported in other studies to range from 8% to 53.9% (10, 15, 2). There is no generally accepted standard for postoperative management, monitoring, and surveillance of patients. Postoperative CT scans are not performed at many facilities if no symptoms are observed after biopsy. The studies reported in the literature include studies in which a CT scan was performed only in cases where symptoms were observed after biopsy. Thus, the incidence of hemorrhage reported in the literature is effectively that of symptomatic hemorrhage only, whereas the true incidence of hemorrhage (including asymptomatic hemorrhage) after biopsy may be higher than previously reported due to cases of asymptomatic hemorrhage.

The present study revealed a correlation between postoperative hemorrhage (including asymptomatic hemorrhage) and prothrombin time. It is therefore advisable to consider this relationship when biopsy is performed. On the other hand, patients with malignant glioma in our study were at a modestly reduced risk for hemorrhage. This is in accordance with the results of Malone *et al.* (12). However, several authors have reported that gliomas of the basal ganglia and thalamus are risk factors for morbidity in a frame-based stereotactic biopsy (8, 14, 16, 18). Therefore, such an intervention should be performed in glioma patients only following careful preparation and consideration of the target site. Our study suggests that the surgical risk is not greater for lesions that are located in deep brain areas, although this is contrary to the reports of other studies (1, 5, 14, 19).

In order to perform safe biopsies, it is important to avoid symptomatic hemorrhage. Therefore, careful planning should be enforced. In the literature, Nishihara *et al.* emphasized the importance of the selected trajectory for the biopsy. They suggested that biopsies should be performed in such a way as to avoid the sulci and associated blood vessels, as well as the pyramidal tract, if it is near the target.

CONCLUSION

Neurosurgeons can be presented with serious problems in cases of multiple cerebral lesions, advanced age, or deep-seated lesions. Intracranial hemorrhage is the most common cause of morbidity related to permanent paralysis and mortality in stereotactic biopsy. However, intracranial symptomatic hemorrhage caused by STBs are rare. Stereotactic biopsy is a less invasive

procedure compared to open craniotomy. However, it can still be used to obtain the samples of brain tumors needed for diagnosis.

DISCLOSURES

We neither have any sources of financial support to disclose, nor do we have any potential conflicts of interest.

FUNDING

No funding was provided for this study.

REFERENCES

- Dammers R, Haitsma IK, Schouten JW, Kros JM, Avezaat CJ, Vincent AJ : Safety and efficacy of frameless and frame-based intracranial biopsy techniques. *Acta Neurochir (Wien)* 150 : 23-29, 2008
- Eibach S, Weise L, Setzer M, Seifert V, Senft C : Intraoperative bleeding in stereotactic biopsies and its implication on postoperative management : can we predict CT findings? *Stereotact Funct Neurosurg* 92 : 80-85, 2014
- Franzini A, Leocata F, Giorgi C, Allegranza A, Servello D, Broggi G : Role of stereotactic biopsy in multifocal brain lesions : considerations on 100 consecutive cases. *J Neurol Neurosurg Psychiatry* 57 : 957-960, 1994
- Friedman WA, Sceats DJ, Jr., Nestok BR, Ballinger WE, Jr. : The incidence of unexpected pathological findings in an image-guided biopsy series : a review of 100 consecutive cases. *Neurosurgery* 25 : 180-184, 1989
- Grossman R, Sadetzki S, Spiegelmann R, Ram Z : Haemorrhagic complications and the incidence of asymptomatic bleeding associated with stereotactic brain biopsies. *Acta Neurochir (Wien)* 147 : 627-631 ; discussion 631, 2005
- Hall WA : The safety and efficacy of stereotactic biopsy for intracranial lesions. *Cancer* 82 : 1749-1755, 1998
- Kanda Y : Investigation of the freely available easy-to-use software 'EZ' for medical statistics. *Bone Marrow Transplant* 48 : 452-458, 2013
- Kongkham PN, Knifed E, Tamber MS, Bernstein M : Complications in 622 cases of frame-based stereotactic biopsy, a decreasing procedure. *Can J Neurol Sci* 35 : 79-84, 2008
- Kreth FW, Muacevic A, Medele R, Bise K, Meyer T, Reulen HJ : The risk of haemorrhage after image guided stereotactic biopsy of intra-axial brain tumours--a prospective study. *Acta Neurochir (Wien)* 143 : 539-545 ; discussion 545-536, 2001
- Kulkarni AV, Guha A, Lozano A, Bernstein M : Incidence of silent hemorrhage and delayed deterioration after stereotactic brain biopsy. *J Neurosurg* 89 : 31-35, 1998
- Livermore LJ, Ma R, Bojanic S, Pereira EA : Yield and complications of frame-based and frameless stereotactic brain biopsy--the value of intra-operative histological analysis. *Br J Neurosurg* 28 : 637-644, 2014
- Malone H, Yang J, Hershman DL, Wright JD, Bruce JN, Neugut AI : Complications Following Stereotactic Needle Biopsy of Intracranial Tumors. *World Neurosurg* 84 : 1084-1089, 2015
- Marko NF, Weil RJ, Schroeder JL, Lang FF, Suki D, Sawaya RE : Extent of resection of glioblastoma revisited : personalized survival modeling facilitates more accurate survival prediction and supports a maximum-safe-resection approach to surgery. *J Clin Oncol* 32 : 774-782, 2014
- McGirt MJ, Woodworth GF, Coon AL, Frazier JM, Amundson E, Garonzik I, et al. : Independent predictors of morbidity after image-guided stereotactic brain biopsy : a risk assessment of 270 cases. *J Neurosurg* 102 : 897-901, 2005
- Reithmeier T, Lopez WO, Doostkam S, Machein MR, Pinsker MO, Trippel M, et al. : Intraindividual comparison of histopathological diagnosis obtained by stereotactic serial biopsy to open surgical resection specimen in patients with intracranial tumours. *Clin Neurol Neurosurg* 115 : 1955-1960, 2013
- Sawin PD, Hitchon PW, Follett KA, Torner JC : Computed imaging-assisted stereotactic brain biopsy : a risk analysis of 225 consecutive cases. *Surg Neurol* 49 : 640-649, 1998
- Smith JS, Quinones-Hinojosa A, Barbaro NM, McDermott MW : Frame-based stereotactic biopsy remains an important diagnostic tool with distinct advantages over frameless stereotactic biopsy. *J Neurooncol* 73 : 173-179, 2005
- Soo TM, Bernstein M, Provias J, Tasker R, Lozano A, Guha A : Failed stereotactic biopsy in a series of 518 cases. *Stereotact Funct Neurosurg* 64 : 183-196, 1995
- Steiner C, Elixhauser A, Schnaier J : The healthcare cost and utilization project : an overview. *Eff Clin Pract* 5 : 143-151, 2002
- Tilgner J, Herr M, Ostertag C, Volk B : Validation of intraoperative diagnoses using smear preparations from stereotactic brain biopsies : intraoperative versus final diagnosis--influence of clinical factors. *Neurosurgery* 56 : 257-265 ; discussion 257-265, 2005
- Woodworth G, McGirt MJ, Samdani A, Garonzik I, Olivi A, Weingart JD : Accuracy of frameless and frame-based image-guided stereotactic brain biopsy in the diagnosis of glioma : comparison of biopsy and open resection specimen. *Neurol Res* 27 : 358-362, 2005