

CASE REPORT

Acute hypercalcemia and hypervitaminosis D associated with pulmonary tuberculosis in an elderly patient : A case report and review of the literature.

Toshihiro Wada¹, Masaki Hanibuchi², and Atsuro Saijo²

¹Department of Internal Medicine, ²Department of Respiratory Medicine, Shikoku Central Hospital of the Mutual Aid Association of Public School teachers, 2233 Kawanae-cho, Shikoku-Chuo, 799-0193, Japan

Abstract : An 80-year-old man was referred to our hospital for further examination of fever, cough and left pleural effusion. The laboratory findings showed acute inflammation, and the elevation of albumin-corrected serum calcium and 1,25-dihydroxyvitamin D₃. A chest CT revealed centrilobular particulate opacity in the bilateral lung fields and left pleural effusion, indicating acute hypercalcemia and hypervitaminosis D associated with pulmonary tuberculosis. By the confirmation of *Mycobacterium tuberculosis* on polymerase chain reaction and cultures of the sputum and pleural effusion, a diagnosis of pulmonary tuberculosis was made. The patient successfully completed a 9-month course of the anti-tuberculosis treatment, and bilateral infiltrative shadows and left pleural effusion in chest X-ray disappeared. Symptoms progressively improved and serum level of albumin-corrected calcium and 1,25-dihydroxyvitamin D₃ eventually normalized. While pulmonary tuberculosis is an infrequent cause of hypercalcemia, it should be considered in patients with hypercalcemia and elevated serum level of 1,25-dihydroxyvitamin D₃. *J. Med. Invest.* 66:351-354, August, 2019

Keywords : pulmonary tuberculosis, hypercalcemia, 1,25-dihydroxyvitamin D₃

INTRODUCTION

The most important causes of hypercalcemia in the elderly are hyperparathyroidism, malignant disease and prolonged immobilization. Medications, such as thiazide diuretics and lithium, as well as excessive supplementation with calcium/vitamin D, may precipitate hypercalcemia (1). Granulomatous disorders, such as sarcoidosis and tuberculosis, can also potentially present with hypercalcemia. Although hypercalcemia is known to be associated with pulmonary tuberculosis, it is relatively uncommon (2, 3). We herein report an elderly case of pulmonary tuberculosis with hypercalcemia and hypervitaminosis D. In the present report, we highlight pulmonary tuberculosis as a potential cause of hypercalcemia and hypervitaminosis D, as well as discuss the prevalence and the putative mechanisms of tuberculous hypercalcemia through the review of the literature.

CASE REPORT

An 80-year-old man was referred to our hospital for further examination of left pleural effusion. On admission, low grade fever and productive cough had persisted for approximately nine months. His medical history included hypertension, vibration disease and fracture of left clavicle. No significant social or family history was reported. His body temperature was 36.7 °C, a blood pressure of 110/74 mmHg, a pulse of 60 beats per minute and an oxygen saturation of 97% on room air. There were no evident cervical, supraclavicular and axillar lymphadenopathies. The

cardiovascular examination was unremarkable. Respiratory sounds were decreased in the left lower lung field. The remainder of the physical examination was normal. The laboratory findings on admission indicate acute inflammation (white blood cell count 6500/μL, C-reactive protein 4.35 mg/dL) and renal dysfunction (urea nitrogen 27.8 mg/dL, creatinine 2.94 mg/dL). The albumin-corrected serum calcium (corrected Ca) and 1,25-dihydroxyvitamin D₃ (1,25-(OH)₂D₃) were elevated at 12.4 mg/dL and 151.0 pg/mL, respectively, but intact parathyroid hormone (PTH), PTH-related protein and angiotensin converting enzyme were within normal range. The remainder of laboratory test results is shown in Table 1. A chest X-ray demonstrated bilateral infiltrative shadows and left massive pleural effusion (Fig. 1A). A chest CT revealed centrilobular particulate opacities and consolidations in the bilateral lung fields and left massive pleural effusion (Fig. 1B). Several differential diagnoses were considered at this juncture. In our patient, there was neither a reported history of excessive calcium/vitamin D intake nor consumption of thiazides. Laboratory tests and systemic radiological scans excluded any malignancies and endocrinopathies. In view of the radiological findings, a diagnosis of hypercalcemia and hypervitaminosis D secondary to pulmonary tuberculosis was formulated. By the confirmation of *Mycobacterium tuberculosis* on polymerase chain reaction and cultures of the sputum and pleural effusion, a diagnosis of pulmonary tuberculosis (bIII2, IPI; The classification of The Japanese Society for Tuberculosis) was made. The isolated strain was susceptible to all anti-tuberculosis drugs. Immediately after diagnosis, the patient received an anti-tuberculosis treatment comprising daily dosing

Abbreviations

corrected Ca, albumin-corrected calcium ; 1,25-(OH)₂D₃, 1,25-dihydroxyvitamin D₃ ; PTH, parathyroid hormone ; INH, isoniazid ; RFP, rifampicin ; EB, ethambutol ; IFN-γ, interferon gamma

Received for publication April 26, 2019 ; accepted June 9, 2019.

Address correspondence and reprint requests to Masaki Hanibuchi, Department of Respiratory Medicine, Shikoku Central Hospital of the Mutual Aid Association of Public School teachers, 2233 Kawanae-cho, Shikoku-Chuo, 799-0193, Japan and Fax : +81-896-58-3464.

Table 1. Laboratory data on admission

Hematology		Na	136 mEq/L	PR3-ANCA	< 1.0 U/mL
WBC	6,500 / μ L	K	4.4 mEq/L	MPO-ANCA	< 1.0 U/mL
Neu	80.9 %	Cl	410 mEq/L	Urinalysis	
Lymph	9.8 %	Ca	11.6 mg/dL	pH	6.5
Mono	7.6 %	P	4.1 mg/dL	specific gravity	1.009
Eos	1.1 %	CRP	4.35 mg/dL	Sugar	–
Baso	0.6 %	HbA1c (NGSP)	5.9 %	Occult blood	±
RBC	368 \times 10 ⁴ / μ L	BS	129 mg/dL	Protein	–
Hb	10.3 g/dL	1,25(OH) ₂ D ₃	151 pg/mL	Sediment	W.N.L.
Ht	30.8 %	intact PTH	7 pg/mL	Analysis for acid-fast bacilli	
Plt	43.2 \times 10 ⁴ / μ L	PTHrP	< 1.0 pmol/L	Sputum	
Biochemistry		ACE	3.1 IU/L	Smear	–
AST	48 IU/L	KL-6	404 U/mL	Culture	+
ALT	44 IU/L	β -D-glucan	< 5.0 pg/mL	TB-PCR	+
ALP	214 IU/L	Immunology		MAC-PCR	–
LDH	299 IU/L	IgG	1,177 mg/dL	Pleural effusion	
γ -GTP	24 IU/L	IgA	334 mg/dL	Smear	–
T-bil	0.59 mg/dL	IgM	79 mg/dL	Culture	+
CK	261 U/L	C3	113 mg/dL	TB-PCR	+
TP	6.5 g/dL	C4	38 mg/dL	MAC-PCR	–
Alb	3.2 g/dL	CH50	45.8 U/mL		
BUN	27.8 mg/dL	anti-nuclear antibody	< 40		
Cre	2.94 mg/dL				

ACE, angiotensin-converting enzyme ; KL-6, krebs von den lungen-6 ; ANCA, antineutrophil cytoplasmic antibody ; TB, tuberculosis ; MAC, Mycobacterium-avium complex

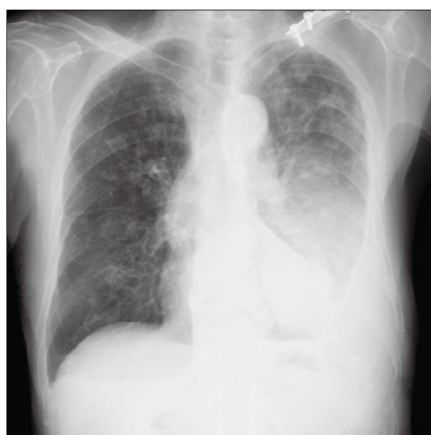

Figure 1A

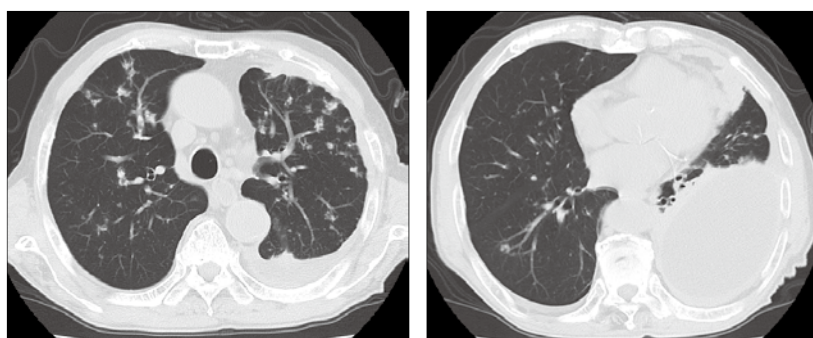


Figure 1B

Figure 1. Chest X-ray and Chest CT on admission. Bilateral infiltrative shadows and left massive pleural effusion were evident in chest X-ray (Figure 1A). A chest CT revealed centrilobular particulate opacities and consolidations in the bilateral lung fields and left massive pleural effusion (Figure 1B).

of isoniazid (INH) 300 mg and rifampicin (RFP) 450 mg, and alternate-day administration of ethambutol (EB) 750 mg for two months followed by daily dosing of INH and RFP for seven months. The dose of EB was adjusted according to the degree of renal dysfunction. In terms of treatment for hypercalcemia, intravenous saline was also administered. After receiving these treatments, the patient's symptoms progressively improved

and serum level of corrected Ca and 1,25-(OH)₂D₃ eventually normalized at 9.0 mg/dL and 29.6 pg/mL, respectively. Finally, the patient successfully completed a 9-month course of the anti-tuberculosis treatment, and bilateral infiltrative shadows and pleural effusion in chest X-ray and chest CT disappeared (Fig. 2A, B).

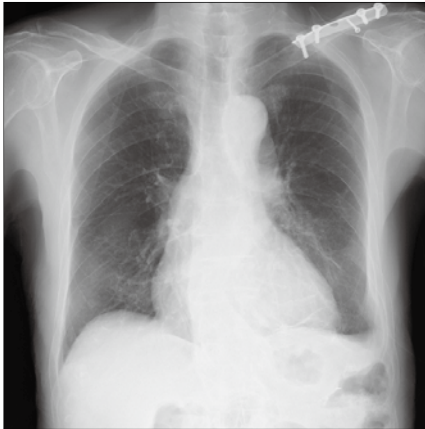


Figure 2A

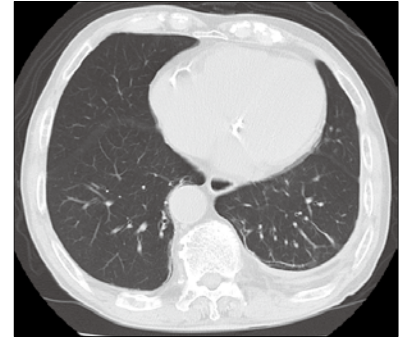
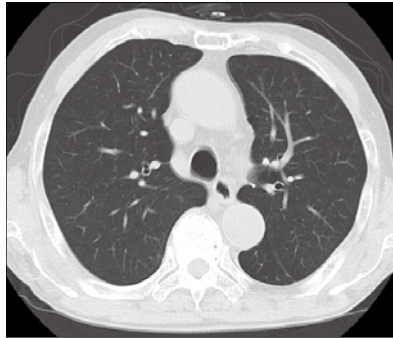


Figure 2B

Figure 2. Chest X-ray and Chest CT after a 9-month course of the anti-tuberculosis treatment. Bilateral infiltrative shadows and left pleural effusion disappeared in both chest X-ray (Figure 2A) and chest CT (Figure 2B).

DISCUSSION

The present case reminds us of the importance of pulmonary tuberculosis as a cause of hypercalcemia especially in elderly patients. While pulmonary tuberculosis is an infrequent cause of hypercalcemia (4), it should be considered in patients with hypercalcemia and elevated serum level of $1,25\text{-(OH)}_2\text{D}_3$. Whenever pulmonary tuberculosis is suspected, timely diagnosis and treatment are mandatory.

Main causes of hypercalcemia include primary hyperparathyroidism, malignancies, drugs and granulomatous diseases, although relative frequency is different between various regions (5). Primary hyperparathyroidism is the most frequent cause, but cancer and drugs have been recently identified as the causes with increased frequency, especially in elderly patients because of the greater risk for malignancy and increased use of vitamin D supplements. However, following these three major causes of hypercalcemia, granulomatous diseases remain important causes for hypercalcemia and these include sarcoidosis, histoplasmosis, coccidioidomycosis and candidiasis in addition to tuberculosis. Finally, other rare causes include hyperthyroidism. Investigations for causes of hypercalcemia include detailed history-taking, physical examination and logical use of laboratory tests. The use of vitamin D or calcium should be sought and physical examination should be performed for looking for a clue suggestive of possible malignancy or granulomatous diseases.

The prevalence of hypercalcemia in patients with tuberculosis is quite variable between countries, varying from approximately 2.3% in some studies (3) to 14.7-50.6% in other studies (6-14) (Table 2). This variation has been largely attributed to disparity in vitamin D and calcium intake, the degree of sunlight exposure as well as the criteria for the diagnosis for hypercalcemia (4). Generally, studies using the albumin-adjusted serum calcium concentration have reported higher prevalence rates compared with patients who did not use correction (7, 9). In the elderly patient with tuberculosis, the frequency of hypercalcemia has not been well documented. Although clinically significant hypercalcemia from tuberculosis is relatively uncommon, the elderly patient seems to be particularly susceptible, given their advanced age, comorbidities, polypharmacy as well as the frequent use of calcium/vitamin D supplements. In the present case, serum level of corrected Ca and $1,25\text{-(OH)}_2\text{D}_3$ eventually normalized with a continued treatment of tuberculosis, as reported previously (1). Although hypercalcemia associated with pulmonary tuberculosis is relatively uncommon and is rarely symptomatic, prompt diagnosis and appropriate treatment is very important.

The mechanism of tuberculous hypercalcemia remains unclear, but has been largely attributed to vitamin D dysregulation. Patients presenting with tuberculosis tend to have lower levels of vitamin D than healthy individuals (15). In patients with tuberculosis, extrarenal synthesis of active vitamin D, $1,25\text{-(OH)}_2\text{D}_3$, occurs via $1\text{-}\alpha$ -hydroxylase produced by interferon

Table 2. Summary of the prevalence of hypercalcemia in pulmonary tuberculosis

Author	Year	Country	N	Prevalence	Methodology*	Reference No.
Abbasi AA	1979	U.S.A.	79	27.8%	Ionized calcium	6
Need AG	1980	Australia	89	50.6%	Albumin-adjusted calcium	7
Sharma SC	1981	India	94	15.5%	Ionized calcium	8
Kitrou MP	1983	Greece	50	48.0%	Albumin-adjusted calcium	9
Lind L	1990	Sweden	67	25.4%	Ionized calcium	10
Tan TT	1993	Malaysia	43	2.3%	Ionized calcium	3
Chan TY	1994	China	34	5.9%	Ionized calcium	11
Chan TY	1994	China	34	14.7%	Albumin-adjusted calcium	11
Liam CK	1998	Malaysia	120	27.5%	Albumin-adjusted calcium	12
Roussos A	2001	Greece	88	25.0%	Albumin-adjusted calcium	13
Dosumu EA	2006	Nigeria	120	27.5%	Albumin-adjusted calcium	14

*Methodology for the diagnosis of hypercalcemia

gamma (IFN- γ)-activated T lymphocytes and alveolar macrophages (16, 17), which results in increased enteric absorption of calcium. *In vitro*, vitamin D promotes mycobacterial killing in macrophages through production of nitric oxide (18), as well as the antimicrobial peptide cathelicidin LL-37, after activation of macrophages via either Toll-like receptor or IFN- γ release (19, 20), and by inducing phagolysosome fusion and autophagy (20, 21). These effects have been shown to be local (22) and does not normally affect overall calcium homeostasis. In addition, 1,25-(OH) $_2$ D $_3$ induces 24-(OH) hydroxylase expression, which deactivates 1,25-(OH) $_2$ D $_3$ to calcitric acid. However, it is believed that if large quantities of 1,25-(OH) $_2$ D $_3$ are produced, a 'spillover' effect may occur in the circulation and potentially result in hypercalcemia (23). It should be also kept in mind that RFP and INH may alter concentrations of serum 25-hydroxyvitamin D $_3$ and 1,25-(OH) $_2$ D $_3$ and thereby reduce the degree of hypercalcemia. RFP induces several enzymes (CYP3A4, CYP2A1, and uridine 5'-diphospho-glucuronyltransferases) that degrade 25-hydroxyvitamin D $_3$ and, by reducing substrate, reduce 1,25-(OH) $_2$ D $_3$ concentrations (24). In contrast, INH inhibits 1,25-(OH) $_2$ D $_3$ synthesis (13). Further study is warranted to elucidate the appropriate mechanism of tuberculous hypercalcemia.

In conclusion, we herein report a case of pulmonary tuberculosis with hypercalcemia and hypervitaminosis D and discuss the prevalence and the putative mechanisms of tuberculous hypercalcemia through the review of the literature. While pulmonary tuberculosis is an infrequent cause of hypercalcemia, it should be considered in patients with hypercalcemia and elevated serum level of 1,25-(OH) $_2$ D $_3$ especially in the elderly.

CONFLICT OF INTEREST DISCLOSURE

The authors have stated that we have no conflicts of interest.

REFERENCES

- Chan JY, Kanthaya M : Hypercalcaemic crisis in an elderly patient with pulmonary tuberculosis. *Oxf Med Case Reports* 2015 : 354-357, 2015
- Shek CC, Natkunam A, Tsang V, Cockram CS, Swaminathan R : Incidence, causes and mechanism of hypercalcaemia in a hospital population in Hong Kong. *Q J Med* 77 : 1277-1285, 1990
- Tan TT, Lee BC, Khalid BA : Low incidence of hypercalcaemia in tuberculosis in Malaysia. *J Trop Med Hyg* 96 : 349-351, 1993
- Chan TY : Differences in vitamin D status and calcium intake : possible explanations for the regional variations in the prevalence of hypercalcemia in tuberculosis. *Calcif Tissue Int* 60 : 91-93, 1997
- Tokuda Y, Maezato K, Stein GH : The causes of hypercalcemia in Okinawan patients : an international comparison. *Intern Med* 46 : 23-28, 2007
- Abbasi AA, Chemplavil JK, Farah S, Muller BF, Arnstein AR : Hypercalcemia in active pulmonary tuberculosis. *Ann Intern Med* 90 : 324-328, 1979
- Need AG, Phillips PJ, Chiu FTS, Prisk HM : Hypercalcaemia associated with tuberculosis. *Br Med J* 280 : 831, 1980
- Sharma SC : Serum calcium in pulmonary tuberculosis. *Post-Grad Med J* 57 : 694-696, 1981
- Kitrou MP, Phytou-Pallikari A, Tzannes SE, Virvidakis K, Mountokalakis TD : Serum calcium during chemotherapy for active pulmonary tuberculosis. *Eur J Respir Dis* 64 : 347-354, 1983
- Lind L, Ljunghall S : Hypercalcemia in pulmonary tuberculosis. *Ups J Med Sci* 95 : 157-160, 1990
- Chan TY, Chan CH, Shek CC : The prevalence of hypercalcaemia in pulmonary and miliary tuberculosis-a longitudinal study. *Singapore Med J* 35 : 613-615, 1994
- Liam CK, Lim KH, Srinivas P, Poi PJ : Hypercalcaemia in patients with newly diagnosed tuberculosis in Malaysia. *Int J Tuberc Lung Dis* 2 : 818-823, 1998
- Roussos A, Lagogianni I, Gonis A, Ilias I, Kazi D, Patsopoulos D, Philippou N : Hypercalcaemia in Greek patients with tuberculosis before the initiation of anti-tuberculosis treatment. *Respir Med* 95 : 187-190, 2001
- Dosumu EA, Momoh JA : Hypercalcemia in patients with newly diagnosed tuberculosis in Abuja, Nigeria. *Can Respir J* 13 : 83-87, 2006
- Nnoaham KE, Clarke A : Low serum vitamin D levels and tuberculosis : a systematic review and meta-analysis. *Int J Epidemiol* 37 : 113-119, 2008
- Gkonos PJ, London R, Hendler ED : Hypercalcaemia and elevated 1,25-dihydroxyvitamin D levels in a patient with end-stage renal disease and active tuberculosis. *N Engl J Med* 311 : 1683-1685, 1984
- Cadranel J, Garabedian M, Milleron B, Guillozo H, Akoun G, Hance AJ : 1,25(OH) $_2$ D $_3$ production by T lymphocytes and alveolar macrophages recovered by lavage from normocalcemic patients with tuberculosis. *J Clin Invest* 85 : 1588-1593, 1990
- Scanga CA, Mohan VP, Tanaka K, Alland D, Flynn JL, Chan J : The inducible nitric oxide synthase locus confers protection against aerogenic challenge of both clinical and laboratory strains of *Mycobacterium tuberculosis* in mice. *Infect Immun* 69 : 7711-7717, 2001
- Liu PT, Stenger S, Li H, Wenzel L, Tan BH, Krutzik SR, Ochoa MT, Schaubert J, Wu K, Meinken C, Kamen DL, Wagner M, Bals R, Steinmeyer A, Zügel U, Gallo RL, Eisenberg D, Hewison M, Hollis BW, Adams JS, Bloom BR, Modlin RL : Toll-like receptor triggering of a vitamin D-mediated human antimicrobial response. *Science* 311 : 1770-1773, 2006
- Fabri M, Stenger S, Shin DM, Yuk JM, Liu PT, Realegeno S, Lee HM, Krutzik SR, Schenk M, Sieling PA, Teles R, Montoya D, Iyer SS, Bruns H, Lewinsohn DM, Hollis BW, Hewison M, Adams JS, Steinmeyer A, Zügel U, Cheng G, Jo EK, Bloom BR, Modlin RL : Vitamin D is required for IFN-gamma-mediated antimicrobial activity of human macrophages. *Sci Transl Med* 3 : 104ra102, 2011
- Hmama Z, Sendide K, Talal A, Garcia R, Dobos K, Reiner NE : Quantitative analysis of phagolysosome fusion in intact cells : inhibition by mycobacterial lipoarabinomannan and rescue by an 1 α , 25-dihydroxyvitamin D $_3$ -phosphoinositide 3-kinase pathway. *J Cell Sci* 117 : 2131-2140, 2004
- Rahman S, Rehn A, Rahman J, Andersson J, Svensson M, Brighenti S : Pulmonary tuberculosis patients with a vitamin D deficiency demonstrate low local expression of the antimicrobial peptide LL-37 but enhanced FoxP3+ regulatory T cells and IgG-secreting cells. *Clin Immunol* 156 : 85-97, 2015
- Cadranel JL, Garabédian M, Milleron B, Guillozzo H, Valeyre D, Paillard F, Akoun G, Hance AJ : Vitamin D metabolism by alveolar immune cells in tuberculosis : correlation with calcium metabolism and clinical manifestations. *Eur Respir J* 7 : 1103-1110, 1994
- Tebben PJ, Singh RJ, Kumar R : Vitamin D-mediated hypercalcemia : mechanisms, diagnosis, and treatment. *Endocr Rev* 37 : 521-547, 2016