

ORIGINAL**Trans-abdominal Pre-peritoneal (TAPP) Inguinal Hernia Repair with Liquid-injection and Gauze Dissection**

Hideya Kashihara, Mitsuo Shimada, Kozo Yoshikawa, Tomohiko Miyatani, Takuya Tokunaga, Masaaki Nishi, Chie Takasu, and Toshiaki Yoshimoto

Department of Surgery, Tokushima university, 3-18-15 Kuramoto-cho, Tokushima 770-8503, Japan

Abstract : *Purpose :* This report describes a novel technique for trans-abdominal pre-peritoneal (TAPP) inguinal hernia repair using liquid injection and gauze dissection. *Methods :* Twenty-five cases underwent TAPP inguinal hernia repair with liquid-injection and gauze dissection. Before the initial peritoneal incision, liquid injection was performed percutaneously into the pre-peritoneal space at the outside of the internal inguinal ring and the inside of the seminal duct. Especially, at the inside of the seminal duct, the liquid was injected into the space between the superficial and deep lobe of pre-peritoneal fascia. Gauze was effectively used to dissect this liquid-injected space. *Results :* In comparison with the cases of inguinal hernia repair without liquid-injection and gauze dissection, the cases who underwent TAPP inguinal hernia repair with liquid-injection and gauze dissection experienced shorter operation times and no complications or recurrence. *Conclusions :* TAPP inguinal hernia repair with liquid-injection and gauze dissection appears to be a safe and feasible procedure. *J. Med. Invest.* 67: 271-273, August, 2020

Keywords : TAPP, liquid injection, gauze dissection

INTRODUCTION

Laparoscopic trans-abdominal pre-peritoneal (TAPP) inguinal hernia repair has been reported since the 1990s (1). Patients undergoing TAPP inguinal hernia repair experienced less pain, less surgical trauma and a faster return to daily activities, compared with conventional hernia repair (2).

In Japan, the number of cases of laparoscopic TAPP inguinal hernia repair has been increasing (3). However, the recurrence during laparoscopic TAPP inguinal hernia repair was reported to occur in 3.0% of cases. The main reasons for the recurrence included prolapsed mesh and inadequate mesh size. Especially, to prevent the recurrence during laparoscopic TAPP inguinal hernia repair, adequate dissection of the pre-peritoneal space was important. Mizota, *et al.* reported that liquid infiltration of the pre-peritoneal space could facilitate dissection and avoid inadvertent injuries (4). This technique made laparoscopic TAPP inguinal hernia repair easier for the trainees with limited operative experience. And we found that the liquid-injected space was effectively dissected with the gauze.

The aim of this study was to evaluate a novel technique for laparoscopic TAPP inguinal hernia repair using liquid injection and gauze dissection.

MATERIALS AND METHODS

From August 2009 to August 2017, ninety-five (95) patients (eighty-seven (87) men and eight (8) women ; mean age sixty-six (66) years ; age range from eighteen (18) to eighty-eight (88) years) with unilateral inguinal hernia except for recurrence

were referred to the Tokushima University for treatment of inguinal hernia.

Seventy (70) patients with inguinal hernia who underwent laparoscopic TAPP inguinal hernia repair without liquid-injection and gauze dissection were enrolled in the study. The remaining twenty-five (25) patients underwent laparoscopic TAPP inguinal hernia repair using liquid-injection and gauze dissection (Table 1).

Table 1. Patients' characteristics in the two (2) groups.

Factors	No liquid injection and gauze dissection (n = 70)	Liquid injection and gauze dissection (n = 25)
Age (y.o.)	64 (18-88)	70 (42-86)
Gender : male/female	63/7	24/1
Right/Left	39/31	15/10
JHS type (I/II/III)	57/11/2	16/9/0
BMI (kg/m ²)	24.7 (18.4-36.5)	24.7 (19-30.3)

After laparoscopic TAPP inguinal hernia repair, the patients started eating on day one (1) post-operatively. If recovery proceeded according to plan, they were discharged from the hospital on day two (2) to day seven (7) post-operatively.

In the post-operative follow up, if the patients found inguinal bulging in the repaired side, they could come to the Department of Surgery, Tokushima University where a check would be

Key words and acronyms

Trans-abdominal Pre-peritoneal (TAPP), myopecteneal orifice (MPO), liquid-injection, gauze dissection

Received for publication March 9, 2020 ; accepted April 30, 2020.

Address correspondence and reprint requests to Hideya Kashihara, M.D., Ph.D., Department of Surgery, Tokushima university 3-18-15 Kuramoto-cho, Tokushima, 770-8503, Japan and Fax : +81-88-631-9698.

made of their inguinal region to judge whether recurrence had occurred or not.

Surgical technique

All procedures were performed under general anesthesia in a supine and head-down position. The operator performed on the oppositional side to the hernia. A camera-port was placed at the umbilicus using an open technique, followed by two (2) 5-mm trocars on the bilateral border of the rectus abdominis muscle, at the edge of the inferior epigastric vessels. The injected liquid was composed of epinephrine 0.2 ml, ropivacaine 20 ml in 180 ml of normal saline solution. Before the initial peritoneal incision, this liquid was injected percutaneously into the pre-peritoneal space at two (2) points using a 22 gauge needle. These two (2) injection points were the outside of the internal inguinal ring and the inside of the seminal duct. Especially, in the inside of the seminal duct, the liquid was injected into the space between the superficial and deep lobe of pre-peritoneal fascia (Figures 1a and 1b). In the previous reports, the amount of this injected liquid was reported to be more than 10 ml. However, the injection volume was reduced in order to understand the anatomical structure in the inguinal area. The injected liquid allowed for the pre-peritoneal space to be easily dissected. The initial incision of the peritoneum was made from the lateral side of the inguinal canal to the medial umbilical fold. In this dissection, the gonadal vessels, seminal duct for men and the inferior epigastric vessels for all the patients were identified. When the medial umbilical fold was grasped and extended medially, the rough

space was found inside of the seminal duct. After dissecting this liquid-injected space using the gauze, the Cooper ligament was easily exposed (Figure 2). After identifying these structures, the gauze dissection was performed in the liquid-injected space. The landmarks of the dissection were the pubis symphysis in the medial side, the aponeurosis of the transversus abdominis in the ventral side and the anterior superior iliac spine in the lateral side (Figure 3). After the fully dissection of the pre-peritoneal space, the mesh was placed in this space. The mesh size required to fully cover the myoepecteneal orifice (MPO) is shown in Figure

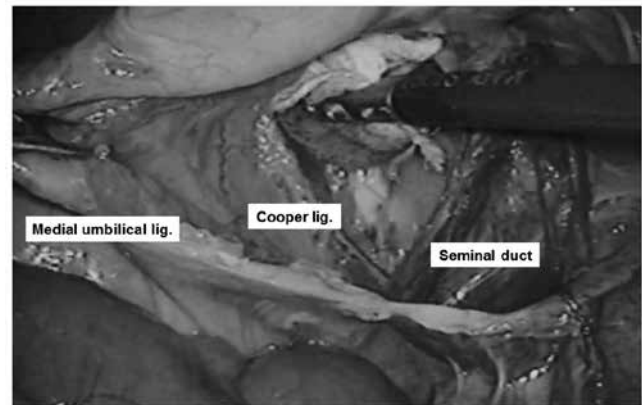


Figure 2. After dissecting this liquid-injected space by using the gauze, the Cooper ligament was easily exposed.

Figure 1a

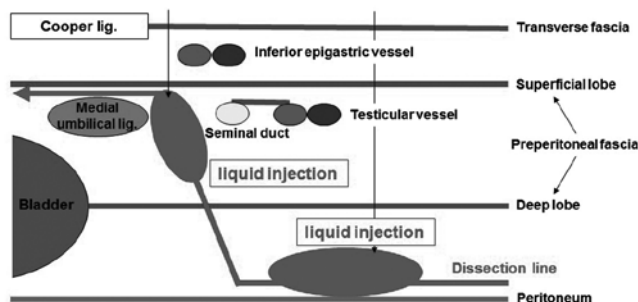


Figure 1b

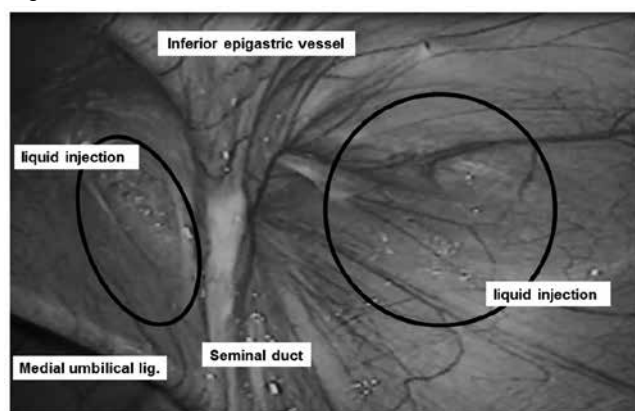


Figure 1a, 1b. The schema of liquid injection. The normal saline solution with ropivacaine and epinephrine was injected percutaneously into the pre-peritoneal space at two (2) points, which is the outside of the internal inguinal ring and the inside of the seminal duct. Especially, in the inside of the seminal duct, the liquid was injected into the space between the superficial and deep lobe of pre-peritoneal fascia.

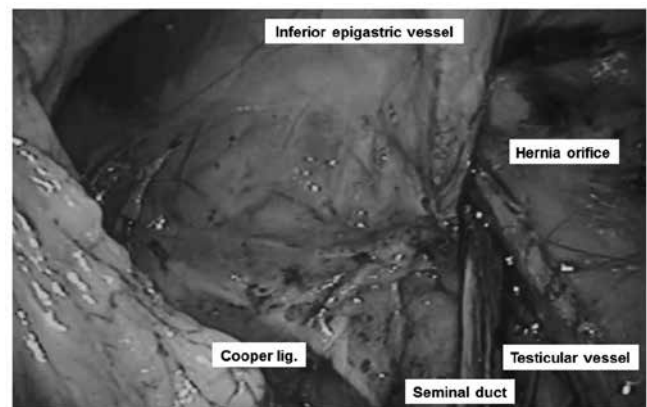


Figure 3. Complete dissection in the pre-peritoneal space.



Figure 4. The placement of adequate mesh.

4. The positions for fixing the mesh by using the surgical tack were the Cooper ligament, the abdominal rectus muscle and the aponeurosis of the transverse abdominal muscle, especially if the margin of the hernia orifice was more than 3 cm. Finally, the peritoneum was closed with a continuous suture of absorbable thread.

Statistical analysis

The t-test was used for statistical analysis of the continuous variables. For all tests, $p < 0.05$ was interpreted as significant. Values for each continuous variable were expressed as a mean \pm the standard deviation (SD).

RESULTS

Table 2 shows the surgical outcomes in the two (2) groups. The operation time in the group with liquid injection and gauze dissection was significantly shorter than that in the group without liquid injection and gauze dissection (120.7 ± 18.9 vs 84.5 ± 15.2 , $p < 0.05$). There was no significant difference in the post-operative hospital stay and conversion to open surgery. However, the group with liquid injection and gauze dissection had no post-operative complications and no recurrence.

Table 2. Surgical outcomes in the two (2) groups.

Factors	No liquid injection and gauze dissection (n = 70)	Liquid injection and gauze dissection (n = 25)
Operation time (min.)	120.7 ± 18.9	$84.5 \pm 15.2^*$
Postoperative hospital stay (days)	4.8 ± 1.6	4.8 ± 0.4
Conversion (%)	0	0
Complication (%)	1.4 (n = 1)	0
Recurrence (%)	2.9 (n = 2)	0

* $p < 0.05$

DISCUSSION

In laparoscopic TAPP inguinal hernia repair with liquid injection and gauze dissection, the normal saline solution with ropivacaine and epinephrine was injected percutaneously into the pre-peritoneal space at two (2) points, namely the outside of the internal inguinal ring and the inside of the seminal duct. Especially, in the inside of seminal duct, the liquid was injected into the space between the superficial and deep lobe of pre-peritoneal fascia. This liquid-injected space was effectively dissected by using the gauze. As a result, this technique contributed to: the complete dissection of the pre-peritoneal space; the prevention of prolapsed mesh; a low recurrence rate; and a shorter operation time.

The number of laparoscopic inguinal hernia repairs has been increasing according to the 13th Nationwide Survey of Endoscopic Surgery in Japan (TAPP, n = 10,174 in 2015) (3). Laparoscopic inguinal hernia repair occurred in 20% of the total cases who underwent inguinal hernia repair.

However, the recurrence rate for laparoscopic TAPP inguinal hernia repair was reported to be 3.0% of cases. This rate was

higher than other procedures of hernia repair (mesh plug, bilayer patch device method, Kugel and direct Kugel). The reasons for the recurrence in laparoscopic inguinal hernia repair included prolapsed mesh, inadequate mesh size, suprapubic hernia and others.

Inadequate dissection in the pre-peritoneal space leads to prolapsed mesh, poor mesh extension and selection of small mesh in laparoscopic TAPP inguinal hernia repair. Therefore, inadequate dissection leads to post-operative recurrence. So, complete dissection in the pre-peritoneal space is needed for the prevention of a recurrence.

Liquid-injection was reported to assist pre-peritoneal dissection and could minimize trauma to surrounding structures. Furthermore, this technique was useful especially when performed by trainees with limited operative experience (4). The authors of this study contend that using gauze dissection is more effective to dissect the liquid-injected space. Finally, this novel technique contributed to the complete dissection of pre-peritoneal space, the prevention of prolapsed mesh, a low recurrence rate and a shorter operation time.

In conclusion, laparoscopic TAPP inguinal hernia repair with liquid-injection and gauze dissection assisted pre-peritoneal dissection and contributed to a shorter operation time, no complications and no recurrence. This novel technique appears to be safe and feasible.

ACKNOWLEDGMENTS

The authors of this study are grateful to the staff at the Department of Surgery, Tokushima University, for important contributions.

DISCLOSURES

Hideya Kashihara and the co-authors have no conflict of interest regarding this report.

Informed consent was obtained from all individual participants included in the study. The institutional review board approved this retrospective study prior to data collection.

REFERENCES

1. Corbitt JD Jr. : Laparoscopic herniorrhaphy. *Surg Laparosc Endosc* 1 : 23-25, 1991
2. Eklund A, Montgomery A, Bergkvist L, Rudberg C ; Swedish Multicentre Trial of Inguinal Hernia Repair by Laparoscopy (SMIL) study group : Chronic pain 5 years after randomized comparison of laparoscopic and Lichtenstein inguinal hernia repair. *Br J Surg* Apr 97(4) : 600-608, 2010
3. Japan Society for Endoscopic Surgery : 13th Nationwide Survey of Endoscopic Surgery in Japan. *Journal of Japan Society for Endoscopic Surgery* 21(6) : 655-810, 2016
4. Mizota T, Watanabe Y, Madani A, Takemoto N, Yamada H, Poudel S, Miyasaka Y, Kurashima Y : Liquid-injection for preperitoneal dissection of transabdominal preperitoneal (TAPP) inguinal [corrected] hernia repair. *Surg Endosc* Mar 29(3) : 516-20, 2015