

ORIGINAL**A new combined index of SUVmax of lymph node in PET/CT by a weighting coefficient plus its maximum minor axis in CECT to evaluate occult lymph node metastasis in clinical N0 patients with tongue cancer**

Ryo Kanamura^{1,2}, Motoyuki Suzuki^{2,3}, Shinji Otozai², Tadashi Yoshii², Hidehiko Okamoto⁴, Yoshiaki Kitamura¹, Koji Abe¹, Takashi Fujii¹, and Noriaki Takeda¹

¹Department of Otolaryngology, Tokushima University Graduate School of Biomedical Sciences, Tokushima, Japan, ²Department of Head and neck Surgery, Osaka International Cancer Institute, Osaka, Japan, ³Department of Otolaryngology-Head and neck Surgery, Osaka University School of Medicine, Osaka, Japan, ⁴Department of Physiology, International University of Health and Welfare School of Medicine, Narita, Japan

Abstract : To predict occult nodal metastasis in clinical N0 patients with tongue cancer, we developed combined index (CI) : SUVmax of the largest lymph node in PET/CT by weighting coefficient plus its maximum minor axis (<10 mm) in contrast-enhanced CT (CECT). In this retrospective study, 57 clinical N0 patients with tongue cancer, who underwent elective supraomohyoid neck dissection at cervical levels of I-III were enrolled. The cutoff value of SUVmax of 2.0 obtained using receiver operating characteristic (ROC) analysis predicted the postoperative positive cervical levels containing metastatic lymph nodes from clinical N0 cervical levels in tongue cancer patients with a sensitivity of 54.5% and a specificity of 78.2%. The cutoff value of CI with weighting coefficient of 1.5 obtained using ROC analysis was 9.8 at the maximum area under the curve of 0.750. The cutoff value of 9.8 predicted the postoperative positive cervical levels containing metastatic lymph nodes from clinical N0 cervical levels in tongue cancer patients with a sensitivity of 68.2% and a specificity of 81.5%. These findings suggest that CI of functional PET/CT and morphological CECT components might improve the diagnostic performance of occult nodal metastasis to select clinical N0 patients with tongue cancer preferable for elective neck dissection. *J. Med. Invest.* 68: 154-158, February, 2021

Keywords : Tongue cancer, lymph node metastasis, clinical N0 neck, occult nodal metastasis, PET/CT

INTRODUCTION

Cervical lymph node metastasis is one of the most important prognostic factors in patients with head and neck squamous cell carcinoma (HNSCC) and is essential for staging procedures and deciding definitive treatments (1). Contrast-enhanced computed tomography (CECT) and magnetic resonance imaging (MRI) are widely used for the assessment of cervical lymph node status before treatment (2). However, because of false negative nodal metastasis assessed with CECT and MRI, the diagnostic accuracy of radiological imaging modalities for detecting cervical lymph node metastasis is insufficient (3). In particular, occult metastatic lymph nodes are the major prognostic factor for survival in HNSCC patients with clinically negative cervical lymph nodes (4). It was reported that the prevalence of occult metastatic lymph nodes was 20%–30% of HNSCC patients, regardless of their primary tumor T stage (5-8).

The uptake of ¹⁸F-fluorodeoxyglucose (FDG) is increased in malignant tumors that enhances the metabolism of glucose. Therefore, positron emission tomography with integrated computerized tomography (PET/CT) can assess the primary site of HNSCC, cervical lymph nodes and distant metastasis (9). The maximum standardized uptake value (SUVmax) is used as a

quantitative parameter of FDG uptake, and PET/CT has been shown to be effective in detecting cervical lymph node metastasis (10). However, false negative nodal metastasis assessed with PET/CT is still a problem in the pretreatment evaluation of patients with HNSCC (11).

In the present retrospective study, clinical N0 patients with tongue cancer, who underwent elective supraomohyoid neck dissection at cervical levels of I-III were enrolled. We first examined the cutoff value of SUVmax in PET/CT to detect cervical lymph node metastasis in patients with clinically negative cervical lymph nodes of squamous cell carcinoma (SCC) of the tongue. Accordingly, we extracted a lymph node with the largest minor axis (<10 mm) at each cervical level of I-III from preoperative CECT imaging in clinical N0 patients with tongue SCC. We then examined the correlation between the SUVmax of the lymph node extracted from a cervical level and postoperative histopathological findings of the resected lymph node at the corresponding cervical level. Finally, an attempt was made to identify a new diagnostic index to detect occult metastasis of cervical lymph nodes. For this purpose, we developed a combined index : SUVmax of the largest lymph node in PET/CT by a weighting coefficient plus its maximum minor axis in CECT at a cervical level. The cutoff value of the combined index was examined to predict cervical metastatic lymph nodes in clinical N0 patients with tongue SCC using receiver operating characteristic (ROC) analysis.

Received for publication December 20, 2020 ; accepted January 19, 2021.

Address correspondence and reprint requests to Noriaki Takeda, M.D., Ph.D., Department of Otolaryngology, Tokushima University Graduate School of Biomedical Sciences, 3-18-15 Kuramoto, Tokushima 770-8502, Japan and Fax : +81-88-633-7170.

PATIENTS AND METHODS

Patients

A retrospective study was conducted at the Osaka International Cancer Institute Hospital. Among the 282 patients with tongue SCC who were previously untreated, 84 patients were evaluated as clinically N0 cervical stage using CECT between January 2005 and December 2013. In the preoperative assessment of cervical lymph node metastasis, lymph nodes with a maximum minor axis of 10 mm or more with focal defect and/or rim enhancement in preoperative CECT were evaluated as clinically positive. In the present study, 57 clinical N0 patients with tongue SCC were enrolled. They underwent elective supraomohyoid neck dissection at cervical levels of I-III defined by the classification system of neck dissection (12) as a part of the primary surgical treatment according to "Japanese Clinical Practice Guideline for Head and Neck Cancer" made by the clinical practice guideline committee of Japan Society for Head and Neck Cancer. After surgery, neck resection specimens were histopathologically analyzed. This study was approved by the Ethics Committee of the Osaka International Cancer Institute Hospital.

CECT and PET/CT

All patients underwent both CECT with a slice thickness of 1 mm and PET/CT within a month before surgery. ¹⁸F-FDG was intravenously injected at a dose of 3.7 mBq/kg after fasting for 5 h. PET/CT was performed 60 min later using SIEMENS Biograph Duo (Siemens Medical Solutions Inc., Knoxville, TN, USA) or Philips GEMINI GXL (Philips Medical Systems, Cleveland, OH, USA).

Because it is impossible to determine the exact spatial correlation between a resected lymph node and imaging of a lymph node on CECT or PET/CT in clinical N0 patients, we first extracted a lymph node with the largest minor axis (<10 mm) at each cervical level of I-III from preoperative CECT imaging and measured the minor axis of the extracted lymph node in the present study. When a given cervical level contained at least one metastatic lymph node postoperatively, the largest lymph node at the cervical level of CECT was considered to be histopathologically positive metastasis and its SUVmax of PET/CT was measured. When a given cervical level contained no metastatic lymph node postoperatively, the largest lymph node at the cervical level of CECT was considered to be histopathologically negative metastasis and the SUVmax of PET/CT was measured. Thereafter, the cutoff value of SUVmax in preoperative PET/CT to predict postoperative metastatic lymph nodes was determined using ROC analysis.

Combined index

A new combined index: SUVmax of the largest lymph node in PET/CT by a weighting coefficient plus its maximum minor axis (<10 mm) in CECT at a cervical level was developed. The cutoff values of the combined index to predict postoperative metastatic lymph nodes were evaluated using ROC analysis by changing the values of the weighting coefficient. After determining the weighting coefficient value to achieve the maximum area under the curve (AUC) of ROC, the optimal cutoff value of the combined index was determined.

Statistical analysis

The ROC analysis and Student's t-test were performed for statistical analysis using EZR (Saitama Medical Center, Jichi Medical University, Saitama, Japan). $p < 0.05$ was considered significant.

RESULTS

The enrolled 57 clinical N0 patients with tongue SCC consisted of 34 males and 23 females with a mean age of 56.7 years (range 16-83 years). As per clinical T staging, T1 was 9, T2 was 38 and T3 was 10 patients. All patients are clinical N0 and M0 (Table 1). Ipsilateral elective supraomohyoid neck dissection was performed on 57 sides of the neck at cervical levels of I-III. Among the 171 cervical levels that underwent neck dissection, 22 cervical levels contained at least one metastatic lymph node, and the largest lymph node was extracted at the corresponding cervical levels of CECT. Among the remaining 149 cervical levels that contained no metastatic lymph node postoperatively, lymph nodes were extracted in 119 cervical levels of CECT. Accordingly, among 141 cervical levels that contained the extracted lymph nodes, of which the maximum minor axis was less than 10 mm in preoperative CECT, 22 cervical levels contained metastatic lymph nodes, while 119 cervical levels did not.

The cutoff value of SUVmax of 2.0 obtained using ROC analysis predicted postoperative positive cervical levels from clinical N0 cervical levels in these patients with a sensitivity of 54.5% and a specificity of 78.2% (Table 2). The same cutoff value of SUVmax predicted pathological positive N stage in these clinical N0 patients with a sensitivity of 58.8% and a specificity of 62.5% (Table 3).

Then, we developed a new combined index of SUVmax of the extracted lymph node in PET/CT by a weighting coefficient plus its minor axis on CECT at a cervical level. The value of AUC was assessed using ROC analysis by changing the values of the weighting coefficient, and the maximum AUC of 0.750 was achieved at the weighting coefficient of 1.5 (Table 4). The mean

Table 1. Patients Characteristics

Characteristics	n	%
Patients	57	
Sex		
Male	34	59.6
Female	23	40.4
Age	56.7 y	(16-83 y)
cT stage*		
T1	9	15.8
T2	38	66.7
T3	10	17.5
T4	0	0

*7th ed. UICC

Table 2.

SUVmax	Histopathological metastasis		
	Positive level	Negative level	Total
Positive (≥ 2.0)	12	26	38
Negative (< 2.0)	10	93	103
Total	22	119	141

Table 3.

SUVmax	Histopathological status of the neck		
	Positive	Negative	Total
Positive (≥ 2.0)	10	15	25
Negative (< 2.0)	7	25	32
Total	17	40	57

Table 4.

Weighting coefficient	1	1.1	1.2	1.3	1.4	1.5	1.6	1.7	1.8	1.9	2.0
AUC*	0.747	0.747	0.748	0.748	0.748	0.750	0.747	0.745	0.745	0.744	0.743

*AUC : area under the curve

values of the combined index with the weighting coefficient of 1.5 in metastatic lymph nodes at 22 cervical levels were significantly increased, compared to those at 119 negative cervical levels in these patients ($t(139) = -4.6734$, $p < 0.05$) (Fig. 1). The cutoff value of the combined index with the weighting coefficient of 1.5 to predict metastatic cervical levels from clinical N0 cervical levels was then assessed using ROC analysis and was determined to be 9.8.

The cutoff value of the combined index of 9.8 predicted the postoperative positive cervical levels from clinical N0 cervical levels with a sensitivity of 68.2% and a specificity of 81.5% (Table 5). The same cutoff value of the combination index predicted pathological positive N stage in these clinical N0 patients with a sensitivity of 82.4% and a specificity of 67.5% (Table 6).

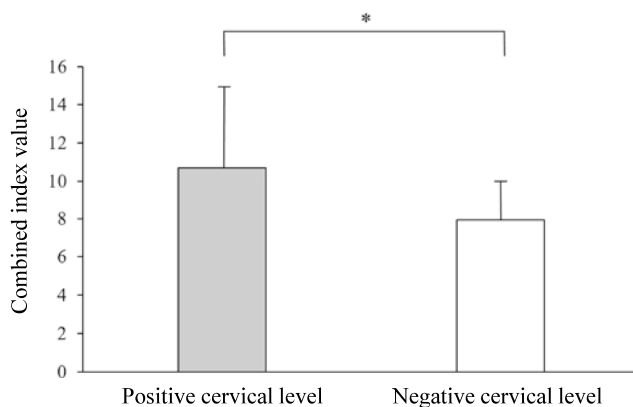


Figure 1. Comparison of combined index values between positive and negative cervical levels. Columns and bars represent means \pm S.D. of the mean values of the combined index with the weighting coefficient of 1.5 in lymph nodes of 22 metastatic positive cervical levels, and those of 119 negative cervical levels in clinical N0 patients with squamous cell carcinoma of tongue. * $p < 0.05$.

Table 5.

Combined index	Histopathological metastasis		
	Positive level	Negative level	Total
Positive (≥ 9.8)	15	22	37
Negative (< 9.8)	7	97	104
Total	22	119	141

Table 6.

Combined index	Histopathological status of the neck		
	Positive	Negative	Total
Positive (≥ 9.8)	14	13	27
Negative (< 9.8)	3	27	30
Total	17	40	57

DISCUSSION

CECT is still a standard tool for the diagnosis of cervical lymph node metastasis in patients with HNSCC. A meta-analysis reported that CECT showed a sensitivity of 81% (range 68%–90%) and a specificity of 76% (range 62%–87%) for the diagnosis in such patients (13). PET/CT, a functional imaging of glucose metabolism with integrated CT is successively applied in the diagnosis, grading, staging and assessment of treatment response of HNSCC. A recent meta-analysis showed that it is also useful for the detection of nodal metastasis in HNSCC (10). A meta-analysis reported that PET/CT showed a sensitivity of 79% (range 72%–85%) and a specificity of 86% (range 83%–89%) for the diagnosis of cervical lymph node metastasis in patients with HNSCC (11).

However, occult metastatic lymph nodes are the major prognostic factor for survival in clinical N0 patients with HNSCC (4) and its prevalence was reported to be over 20% of the patients with negative cervical stage evaluated using CECT (5–8). A meta-analysis reported that PET/CT showed a sensitivity of only 50% (range 37%–63%) and a specificity of 87% (range 76%–93%) for the diagnosis of cervical lymph node metastasis in clinical N0 patients with HNSCC (10). In the present study, the cutoff SUVmax of 2.0 in preoperative PET/CT showed a sensitivity of 54.5% and a specificity of 78.2% for the diagnosis of postoperative positive cervical levels from clinical N0 cervical levels of I–III, and a sensitivity of 58.8% and a specificity of 62.3% for the diagnosis of pathological positive N stage in clinical N0 patients with tongue SCC. Thus, PET/CT showed high specificity, but sensitivity was lower than desired in detecting nodal metastasis in clinical N0 patients with oral cavity SCC (14, 15).

The major question is whether to treat HNSCC patients with clinical N0 neck with elective neck dissection or to adopt observation/therapeutic neck dissection (16). A decision analysis showed that elective neck dissection is preferable over watchful waiting in patients with early stage oral tongue carcinoma with no clinical nodal metastases (17). However, another decision analysis showed that careful observation is preferable to prophylactic neck dissection in oral cancer patients without clinical nodal metastases (18). A recent prospective, randomized, controlled trial reported that elective neck dissection showed higher rates of overall, disease-free survival than watchful waiting followed by neck dissection for nodal relapse in patients with early stage oral SCC (19). Therefore, the decision of elective neck dissection still depends on the probability of occult neck metastasis. To avoid unnecessary surgeries, patients who would have the greatest benefit from elective neck dissection should be selected.

In the present study, we developed a new combined index of SUVmax of the lymph node in PET/CT by a weighting coefficient plus its minor axis in CECT for more accurate diagnosis of occult metastatic lymph nodes in clinical N0 patients with tongue SCC. Indeed, the combined index of SUVmax by the weighting coefficient of 1.5 plus the maximum minor axis with the optimal cutoff value of 9.8 showed better sensitivity of 68.2% and continued high specificity of 81.5% to predict postoperative positive cervical levels from clinical N0 levels of I–III. The same cutoff value of the combination index also predicted pathological positive N stage with better sensitivity of 82.4% and continued high specificity of 67.5% in clinical N0 patients. While PET/CT

has low sensitivity and high specificity for the diagnosis of occult cervical lymph node metastasis (14, 15), the combined index that effectively combined SUVmax of lymph node in PET/CT with its minor axis in CECT increased the sensitivity and retained the high specificity for the diagnosis of cervical lymph node metastasis in clinical N0 patients with tongue SCC.

In the present retrospective study, among 27 tongue SCC patients with clinical N0 and positive combined index, histopathologic metastasis in cervical lymph nodes was found in 52% (14/27) of patients. Because the decision analysis showed elective neck dissection is warranted when the probability of occult neck metastasis is more than 20% in clinical N0 patients with HNSCC (20), clinical N0 patients with a positive combined index may be good candidates for elective neck dissection for better prognosis of tongue SCC.

The present study has several limitations including retrospective design and its small sample size. A selection bias (i.e., predilection of elective neck dissection for advanced T stages) may have influenced the results in the present study. Further prospective studies are required to prove the efficacy of the combined index to evaluate occult lymph node metastasis in clinical N0 patients with tongue cancer.

CONCLUSION

In conclusion, the present study suggests that the combined index of functional SUVmax in PET/CT and morphological minor axis in CECT might be a promising tool to improve the diagnostic performance of occult nodal metastasis to select clinical N0 patients with tongue SCC preferable for elective neck dissection.

CONFLICT OF INTEREST

The authors declare no conflicts of interest in this study.

REFERENCES

- Layland MK, Sessions DG, Lenox J : The influence of lymph node metastasis in the treatment of squamous cell carcinoma of the oral cavity, oropharynx, larynx, and hypopharynx : N0 versus N+. *Laryngoscope* 115 : 629-639, 2005
- Atula TS, Varpula MJ, Kurki TJ, Klemi PJ, Grénman R : Assessment of cervical lymph node status in head and neck cancer patients : palpation, computed tomography and low field magnetic resonance imaging compared with ultrasound-guided fine-needle aspiration cytology. *Eur J Radiol* 25 : 152-161, 1997
- Liao LJ, Lo WC, Hsu WL, Wang CT, Lai MS : Detection of cervical lymph node metastasis in head and neck cancer patients with clinically N0 neck : a meta-analysis comparing different imaging modalities. *BMC Cancer* 12 : 236, 2012
- Leemans CR, Tiwari R, Nauta JJ, van der Waal I, Snow GB : Regional lymph node involvement and its significance in the development of distant metastases in head and neck carcinoma. *Cancer* 71 : 452-456, 1993
- Okamoto M, Nishimine M, Kishi M, Kirita T, Sugimura M, Nakamura M, Konishi N : Prediction of delayed neck metastasis in patients with stage I/II squamous cell carcinoma of the tongue. *J Oral Pathol Med* 31 : 227-233, 2002
- Pimenta Amaral TM, Da Silva Freire AR, Carvalho AL, Pinto CA, Kowalski LP : Predictive factors of occult metastasis and prognosis of clinical stages I and II squamous cell carcinoma of the tongue and floor of the mouth. *Oral Oncol* 40 : 780-786, 2004
- Psychogios G, Mantsopoulos K, Bohr C, Koch M, Zenk J, Iro H : Incidence of occult cervical metastasis in head and neck carcinomas : development over time. *J Surg Oncol* 107 : 384-387, 2013
- de Bree R, Takes RP, Castelijns JA, Medina JE, Stoeckli SJ, Mancuso AA, Hunt JL, Rodrigo JP, Triantafyllou A, Teymoortash A, Civantos FJ, Rinaldo A, Pitman KT, Hamoir M, Robbins KT, Silver CE, Hoekstra OS, Ferlito A : Advances in diagnostic modalities to detect occult lymph node metastases in head and neck squamous cell carcinoma. *Head Neck* 37 : 1829-1839, 2015
- Fletcher JW, Djulbegovic B, Soares HP, Siegel BA, Lowe VJ, Lyman GH, Coleman RE, Wahl R, Paschold JC, Avril N, Einhorn LH, Suh WW, Samson D, Delbeke D, Gorman M, Shields AF : Recommendations on the use of 18F-FDG PET in oncology. *J Nucl Med* 49 : 480-508, 2008
- Yongkui L, Jian L, Wanghan, Jingui L : 18FDG-PET/CT for the detection of regional nodal metastasis in patients with primary head and neck cancer before treatment : a meta-analysis. *Surg Oncol* 22 : e11-16, 2013
- Kyzas PA, Evangelou E, Denaxa-Kyza D, Ioannidis JP : 18F-fluorodeoxyglucose positron emission tomography to evaluate cervical node metastases in patients with head and neck squamous cell carcinoma : a meta-analysis. *J Natl Cancer Inst* 100 : 712-720, 2008
- Robbins KT, Clayman G, Levine PA, Medina J, Sessions R, Shaha A, Som P, Wolf GT ; American Head and Neck Society ; American Academy of Otolaryngology-Head and Neck Surgery : Neck dissection classification update : revisions proposed by the American Head and Neck Society and the American Academy of Otolaryngology-Head and Neck Surgery. *Arch Otolaryngol Head Neck Surg* 128 : 751-758, 2002
- de Bondt RB, Nelemans PJ, Hofman PA, Casselman JW, Kremer B, van Engelshoven JM, Coleman RE, Wahl R, Paschold JC, Avril N, Einhorn LH, Suh WW, Samson D, Delbeke D, Gorman M, Shields AF : Detection of lymph node metastases in head and neck cancer : a meta-analysis comparing US, USgFNAC, CT and MR imaging. *Eur J Radiol* 64 : 266-272, 2007
- Krabbe CA, Dijkstra PU, Pruim J, van der Laan BF, van der Wal JE, Gravendeel JP, Roodenburg JL : FDG PET in oral and oropharyngeal cancer. Value for confirmation of N0 neck and detection of occult metastases. *Oral Oncol* 44 : 31-36, 2008
- Zhang H, Seikaly H, Biron VL, Jeffery CC : Utility of PET-CT in detecting nodal metastasis in cN0 early stage oral cavity squamous cell carcinoma. *Oral Oncol* 80 : 89-92, 2018
- Wei WI, Ferlito A, Rinaldo A, Gourin CG, Lowry J, Ho WK, Leemans CR, Shaha AR, Suárez C, Clayman GL, Robbins KT, Bradley PJ, Silver CE : Management of the N0 neck : reference or preference. *Oral Oncol* 42 : 115-122, 2006
- Song T, Bi N, Gui L, Peng Z : Elective neck dissection or "watchful waiting" : optimal management strategy for early stage N0 tongue carcinoma using decision analysis techniques. *Chin Med J* 121 : 1646-1650, 2008
- Kaneko S, Yoshimura T, Ikemura K, Shirasuna K, Kusukawa J, Ohishi M, Shiba R, Sunakawa H, Tominaga K, Sugihara K, Shinohara M, Katsuki T, Yanagisawa S, Kurokawa H, Mimura T, Ikeda H, Yamabe S, Ozeki S : Primary neck management among patients with cancer of the oral cavity without clinical nodal metastases : a decision and sensitivity analysis. *Head Neck* 24 : 582-590, 2002
- D'Cruz AK, Vaish R, Kapre N, Dandekar M, Gupta S,

- Hawaldar R, Agarwal JP, Pantvaidya G, Chaukar D, Deshmukh A, Kane S, Arya S, Ghosh-Laskar S, Chaturvedi P, Pai P, Nair S, Nair D, Badwe R : Head and Neck Disease Management Group : Elective versus therapeutic neck dissection in node-negative oral cancer. *N Engl J Med* 373 : 521-529, 2015
20. Weiss MH, Harrison LB, Isaacs RS : Use of decision analysis in planning a management strategy for the stage N0 neck. *Arch Otolaryngol Head Neck Surg* 120 : 699-702, 1994