

ORIGINAL

Optimal baseplate position in reverse shoulder arthroplasty in small-stature Japanese women : a cadaveric study

Shoji Fukuta^{1,2}, Keizo Wada², Kosaku Higashino^{2,3}, Koichi Sairyō², and Yoshihiro Tsuruo⁴

¹Department of Orthopaedic Surgery, National Hospital Organization Kochi National Hospital, Kochi, Japan, ²Department of Orthopedics, Institute of Biomedical Sciences, Tokushima University Graduate School, Tokushima, Japan, ³Department of Orthopaedic Surgery, National Hospital Organization Shikoku Medical Center for Children and Adults, Kagawa, Japan, ⁴Department of Anatomy and Cell Biology, Tokushima University Faculty of Medicine, Tokushima, Japan

Abstract : The purpose of this study was to determine the optimal position of the baseplate on the small glenoid of female Japanese. Two sets of 3D scapular models were made according to the CT data of 7 female cadavers. We set two scenarios of the baseplate placement : A and B. In scenario A, the baseplate was placed on the glenoid face centrally in the anteroposterior direction. In scenario B, the baseplate was implanted at the point where the baseplate post was contained within the glenoid vault. Whether or not the baseplate post perforated the scapular neck was recorded. In scenario A, the central post penetrated the scapular neck posteriorly in 5 scapulae. In scenario B, the average distances from the guide pin position to the anterior glenoid rim was 9.7 ± 1.7 mm and the optimal position of the guide pin was 1.9 ± 1.7 mm anterior from the glenoid center. The central post was contained within the scapula without breakage of the cortex. This study demonstrated that shifting the center of the baseplate slightly anterior to the anatomic center is necessary to avoid perforation of the scapular neck in small female Japanese. *J. Med. Invest.* 68: 175-180, February, 2021

Keywords : reverse shoulder arthroplasty, glenoid baseplate, Japanese female, small stature

Reverse shoulder arthroplasty (RSA) was developed by Paul Grammont in 1985 to restore shoulder function in patients with cuff tear arthropathy (CTA) (1). The basic concept of RSA is reversal of glenohumeral joint anatomy by replacing the glenoid cavity with large-diameter convex metallic glenosphere and humeral head with concave polyethylene socket to cause distalization and medialization of the center of rotation of the shoulder. This prosthetic design increases the lever arm and force of the deltoid muscle, which acts as a stabilizer and main muscle of the shoulder.

RSA has been proven to provide satisfactory pain relief and functional improvement for patients with rotator cuff deficiency (2, 3). Recently, first-line surgical treatment for cuff tear arthropathy and its indications have been expanded to include fracture of the proximal humerus (4), rheumatoid arthritis (5), primary osteoarthritis, tumors of the proximal humerus (6) and revision surgeries for failed anatomical shoulder arthroplasty (7).

Optimal positioning and secure initial fixation of the glenoid baseplate is critical for long-term and excellent clinical outcomes of RSA. Lower positioning of the glenoid baseplate on the glenoid surface is recommended to avoid scapular notching, which is the most common radiographic complication after RSA (8). In the anteroposterior plane, the pilot hole should also be positioned optimally to eliminate penetration of the central post outside the glenoid vault (9). Kelly *et al.* (9) developed a computed tomography (CT) -template protocol to determine the position of the pilot hole by superimposing a virtual baseplate on the axial image 12 mm above the inferior glenoid rim. They reported that the optimal position determined by their protocol was slightly posterior

in anteroposterior dimensions. Their study did not state the sex and race of the specimens ; however, the size of the scapulae in their study was similar to those of other published anatomical studies. Conversely, in our current clinical practice, we have found it necessary to shift the center of the baseplate slightly anterior to the anatomic center of the glenoid to avoid the posterior cortex of the scapular neck from breaking in small-stature Japanese women (10).

The purpose of this study was to determine if the preoperative planning protocol proposed by Kelly *et al.* (9) could be applied to Japanese shoulders, which are considerably smaller than those of Caucasians. We hypothesized that the optimal position of the baseplate would differ in women with a glenoid fossa that is smaller than the baseplate. We sought to demonstrate the optimal baseplate position to avoid the central peg from perforating the glenoid fossa bone of small-stature women.

METHODS

Seven fresh frozen cadavers were used in this study. All specimens were Japanese women, (mean age, 82.4 years ; range, 48 to 100) years. All the cadavers were donated to Tokushima University for research purposes. The study was approved by the Institutional Review Board of Tokushima University.

For all cadaveric specimens, CT scans were obtained with a 16-slice scanner (Somatom Emotion-16 ; Siemens Japan, Tokyo, Japan). The scanning parameters were as follows : 130 kV ; 134 mA ; slice thickness, 0.75 mm ; screw pitch, 0.5 mm ; and matrix, 512×512 . None of the specimens showed signs of previous surgery, trauma, abnormal osseous anatomy, or severe osteoarthritis. Multiplanar reconstructions were made using the OsiriX DICOM shareware viewer (www.osirix-viewer.com). The optimal positioning of the baseplate was determined to be 12 mm above the inferior glenoid rim, as described by Kelly *et al.* (9) The optimal baseplate position in the anteroposterior plane was then de-

Received for publication September 28, 2020 ; accepted February 15, 2021.

Address correspondence and reprint requests to Shoji Fukuta, M.D., PhD., Department of Orthopaedic Surgery, National Hospital Organization Kochi National Hospital, Kochi, Japan 781-8555, Japan and Fax : +81-88-843-6385.

terminated according to the template protocol. The baseplate was positioned either anteriorly or posteriorly from the central position, where the central post was contained within the scapular neck (Fig. 1). The distance from the center post to the anterior glenoid rim were measured and identified as an entry point for the baseplate guide pin in the anteroposterior plane.

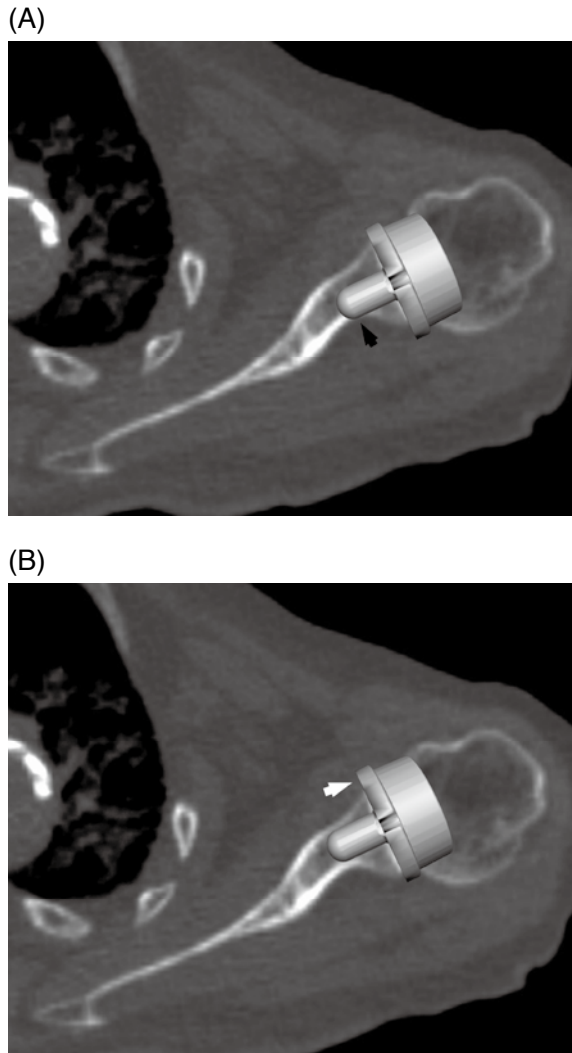


Figure 1. Preoperative planning of the baseplate placement. (A) Baseplate positioning at the anatomic center of a small glenoid introduces risk for posterior cortex breakage (white arrow). (B) Slight anterior placement can avoid this risk, but results in extra overhang of the baseplate anteriorly from the glenoid rim (black arrow).

CT data were exported in Digital Imaging and Communication in Medicine (DICOM) file format and imported into the medical imaging software Mechanical Finder (Research Center of Computational Mechanics, Inc., Tokyo, Japan). A three-dimensional (3D) model of the scapula was constructed by extracting the regions of interest from the imported DICOM data and then saving these in stereolithography (STL) file format. The STL file of the scapula data was processed with the free software Meshmixer (Autodesk, San Rafael, CA), which allows for virtual sectioning of the rendered model intended for 3D printing. Each 3D scapular model was evaluated for file quality, detection performance of bad edges, flipped triangles, and multiple shells and

then repaired to transform the complex geometry of the cancellous bone into a compatible model for printing. The 3D scapular model was then loaded to a 3D printer (Lepton2; GENKEI LLC, Tokyo, Japan). Print parameters were set to a layer thickness of 0.2 mm, filling rate of 15.0%, and filling speed of 58 mm/s. The scale was set at 1 : 1, and polylactic acid was used as the 3D printing material (Fig. 2).

Two sets of 3D scapular models were printed for each specimen. Glenoid height, glenoid width, scapular height, and scapular width measurements were obtained on 3D models and compared with measurements on 3D-CT (Fig. 3).

The glenoid component of a Trabecular Metal Reverse Shoulder System™ (Zimmer Biomet, Warsaw, IN) was implanted in

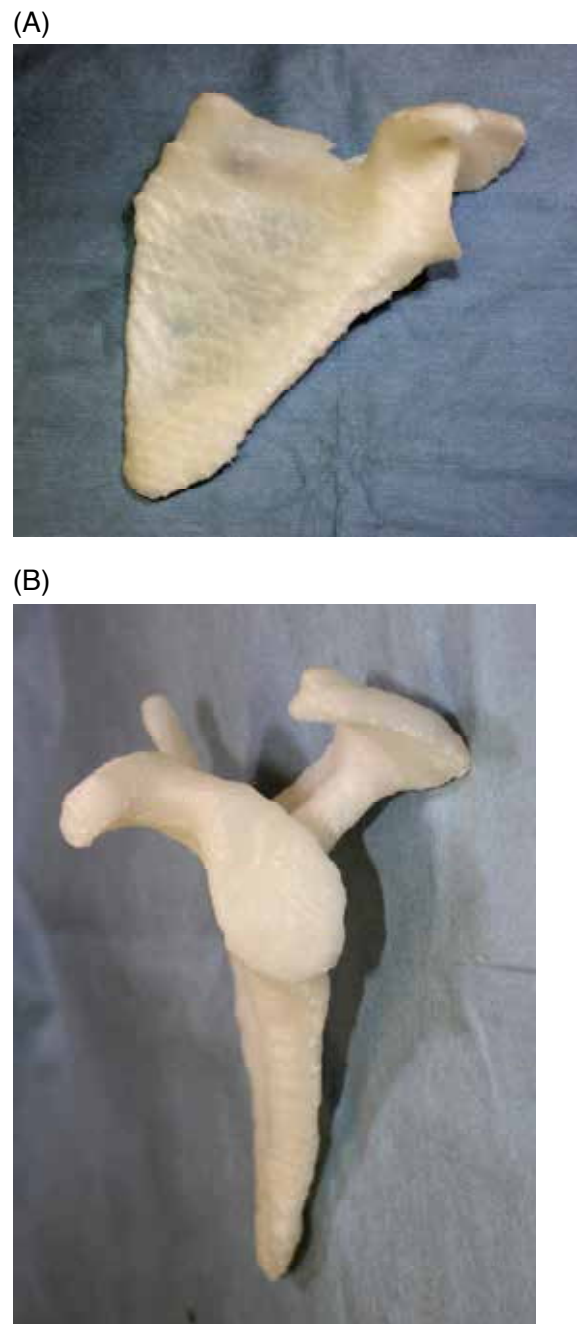


Figure 2. Three-dimensional model of the scapula. (A) Anterior view. (B) Lateral view.

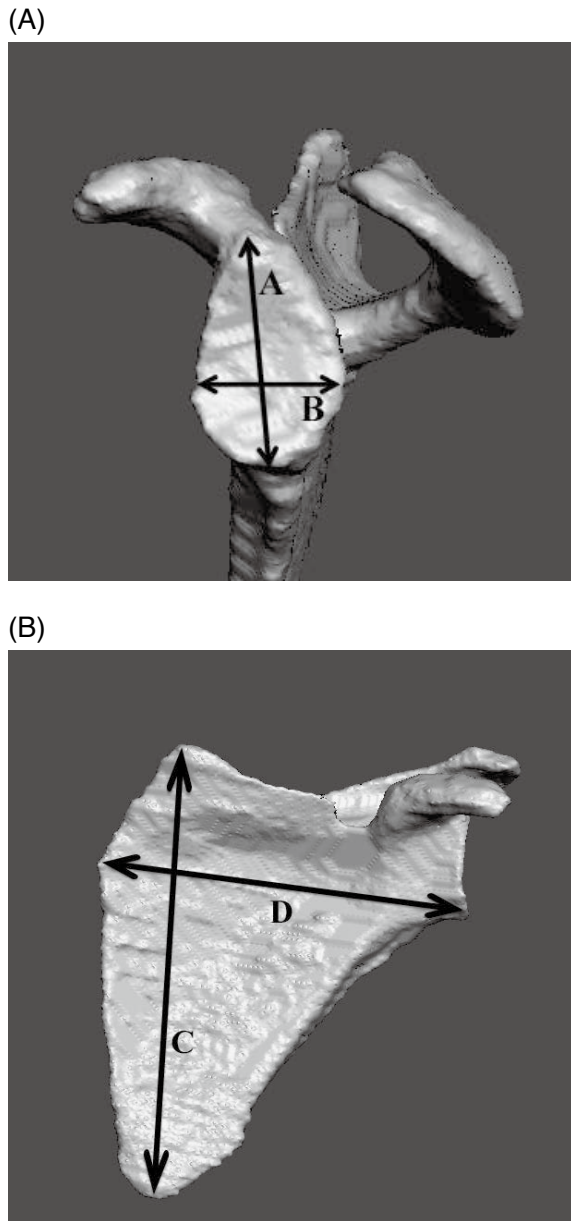


Figure 3. Measurements of glenoid and scapular sizes. A : glenoid height B : glenoid width C : scapular height D : scapular width

all specimens. This glenoid component comprises a 28-mm flat-back baseplate that is affixed to the glenoid with a central post 15 mm in length and 8 mm in diameter, and two locking screws in the superior and inferior positions.

We set up two scenarios of baseplate placement, A and B. In scenario A, the central post of the baseplate was placed on the glenoid surface centrally in the anteroposterior direction, as described in the surgical technique guide provided by the manufacturer. In scenario B, the central post was placed at the point determined by the preoperative template protocol. The entry point of the guide pin was marked with a marker pen and a 2.5-mm guide pin was inserted without any tilt relative to the native glenoid using a unidirectional drill guide. The version of the baseplate was set to match that of the native glenoid. The glenoid surface was reamed using a 28-mm cannulated reamer placed over the guide pin until it flattened. Peripheral reaming was also performed if necessary. The central hole was enlarged using a 7.5-mm drill and the baseplate was inserted until the baseplate was flush with the reamed surface of the glenoid. Then, whether the baseplate post was contained within the glenoid vault was recorded. The overhang of the baseplate from the glenoid rim was measured using calipers.

RESULTS

Glenoid height, width, scapular height, and width were measured on 3D printed models and compared with scapular measurements on CT scans (Table 1). Each measurement on both 3D printed models and CT scans was similar.

In scenario A, the target position of the guide pin was centered in the anteroposterior dimension. The average overhang of the glenoid baseplate was 2.5 ± 1.3 (range, 1.0-4.4) mm from the anterior glenoid edge. The central post was contained within the scapula without cortex breakage in all scapulae (Fig. 4).

In scenario B, the target position of the guide pin was determined by the CT-templating protocol. The average distances from the guide pin position to the anterior glenoid rim was 9.7 ± 1.7 (range, 7.6-11.8) mm (Table 2). Thus, the optimal position of the guide pin was 1.9 ± 1.7 (range, 0.6-3.2) mm anterior in the anteroposterior dimension. The average overhang of the glenoid baseplate was 4.3 ± 1.7 (range, 2.2-6.4) mm from the anterior glenoid edge. The central post drill penetrated the scapular neck posteriorly in 5 scapulae (Fig. 5).

Table 1. Glenoid and scapular size measured on 3D printed models and CT scans

Specimen no.	CT measurements				3D models			
	Glenoid length	Glenoid width	Scapular length	Scapular width	Glenoid length	Glenoid width	Scapular length	Scapular width
1	35.6 mm	25.2 mm	133.3 mm	94.1 mm	34.5 mm	26.9 mm	127.0 mm	93.5 mm
2	25.5 mm	19.3 mm	111.7 mm	84.1 mm	29.7 mm	18.8 mm	114.5 mm	93.5 mm
3	30.7 mm	20.1 mm	111.6 mm	88.9 mm	31.5 mm	21.0 mm	115.0 mm	89.0 mm
4	33.8 mm	24.7 mm	96.0 mm	91.3 mm	34.0 mm	24.5 mm	93.5 mm	89.5 mm
5	29.0 mm	22.8 mm	97.6 mm	92.9 mm	30.0 mm	23.0 mm	98.0 mm	91.0 mm
6	32.3 mm	23.5 mm	113.4 mm	89.2 mm	32.0 mm	23.0 mm	115.5 mm	90.5 mm
7	33.9 mm	26.0 mm	121.4 mm	90.9 mm	32.0 mm	26.0 mm	118.5 mm	91.5 mm
Average	31.5 mm	23.1 mm	112.1 mm	90.2 mm	32.0 mm	23.3 mm	111.7 mm	91.2 mm

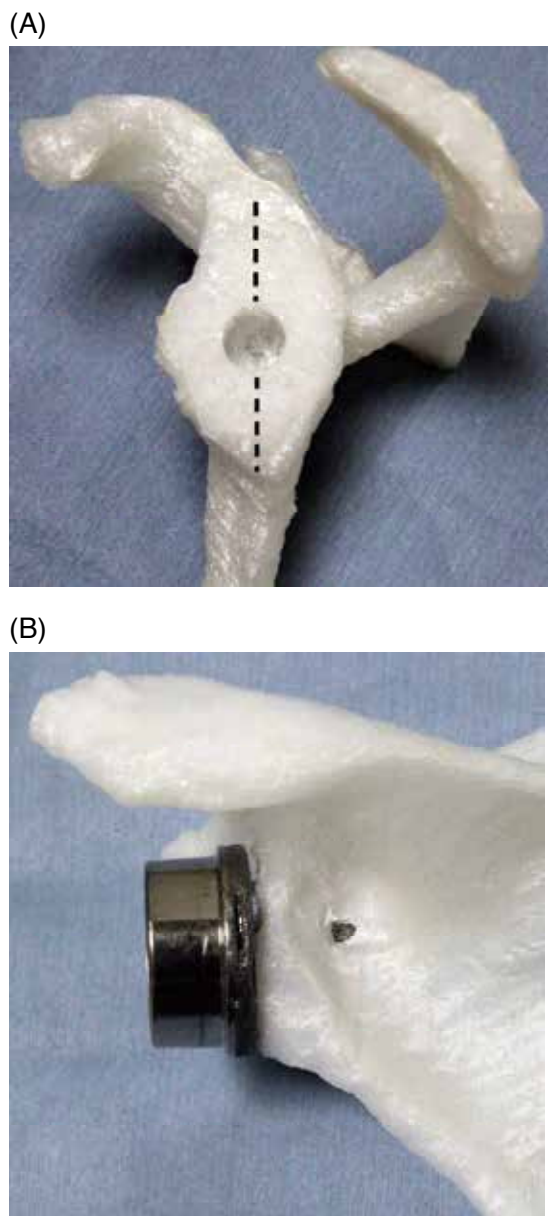


Figure 4. When the baseplate central post was placed centrally on the glenoid surface (A), it penetrated the scapular neck posteriorly in 5 out of 7 scapulae (B).

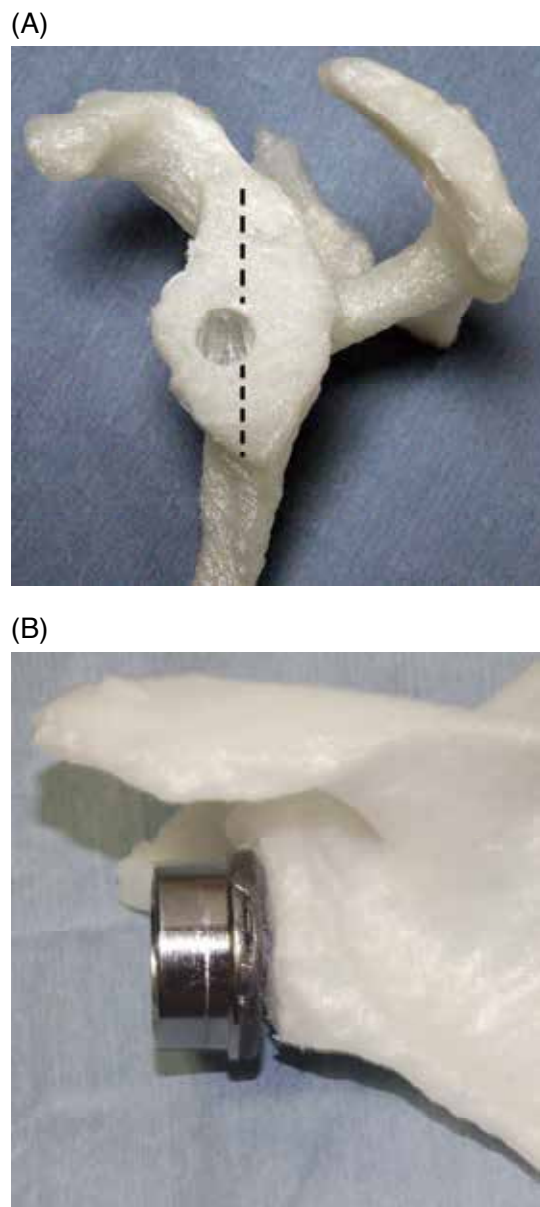


Figure 5. When the baseplate central post was placed anteriorly from the center of the glenoid surface (A), it was contained within the glenoid vault in all scapulae (B).

Table 2. Preoperative planning of the baseplate position

Specimen no.	Senario A		Senario B		
	Position of the guide pin	Anterior overhang of the base plate	Position of the guide pin	Anterior overhang of the base plate	Position of the guide pin from the center of the glenoid
1	12.6 mm	1.4 mm	9.4 mm	4.8 mm	3.2 mm
2	9.7 mm	4.4 mm	7.6 mm	6.4 mm	2.1 mm
3	10.0 mm	4.0 mm	9.5 mm	4.5 mm	0.6 mm
4	12.4 mm	1.6 mm	11.8 mm	2.2 mm	0.6 mm
5	11.4 mm	2.6 mm	7.8 mm	6.2 mm	3.6 mm
6	11.7 mm	2.3 mm	9.7 mm	4.3 mm	2.1 mm
7	13 mm	1.0 mm	11.8 mm	2.2 mm	1.2 mm
Average	11.5 mm	2.4 mm	9.7 mm	4.3 mm	1.9 mm

Position of the guide pin was expressed as the distance from the anterior glenoid rim.

Anterior overhang of the base plate expressed as the distance from the anterior glenoid rim to the anterior edge of the base plate.

DISCUSSION

When inserting RSA implants, the baseplate should be positioned inferiorly and be aligned to the inferior edge of the glenoid to avoid scapular notching. The 12-mm rule proposed by Kelly *et al.* (9) has been widely accepted as a practical recommendation for the ideal location of the pilot hole. Their theory proposes that the baseplate pilot hole be placed 12 mm above the inferior glenoid rim, and slightly posterior from the anatomic center of the glenoid surface.

Although age, sex, and ethnicity of specimens in the study by Kelly *et al.* (9) were unknown, their specimens were similar in size to other published scapular measurements of Caucasians (11, 12, 13). Previous studies analyzing normal scapular geometry and morphology have demonstrated racial differences in glenoid size. Iannotti *et al.* (11) measured the dimensions of the glenoid surface and found an average glenoid height of 39 ± 3.5 mm and a width of 29 ± 3.2 mm. Von Schroeder *et al.* (12) reported that glenoid height and width were 36 ± 4 mm and 29 ± 3 mm, respectively. However, compared with these measurements, Asian shoulders are smaller. Matsumura *et al.* (14) analyzed 160 healthy Japanese shoulders and reported an average glenoid height of 31.5 ± 2.8 mm and glenoid width of 23.1 ± 2.4 mm. Another study in a Japanese population demonstrated that the average glenoid height and width were 33.3 ± 5.3 mm and 25.9 ± 4.3 mm, respectively (15). The glenoid size in the women of our study was close to that reported in these Japanese studies.

In addition to ethnic variations, the glenoid is known to be larger in men than in women. Sex differences in glenoid morphology were not considered when inserting baseplate guide pin at the glenoid surface. In a Korean population, Ji *et al.* (16) noted that insertion of a standard 29-mm baseplate was technically challenging in small-stature patients, especially in small-stature women. For a small glenoid, the standard-sized 29-mm baseplate is larger than glenoid bone stock, which results in insufficient bone-implant contact and anterior and posterior screw fixation. The authors suggested that smaller implants may be required for proportionally small-stature patients.

With increased use of RSA in several countries worldwide including in Asia, some manufacturers have made available baseplates with a diameter < 29 mm. RSA use has thus been increasing, especially in small-stature Asian women. Athwal *et al.* (17) reported favorable short-term outcomes with the Mini 25-mm baseplate in small-stature patients with demonstrable implant safety and effectiveness. Chae *et al.* (18) demonstrated that smaller baseplates improve primary stability and greater impingement-free range of motion in a relatively small glenoid fossa, compared with the regular 29-mm baseplate. Previous studies have focused on proper placement of the standard 29-mm baseplate. It is still unclear whether these guidelines for the 29-mm baseplate can be applied to the Mini 25-mm baseplate.

In this study, we determined the ideal position of the guide pin in a small glenoid fossa using the same CT-templating protocol described by Kelly *et al.* (9) We found that the target position of the guide pin was located slightly anterior from the center of the glenoid, which was contrary to their theory. This discrepancy may be related to the relative height of the CT image used for templating. If the glenoid size is similar to the baseplate size, the shape of the glenoid vault is an isosceles triangle. Conversely, a baseplate positioned 12 mm above the inferior glenoid rim is higher than the center of the glenoid fossa, and the CT slice passes near the spinoglenoid notch. At this level, the glenoid vault is narrow posteriorly. Therefore, shifting the position of the guide pin slightly anteriorly may prevent breakage of the posterior wall of the scapular neck. Anterior shifting of the baseplate leads the anterior overhang from the anterior glenoid edge, which may

cause insufficient fixation of the anterior screw. A biomechanical comparative study demonstrated that the most important screws for glenoid-baseplate fixation were the superior and inferior screws. Anterior overhang of the baseplate exerts less influence on the initial stability of the baseplate. It is unclear how central post perforating the scapular neck affects the initial press-fit fixation of the baseplate. Further biomechanical testing is required to clarify this. There are certain limitations of this study. First, the sample size was small. Second, biomechanical testing was not performed to compare the initial fixation strength of these two scenarios. Third, our specimens had no severe deformity or bony erosions. Kelly *et al.* (9) reported that the 12-mm rule would not apply to scapulae with severe bone defects. On an abnormal glenoid version, the target point may differ from that of this study. Fourthly, shifting of the guide pin position could be applied to only a flat-back baseplate. A round-back baseplate is not suitable for a small glenoid fossa because the baseplate should be placed in the centrally on the glenoid surface.

CONCLUSION

This study demonstrated that shifting the center of the baseplate slightly anterior to the anatomic center is necessary to avoid the posterior cortex of the scapular neck from breaking in small-stature Japanese women. Our results in this Japanese women cohort were contrary to those of Western cadavers described by Kelly *et al.* (9); however, their CT-templating protocol is still useful for obtaining better stability of the glenoid component, even in a small glenoid fossas.

COI DISCLOSURE

Shoji Fukuta : The author, their immediate family, and any research foundation with which they are affiliated have not receive any financial payments or other benefits from any commercial entity related to the subject of this article.

Keizo Wada : The author, their immediate family, and any research foundation with which they are affiliated have not receive any financial payments or other benefits from any commercial entity related to the subject of this article.

Kosaku Higashino : The author, their immediate family, and any research foundation with which they are affiliated have not receive any financial payments or other benefits from any commercial entity related to the subject of this article.

Koichi Sairyō : The author, their immediate family, and any research foundation with which they are affiliated have not receive any financial payments or other benefits from any commercial entity related to the subject of this article.

Yoshihiro Tsuruo : The author, their immediate family, and any research foundation with which they are affiliated have not receive any financial payments or other benefits from any commercial entity related to the subject of this article.

REFERENCES

1. Grammont PM, Baukot E : Delta shoulder prosthesis for rotator cuff rupture. *Orthopedics* 16 : 65-68, 1993
2. Werner CM, Steinmann PA, Gilbert M, Gerber C : Treatment of painful pseudoparesis due to irreparable rotator cuff dysfunction with the Delta III reverse-ball-and-socket total shoulder prosthesis. *J Bone Joint Surg* 87-A : 1476-1486, 2005
3. Boileau P, Watkinson D, Hatzidakis AM, Hovorka I : The

- Grammont reverse shoulder prosthesis : Results in cuff tear arthritis, fracture sequelae, and revision arthroplasty. *J Shoulder Elbow Surg* 15 : 527-540, 2006
4. Martin TG, Iannotti JP : Reverse total shoulder arthroplasty for acute fractures and failed management after proximal humeral fractures. *Orthop Clin North Am* 39 : 451-457, 2008
 5. Rittmeister M, Kerschbaumer F : Grammont reverse total shoulder arthroplasty in patients with rheumatoid arthritis and nonreconstructible rotator cuff lesions. *J Shoulder Elbow Surg* 1 : 17-22, 2001
 6. De Wilde LF, Plasschaert FS, Audenaert EA, Verdonk RC : Functional recovery after a reverse prosthesis for reconstruction of the proximal humerus in tumor surgery. *Clin Orthop Relat Res* 430 : 156-162, 2005
 7. Zumstein MA, Pinedo M, Old J, Boileau P : Problems, complications, reoperations, and revisions in reverse total shoulder arthroplasty : a systematic review. *J Shoulder Elbow Surg* 20 : 146-157, 2011
 8. Nyffeler RW, Werner CM, Gerber C : Biomechanical relevance of glenoid component positioning in the reverse Delta III total shoulder prosthesis. *J Shoulder Elbow Surg* 14 : 524-528, 2005
 9. Kelly JD, Humphrey CS, Norris TR : Optimizing glenosphere position and fixation in reverse shoulder arthroplasty, Part One : The twelve-mm rule. *J Shoulder Elbow Surg* 17 : 589-594, 2008
 10. Jha SC, Fukuta S, Wada K, Higashino K, Amari-Kita R, Tsutsusi T, Goto T, Hamada D, Suzue N, Matsuura T, Nishisho T, Abe M, Takata Y, Sakai T, Nagamachi A, Sairyo K : Optimizing baseplate position in reverse total shoulder arthroplasty in small-sized Japanese females : technical notes and literature review. *J Med Invest* 63 : 8-14, 2016
 11. Iannotti JP, Gabriel JP, Schneck SL, Evans BG, Misra S : The normal glenohumeral relationships : an anatomical study of one hundred and forty shoulders. *J Bone Joint Surg Am* 74 : 491-500, 1992
 12. von Schroeder HP1, Kuiper SD, Botte MJ : Osseous anatomy of the scapula. *Clin Orthop Relat Res* 383 : 131-139, 2001
 13. Churchill RS, Brems JJ, Kotschi H : Glenoid size, inclination, and version : an anatomic study. *J Shoulder Elbow Surg* 10 : 327-332, 2001
 14. Matsumura N, Oki S, Ogawa K, Iwamoto T, Ochi K, Sato K, Nagura T : Three-dimensional anthropometric analysis of the glenohumeral joint in a normal Japanese population. *J Shoulder Elbow Surg* 25 : 493-501, 2016
 15. Shimozone Y, Arai R, Matsuda S : The Dimensions of the scapula glenoid in Japanese rotator cuff tear patients. *Clin Orthop Surg* 9 : 207-212, 2017
 16. Ji JH, Jeong JY, Song HS, Ok JH, Yang SJ, Jeon BK, Kim TG, Moon YS, Kim YS : Early clinical results of reverse total shoulder arthroplasty in the Korean population. *J Shoulder Elbow Surg* 22 : 1102-1107, 2013
 17. Athwal GS, Faber KJ : Outcomes of reverse shoulder arthroplasty using a mini 25-mm glenoid baseplate. *Int Orthop* 40 : 109-113, 2016
 18. Chae SW, Kin SY, Lee H, Yon JR, Lee J, Han SH : Effect of baseplate size on primary glenoid stability and impingement-free range of motion in reverse shoulder arthroplasty. *BMC Musculoskelet Disord* 15 : 417, 2014