

ORIGINAL**Efficacy of the direct grasping technique using pean forceps under fluoroscopy to replace ureteral stents in women**

Yutaro Sasaki¹, Masayuki Takahashi¹, Keisuke Ozaki¹, Kei Daizumoto¹, Yoshiteru Ueno¹, Megumi Tsuda¹, Yoshito Kusuhabara¹, Tomoya Fukawa¹, Yasuyo Yamamoto¹, Kunihsa Yamaguchi¹, and Hiroomi Kanayama¹

¹Department of Urology, Tokushima University Graduate School of Biomedical Sciences, Tokushima, Japan

Abstract : **Purpose :** To evaluate the efficacy of the direct grasping technique using pean forceps under fluoroscopic guidance for ureteral stent replacement in women. **Methods :** Between April 2018 and September 2020, 28 female patients underwent ureteral stent replacements at our facility, and 184 stent replacement procedures were performed. A total of 127 stents were replaced using pean forceps under fluoroscopic guidance (pean forceps group), and 57 stents were replaced using the cystoscope (cystoscopy group). Clinical characteristics and surgical outcomes were compared between the groups. **Results :** All stents were successfully replaced. There was a statistically significant difference in the procedure time between the two groups (median [interquartile range], pean forceps group : 10.8 [8.2–13.9] minutes vs. cystoscopy group : 15.8 [11.1–20.9] minutes, $P < 0.001$). There were no intraoperative complications in either group and no difference in the incidence of postoperative complications (pean forceps group : 1.6% vs. cystoscopy group : 1.8%, $P = 1.000$). Fluoroscopy time was longer in the pean forceps group, although this difference was not statistically significant (pean forceps group : 38.9 [22.6–60.1] seconds vs. cystoscopy group : 33.0 [20.0–48.9] seconds, $P = 0.0558$). **Conclusion :** The direct grasping technique using pean forceps under fluoroscopy may be a beneficial alternative to cystoscopy for ureteral stent replacement in women. *J. Med. Invest.* 68: 326-329, August, 2021

Keywords : ureteral stent replacement, pean forceps, fluoroscopy

INTRODUCTION

Ureteral stents are small tubes inserted into the ureter to treat or prevent a blockage that impedes the flow of urine from the kidney to the bladder. Usually within several months after the first placement, these stents must be removed or replaced to avoid complications such as migration, encrustation, further obstruction, or infection (1). Several methods are used to replace ureteral stents. The conventional method, cystoscopy, involves passing a rigid tube (with a lens and camera at the end) through the urethral sheath, thus painful or uncomfortable for the patient. Cystoscopy is frequently performed using a tube with a large diameter (from 18-Fr to 22-Fr) (2). To overcome the shortcomings of these stent replacement methods, we devised a direct grasping technique using pean forceps under fluoroscopic guidance. Pean forceps are inexpensive, widely available, and thinner than a cystoscope. In this study, we compared the efficacy of cystoscopy with that of the direct grasping technique using pean forceps under fluoroscopic guidance for ureteral stent replacement in women.

PATIENTS AND METHODS*Study population and design*

For this retrospective cohort study, we reviewed the archives of Tokushima University Graduate School of Biomedical Sciences for ureteral stent replacements performed from April 2018 to

September 2020. These procedures were categorized according to the surgical technique employed : either cystoscopy or direct grasping using pean forceps under fluoroscopic guidance. All women who underwent stent replacement at our facility since April 2018 to September 2020 were eligible. Patients who underwent another procedure simultaneously were excluded. All procedures were performed by eight urologists. Patient medical history and anthropometrics were assessed along with the following factors : stent replacement outcome, procedure and fluoroscopy times. The institutional review board approved this study (protocol number 4063), and all patients provided informed consent.

Collection of demographic and clinical data from the medical archive

Data collection was performed between April 1, 2018 and September 30, 2020. As indicated in the archive, all procedures were performed in a fluoroscopic room within the hospital. For stent replacement using pean forceps under fluoroscopic guidance, the general procedure was as follows : the patient was placed in a lithotomy position without anesthesia. Pean forceps (Fig. 1. a) were sterilized by autoclaving. Lidocaine jelly was applied to the forceps, which were gently inserted through the urethra. To guide the path of the forceps, fluoroscopy was used. This imaging technique uses X-rays to obtain real-time moving images of the patient's organs. Under fluoroscopic guidance (Fig. 1. b), the surgeon used the forceps to grasp and remove the distal end of ureteral stent through urethra to external urethral meatus. The surgeon then inserted a guide wire through the ureteral stent to the renal pelvis or intra pelvic/lyceal system, took out the old ureteral stent over the guide wire, slid the new stent over the guide wire, and took out the guide wire at external meatus level while gently sliding the distal end of ureteral stent over the guide wire into the urethra. The fluoroscopic apparatus used was the DynaDirect Winscope 6000 (Toshiba Medical Systems,

Received for publication May 12, 2021 ; accepted July 13, 2021.

Address correspondence and reprint requests to Yutaro Sasaki, M.D., Department of Urology, Tokushima University Graduate School of Biomedical Sciences, 3-18-15, Kuramoto, Tokushima, 770-8503, Japan.

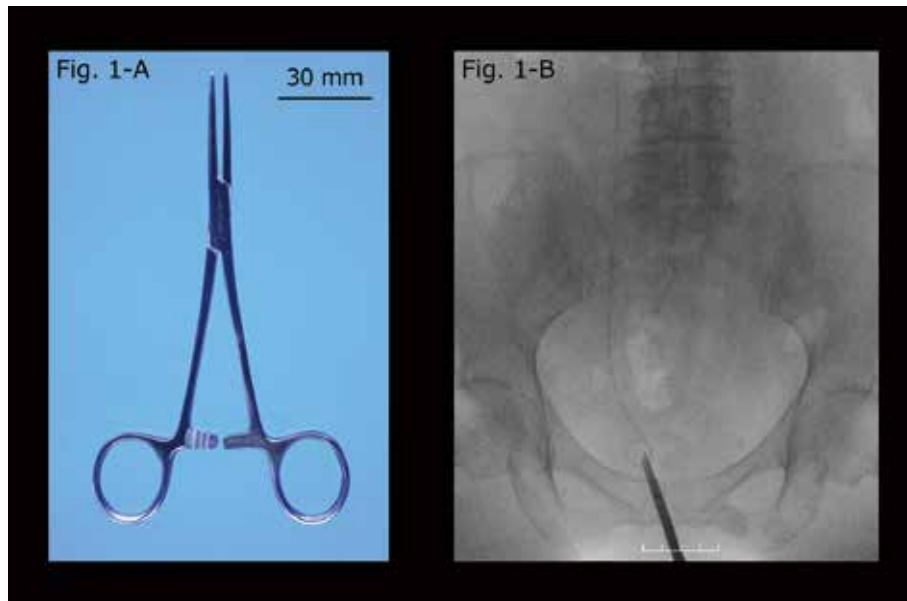


Figure 1.
 a. Pean forceps.
 b. Fluoroscopic image showing pean forceps successfully grasping the stent.

Tochigi, Japan). For stent replacement using cystoscopy, the general procedure was as follows : a 22-Fr rigid cystoscope was inserted through the urethra. Using grasping forceps, the stent was removed under direct view. The surgeon then inserted a replacement stent under fluoroscopic guidance.

Statistical analysis

All continuous variables are expressed as the median (inter-quartile range). While performing our analyses, the t-test was used for continuous variables, and Fisher’s exact test was used for nominal variables. A p-value < 0.05 was considered statistically significant. The EZR (Easy R) version 1.32 was used for statistical analysis (3).

RESULTS

Patient characteristics

During the retrospective study period, 28 female patients underwent stent replacement procedures at our institution. Their anthropometric and clinical characteristics are summarized in Table 1. Their median age was 62 years, and their median BMI was 20.6 kg/m². The etiology of ureteral obstruction was gynecologic cancer in 15 patients, gastrointestinal cancer in 10 patients, benign disease in 2 patients, and urinary cancer in 1 patient. Six patients (21.4 %) had bilateral stent replacements.

Technique outcomes : direct grasping technique using pean forceps under fluoroscopic guidance versus cystoscopy

Among the 28 patients in our study, 184 ureteral stent replacements were performed. Of these, 127 stents were replaced using pean forceps under fluoroscopic guidance (the pean forceps group), and 57 stents were replaced using cystoscopy (the cystoscopy group). Almost all stents were double pigtail stents. In the pean forceps group, all stents were successfully replaced. In the cystoscopy group, all stents were replaced successfully. The surgical outcomes are shown in Table 2. There were no intraoperative complications in either group. Similarly, there

was no difference in the incidence of postoperative complications between the groups (pean forceps group : 1.6% vs. cystoscopy group : 1.8%, P = 1.000). All complications were low-grade urinary tract infections. Three patients experienced a urinary tract infection within 1 week after stent replacement, but this complication resolved after several days of antibiotic infusion therapy. The median procedure time was significantly shorter in

Table 1. Clinical characteristics of female patients who underwent a replacement of ureteral stents

Age, years, median (IQR)	62 (56-73)
BMI, kg/m ² , median (IQR)	20.6 (19.0-21.8)
Etiology, number of patients (%)	
Gynecologic cancer	15 (53.6)
Gastrointestinal cancer	10 (35.7)
Benign disease	2 (7.1)
Urinary cancer	1 (3.6)
Side, number of patients (%)	
Right	11 (39.3)
Left	11 (39.3)
Bilateral	6 (21.4)
Stent type, number of stents (%)	
Double pigtail configuration	33 (97.1)
Loop configuration	1 (2.9)
Stent length (cm), number of stents (%)	
22	5 (14.7)
24	20 (58.8)
26	9 (26.5)
Stent diameter (Fr), number of stents (%)	
6	33 (97.1)
7	1 (2.9)

Table 2. Surgical outcome in female patients who underwent a replacement of ureteral stents

	Overall	Peaen forceps	Cystoscopy	p value
	(n = 184)	(n = 127)	(n = 57)	
Procedure time (min), median (IQR)	12.0 (8.7-16.0)	10.8 (8.2-13.9)	15.8 (11.1-20.9)	< 0.001
Side, number of stents (%)				
Right	63 (34.2)	39 (30.7)	24 (42.1)	
Left	45 (24.5)	26 (20.5)	19 (33.3)	0.00597
Bilateral	76 (41.3)	62 (48.8)	14 (24.6)	
Stent type, number of stents (%)				
Double pigtail configuration	175 (95.1)	122 (96.1)	53 (93.0)	0.462
Loop configuration	9 (4.9)	5 (3.9)	4 (7.0)	
Success of replacement	184 (100.0)	127 (100.0)	57 (100.0)	
Complications				
Active bleeding	0 (0.0)	0 (0.0)	0 (0.0)	
Urinary tract infection	3 (1.6)	2 (1.6)	1 (1.8)	1.000
Fluoroscopy time (sec), median (IQR)	34.0 (20.9-54.1)	38.9 (22.6-60.1)	33.0 (20.0-48.9)	0.0558

the peaen forceps group (10.8 [8.2–13.9] minutes) than in the cystoscopy group (15.8 [11.1–20.9] minutes, $P < 0.001$). The fluoroscopy time was longer in the peaen forceps group (38.9 [22.6–60.1] seconds) than in the cystoscopy group (33.0 [20.0–48.9] seconds, $P = 0.0558$). Eleven patients underwent multiple ureteral stent replacements at both the technique using peaen forceps and using cystoscopy. Figure 2 shows the median procedure time for each technique in 11 patients. The procedure time was reduced by 38.2 % in 9 patients (81.8 %).

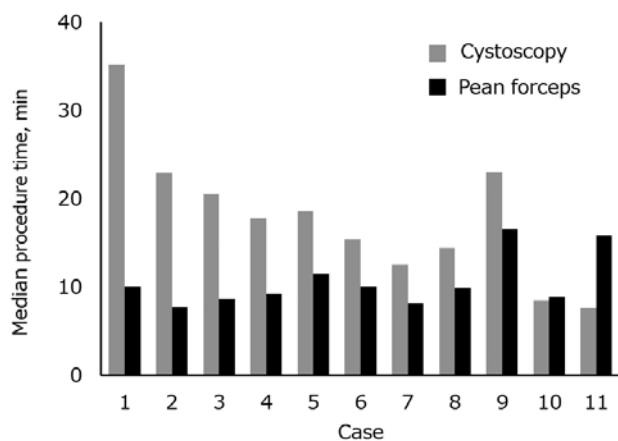


Figure 2. The median procedure time for each technique in 11 female patients.

DISCUSSION

Ureteral stents are small tubes inserted into the ureter to treat or prevent an obstruction that impedes the flow of urine from the kidney to the bladder. Ureteral obstructions may be caused by various conditions, including tumors and kidney stones. To prevent complications such as encrustation and infection, ureteral stents must be removed or replaced within four to six months of insertion (1). Ureteral stent replacement is

a minimally invasive surgical procedure commonly performed by urologists. Cystoscopy, a widely used method for replacing ureteral stents, involves passing a rigid or flexible tube (with a lens and camera at the end) through the urethral sheath, which may be painful for the patient. To address this problem, other stent replacement methods have been reported (2, 4-6). These include the guidewire lasso technique, the snare technique, the crochet hook technique, and the cystoscopic direct grasping technique. The guidewire lasso technique involves inserting a folded guidewire through the urethral sheath to make a lasso. Using this lasso, the ureteral stent is removed under fluoroscopic guidance. The snare technique uses a gooseneck snare instead of a folded guidewire. The guidewire lasso and gooseneck snare techniques require extra equipment and are difficult to perform, so fluoroscopy time is inevitably long. Gadzhiev *et al.* reported that the snare technique, under ultrasound guidance, also requires practice and special skills (5). The cystoscopic direct grasping technique uses forceps located inside the cystoscope. The cystoscopic camera uses x-ray imaging, so fluoroscopy is not needed. The crochet hook technique uses neither cystoscopy nor fluoroscopy: a metal crochet hook is inserted into the urethra (usually five to ten times) until the ureteral stent is grasped and removed. The success rate for this technique is 83.9% (6). When it fails, the procedure is repeated under fluoroscopic guidance and takes additional time to accomplish.

Although some urologists insist that forceps may damage the bladder mucosa, the patients in our study did not suffer from any injury. Our results thus indicate that our newly devised method could be performed safely. One advantage of this method is the elimination of the need to prepare for a cystoscopy and clean up the fluoroscopy room, which reduces the occupation time in the fluoroscopy room relative to methods based on cystoscopy. Therefore, we can perform stent exchanges more rapidly and in more patients. Another advantage of this method is that the patient's pain or discomfort is reduced because a peaen forceps is thinner than a cystoscope. Moreover, this method does not require the clinician to consider an increase in intravesical pressure caused by saline instillation or poor visibility due to cloudy urine.

It is left to the discretion of the surgeon whether to use peaen forceps or cystoscopy. In April 2019, one urologist (Y.S.) introduced the method using peaen forceps at our facility. After that,

the method using pean forceps became widespread rapidly. Therefore, the majority of patients in the cystoscopy group underwent stent replacement during the first half of the study period, while most patients in the pean forceps group were included in the second half. Fluoroscopy was used to remove the stent when using pean forceps. Therefore, the radiation exposure increased and affected the fluoroscopy time. To reduce radiation exposure, it would be useful to investigate the efficacy of stent replacement using pean forceps under ultrasonic guidance.

This study had limitations. It was a single-center, retrospective study. The sample size was small, and all patients were female. The fluoroscopy equipment at our facility could not measure the dose area product (i. e., the total amount of radiation delivered to the patient) nor the air kerma (i. e., the dose of radiation delivered to a specific point on the patient's body).

CONCLUSION

Our results suggest that in women, ureteral stent replacement may be safely performed using the direct grasping technique with pean forceps under fluoroscopic guidance. This method may be a useful alternative to conventional cystoscopy. The efficacy and safety of this technique merits further evaluation.

CONFLICT OF INTEREST

The authors report no conflict of interest.

ACKNOWLEDGEMENT

The authors thank the patients who participated in this study, as well as their families and caregivers, investigators, and site personnel involved.

REFERENCES

1. Wetton CW, Gedroyc WM : Retrograde radiological retrieval and replacement of double-J ureteric stents. *Clin Radiol* 50 : 562-565, 1995
2. Park SW, Cha IH, Hong SJ, Yi JG, Jeon HJ, Park JH, Park SJ : Fluoroscopy-Guided Transurethral Removal and Exchange of Ureteral Stents in Female Patients : Technical Notes. *J Vasc Interv Radiol* 18 : 251-256, 2007
3. Kanda Y : Investigation of the freely available easy-to-use software "EZR" for medical statistics. *Bone Marrow Transplant* 48 : 452-458, 2013
4. Chang RS, Liang HL, Huang JS, Wang PC, Chen MCY, Lai PH, Pan, HB : Fluoroscopic guidance of retrograde exchange of ureteral stents in women. *Am J Roentgenol* 190 : 1665-1670, 2008
5. Gadzhiev N, Brovkin S, Grigoryev V, Dmitriev V, Korol V, Shkarupa D, Pisarev A, Tagirov N, Malkhasyan V, Semeniakin I, Khromov-Borisov N, Petrov S : Ultrasound-guided ureteral stent removal in women. *J Ultrasound Med* 35 : 2159-2163, 2016
6. Kawahara T, Ito H, Terao H, Takuya Y, Takehiko O, Hiroji U, Yoshinobu K, Junichi M : Ureteral stent retrieval using the crochet hook technique in females. *PLoS One* 7, 2012