

CASE REPORT

Idiopathic pneumoperitoneum diagnosed following high-energy motor vehicular trauma : a case report

Yasunari Ubukata, Makoto Sohda, Makoto Sakai, Nobuhiro Nakazawa, Keigo Hara, Akihiko Sano, Hiroomi Ogawa, Ken Shirabe, and Hiroshi Saeki

Department of General Surgery, Graduate School of Medical Sciences, Gunma University, Maebashi, Japan

Abstract : Intra-abdominal free gas is a finding of extra-intestinal gas in the abdominal cavity on radiography or CT, mainly suggesting gastrointestinal perforation and necessitating emergency surgery. Idiopathic pneumoperitoneum is diagnosed when there is no obvious gastrointestinal perforation, but there is presence of free gas in the abdominal cavity with an unidentifiable cause. Herein, we report a case of idiopathic pneumoperitoneum secondary to high-energy trauma following a car rollover accident. A 95-year-old man was transferred to our clinic after a car-to-car rollover accident. He had abrasions on his right upper arm and left abdomen that appeared to be the result of the accident ; however, no other apparent traumatic injuries were noted. There was no pain in the abdomen, and peritoneal irritation symptoms were also not noted. A CT scan showed fine free air. Although idiopathic pneumoperitoneum could not be ruled out, considering the patient's background and the possibility of traumatic small bowel perforation, emergency surgery was performed. A thorough search of the abdominal cavity was performed ; however, the surgery was completed without an obvious perforation site. Idiopathic pneumoperitoneum should be considered as a differential disease in cases who have free air on abdominal CT but clinically lack obvious inflammatory reaction findings. *J. Med. Invest.* 69:155-157, February, 2022

Keywords : *idiopathic pneumoperitoneum, motor vehicular trauma, gastrointestinal perforation*

INTRODUCTION

Intra-abdominal free gas is a finding of extra-intestinal gas in the abdominal cavity on radiography or CT, mainly suggesting gastrointestinal perforation and necessitating emergency surgery. Idiopathic pneumoperitoneum is diagnosed when there is no obvious gastrointestinal perforation, but there is presence of free gas in the abdominal cavity with an unidentifiable cause (1). In this case, the patient's background and findings need to be carefully considered before administration of treatment, rather than simply dismissing gastrointestinal perforation. Here, we report a case of idiopathic pneumoperitoneum secondary to high-energy trauma following a car rollover accident.

CASE REPORT

A 95-year-old man was transferred to our hospital after a car-to-car accident that resulted in a rollover. Abrasions were noted on the right upper arm and left abdomen, which were thought to be due to the accident, but no other obvious traumatic injuries, including seat belt marks, were noted. There was no tenderness or spontaneous pain in the abdomen, and no peritoneal irritation symptoms, such as rebound pain or muscular guarding, were observed. The vital signs of the patient were as follows : body temperature, 37.7°C ; heart rate, 90 beats per min ; blood pressure, 143/96 mmHg ; SpO₂, 95% (room air) ; and respiratory rate, 29 breaths per min. No significant abnormalities, including inflammation, were observed in the blood tests. Computed tomography

(CT) of the whole body showed fine free air mainly in the upper abdomen, but no ascitic fluid accumulation was observed (Figure 1), and there were no other obvious traumatic changes in the thorax and abdomen.

The patient background showed mild emphysema on CT, but no obvious pneumothorax or other serious comorbidities. However, traumatic perforation of the gastrointestinal tract could not be ruled out due to injury ; hence, considering the patient's age, the possibility of idiopathic pneumoperitoneum was informed to the patient and the family. First, perforation of the small intestine was suspected, and the small intestines were thoroughly checked by laparoscopy ; however, no obvious abnormality was found in the intestinal wall or mesentery. Thereafter, the patient was transferred for laparotomy for thorough inspection of perforation in the gastrointestinal tract, including the colon, stomach, and rectum, under direct vision ; however, no obvious perforation was found. No contaminated ascitic fluid or inflammatory findings were observed in the abdominal cavity, and the patient was diagnosed with idiopathic pneumoperitoneum ; the abdomen was sutured. Intraoperatively, the ascitic fluid culture was negative, and there was no postoperative drain opacity or other evidence of drain clouding. Postoperatively, both abdominal findings and blood tests were only reflective of the invasion of laparotomy. However, due to the prolonged paralytic ileus and decreased swallowing function owing to the patient's advanced age, he was transferred to another hospital for rehabilitation.

DISCUSSION

Idiopathic pneumoperitoneum is a relatively rare condition in which imaging studies show intra-abdominal free gas, but no apparent cause can be identified, including perforation of the gastrointestinal tract. Possible causes include the following : intrathoracic, intra-abdominal, female genital origin, and medical causes. The possible causes such as intrathoracic pressure and

Received for publication January 6, 2022 ; accepted March 5, 2022.

Address correspondence and reprint requests to Makoto Sohda, MD, PhD., Department of General Surgery, Graduate School of Medical Sciences, Gunma University, 3-39-22, Showa-machi, Maebashi, Gunma 371-8511, Japan and Fax : +81-27-220-8224.

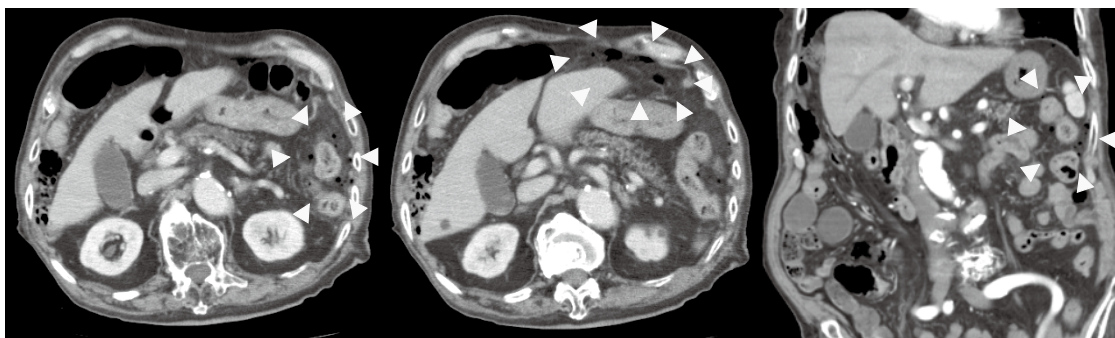


Figure 1. Computed tomography showing free air in the left side of the abdomen, with no obvious ascites in the surrounding area.

mediastinal emphysema (1) of idiopathic pneumoperitoneum may be due to increased intrathoracic pressure or longitudinal emphysema reaching the diaphragm or transabdominal cavity (2); due to pneumatosis cystoides intestinalis, emphysema, or emphysematous cholecystitis (3); result from full fallopian tubes or after sexual intercourse (4); due to laparotomy, endoscopic procedures, or peritoneal dialysis (5); and others (1-9). In addition, in cases where alpha-glucosidase inhibitors or steroids were used, pneumatosis cystoides intestinalis or intestinal emphysema, a condition in which gas is produced in the intestinal wall, has been reported (10-12). However, no intestinal emphysema was observed in the present case; this is because of a transient increase in the intestinal pressure caused by the accident in a very old patient. Intraperitoneal transfer of gas into the abdominal cavity is the most likely cause of idiopathic pneumoperitoneum. A case of varioliform pneumoperitoneum, which is a microperforation without obvious perforation at the time of surgery that is immediately covered by the surrounding tissue, has been reported (13).

A search of Pubmed for “trauma” and “idiopathic pneumoperitoneum” yielded only three case reports, none of which could be confirmed in detail (14-16). In the present case, a thorough search of the entire intestinal tract revealed no evidence of inflammation, and the ascitic fluid culture was negative, which suggested that microperforation was absent. Tani *et al.* (17) and Williams *et al.* (18) have shown that conservative treatment is possible in the absence of inflammatory findings, such as peritoneal irritation, fever, and elevated leukocytes. In the present case, there were no abnormal findings other than inflammation on blood tests, abdominal symptoms, and free air on CT, and the possibility of idiopathic pneumoperitoneum was considered. However, since the patient was in a high-energy trauma situation after the rollover accident and was very old, we were concerned about the possibility of serious complications if his condition worsened after conservative treatment was chosen. Thus, we decided to perform an emergency surgery because he was in a relatively good general condition considering his age. As a result, the diagnosis of idiopathic pneumoperitoneum was made.

There have been no reports of delayed perforation of the gastrointestinal tract in patients with idiopathic pneumoperitoneum, and postoperative drain placement is not mandatory in patients without obvious intraoperative contamination of the abdominal cavity.

In conclusion, although it is difficult to diagnose idiopathic pneumoperitoneum from images and abdominal findings, it should be considered as a differential disease in cases who have free air on abdominal CT but clinically lack obvious inflammatory reaction findings. If preoperative diagnosis is clinically

difficult, laparoscopy and exploratory laparotomy may still be the final diagnostic tools. We should not hesitate diagnostic surgery, because delayed diagnosis will lead to preventable trauma death. Further studies are needed to establish diagnostic criteria for idiopathic pneumoperitoneum and to avoid unnecessary surgery.

CONFLICT OF INTEREST

The authors declare that they have no conflict of Interest

HUMAN/ANIMAL RIGHTS

All procedures followed were in accordance with the ethical standards of the responsible committee on human experimentation (institutional and national) and with the Helsinki Declaration of 1975, as revised in 2008(5).

INFORMED CONSENT

Informed consent was obtained from this patient to be included in the study.

ETHICS APPROVAL AND CONSENT TO PARTICIPATE

This is a case report and does not require review by the Ethics Committee.

Consent was obtained from the patient on a comprehensive consent form, including the case report.

AVAILABILITY OF DATA AND MATERIALS

The dataset supporting the conclusions of this article is included within the article.

AUTHORS' CONTRIBUTIONS

YU collected and analyzed the patient disease data and edited the manuscript. MSO, MSA, NN, KH, and AS performed the operation and managed the perioperative course. HS corrected it as above, and KS and HS approved the final submission of the manuscript. All authors read and approved the manuscript.

ACKNOWLEDGEMENTS

We would like to thank Editage (<https://www.editage.jp/>) for the English language editing.

REFERENCES

1. Gantt CB Jr, Daniel WW, Hallenbeck GA : Nonsurgical pneumoperitoneum. *Am J Surg* 134(3) : 411-4, 1977
2. Mularski RA, Sippel JM, Osborne ML : Pneumoperitoneum : a review of nonsurgical causes. *Crit Care Med* 28(7) : 2638-44, 2000
3. Mularski RA, Ciccolo ML, Rappaport WD : Nonsurgical causes of pneumoperitoneum. *West J Med* 170(1) : 41-6, 1999
4. Aganovic L, Lee YK, Chu PK, Cassidy FH : Recurrent non-surgical pneumoperitoneum due to jejunal diverticulosis. *J Emerg Med* 43(3) : e175-9, 2012
5. Yamana I, Noritomi T, Takeno S, Hashimoto T, Sato K, Shimaoka H, Yamaguchi R, Ishii F, Yamada T, Yamashita Y : Spontaneous pneumoperitoneum due to constipation. *Case Rep Gastroenterol* 9(3) : 361-5, 2015
6. Brown MW, Brown RC, Orr G : Pneumoperitoneum complicating endoscopy in a patient with duodenal and jejunal diverticula. *Gastrointest Endosc* 32(2) : 120-1, 1986
7. Prasannan S, Kumar S, Gul YA : Spontaneous pneumoperitoneum associated with colonic pseudo-obstruction. *Acta Chir Belg* 104(6) : 739-41, 2004
8. Williams TC, Kanne JP, Lalani TA : Jacuzzi jet-induced pneumoperitoneum. *Emerg Radiol* 10(5) : 259-61, 2004
9. Spinelli N, Nfonam V, Marcet J, Velanovich V, Frattini JC : Postoperative pneumoperitoneum after colorectal surgery : expectant vs surgical management. *World J Gastrointest Surg* 4(6) : 152-6, 2012
10. Wada Y, Murayama N, Hirose S, In H, Kuroda T, Ito S, Nakano M, Gejyo F : A case of pneumatosi cystoides intestinalis in a patient with polymyositis and interstitial pneumonia. *Mod Rheumatol* 14(3) : 260-3, 2004
11. Hisamoto A, Mizushima T, Sato K, Haruta Y, Tanimoto Y, Tanimoto M, Matsuo K : Pneumatosi cystoides intestinalis after alpha-glucosidase inhibitor treatment in a patient with interstitial pneumonitis. *Intern Med* 45(2) : 73-6, 2006
12. Suzuki E, Kanno T, Hazama M, Kobayashi H, Watanabe H, Ohira H : Four cases of pneumatosi cystoides intestinalis complicated by connective tissue diseases. *Intern Med* 56(9) : 1101-6, 2017
13. Singer HA : Valvular pneumoperitoneum. *JAMA* 99(26) : 2177-80, 1932
14. Urso G, Palladino E, Andriulo N, Marinelli T, Perrotta N, Loffredo D, Genova G : Spontaneous pneumoperitoneum : a case secondary to thoracic trauma. *Minerva Chir* 62(6) : 497-502, 2007
15. Gardner-Thorpe D, P R Maddox P R : Idiopathic pneumoperitoneum following blunt chest trauma : a case report. *Injury* 30(7) : 511-3, 1999
16. Marouby D, Guyonnet G, Gimbert A, Magne J : Post-traumatic idiopathic pneumopericardium and pneumoperitoneum. *J Chir (Paris)* 126(1) : 24-7, 1989
17. Tani T, Shirai Y, Sasagawa M, Wanifuchi T, Yagi K, Satoh I, Hatakeyama K : Conservative management of idiopathic pneumoperitoneum masquerading as peritonitis : report of a case. *Surg Today* 25(3) : 265-7, 1995
18. Williams NM, Watkin DF : Spontaneous pneumoperitoneum and other nonsurgical causes of intraperitoneal free gas. *Postgrad Med J* 73(863) : 531-7, 1997