

CASE REPORT

An incidentally discovered paraganglioma that caused sinus arrest after resection

Takayuki Sano¹, Takeshi Inoue¹, Naoko Irie¹, Tatsuo Ichikawa¹, Akira Iai¹, Kiyoshi Osa¹, Satoshi Ono¹, Kozo Asanuma¹, Shiori Kaneko¹, Tadao Kuribara¹, Itaru Shigeyoshi¹, Kouta Matsubara¹, Kanako Suzuki¹, Hideki Ishizu², and Keishin Sunagawa²

¹Department of Surgery and ²Department of Pathology, Saitama Cooperative Hospital, Saitama, Japan

Abstract : Paragangliomas are neural-crest-derived nonepithelial neuroendocrine tumors distributed along the parasympathetic and sympathetic nerves. To our knowledge, no studies were reported regarding sinus arrest on day 4 after paraganglioma resection. A 66-year-old female patient with a history of pulmonary vein isolation visited our department for sigmoid colon cancer treatment. Enhanced computed tomography revealed an enhanced small nodule-like lymph node near the root of the inferior mesenteric artery. The patient underwent laparoscopic colectomy with regional lymph node dissection. Postoperatively, paroxysmal atrial fibrillation attacks developed, and the patient resumed oral medication. Additionally, sinus arrest after tachycardia developed. Changing the oral medication could maintain her circulatory dynamics. Pathological examination revealed that differentiated tubular adenocarcinoma infiltrated the submucosa. Immunohistochemically, the excised nodule as a lymph node was considered a functional paraganglioma. Our case indicates that paraganglioma resection and oral medication resumption may contribute to sinus arrest. When arrhythmias affecting the circulation occur perioperatively, the presence of a catecholamine-producing tumor should be considered in addition to cardiac disease. *J. Med. Invest.* 70 : 503-507, August, 2023

Keywords : Paraganglioma, sinus arrest, colon cancer

INTRODUCTION

Paragangliomas are neural-crest-derived nonepithelial neuroendocrine tumors distributed along the parasympathetic and sympathetic nerves. Head-and-neck paragangliomas have been recognized as nonchromaffin, nonfunctional, parasympathetic tumors. By contrast, thoracoabdominal paragangliomas and pheochromocytomas are chromaffin, functional, sympathetic tumors (1). To the best of our knowledge, no studies have been reported regarding sinus arrest on day 4 after paraganglioma resection. Here we present an incidentally discovered paraganglioma that developed sinus arrest after resection.

CASE PRESENTATION

A 66-year-old female patient visited our department for surgical colon cancer treatment. She was aware of the symptoms of paroxysmal headaches, sweating, and pallor. She had a history of paroxysmal atrial fibrillation (PAF) in addition to hypertension and underwent pulmonary vein isolation when she was 65 years old. She was treated with oral amlodipine, bisoprolol, olmesartan, apixaban, and bepridil after pulmonary vein isolation. The blood tests were within the normal range except for the brain natriuretic peptide levels, which had increased to 110 pg/ml. Colonoscopy revealed a 10-mm large semipedunculated tumor in the sigmoid colon (Fig.1). Subsequent pathological examination of the biopsy specimens revealed that the tumor

consisted of differentiated tubular adenocarcinoma. Enhanced computed tomography revealed an enhanced nodule-like regional lymph node near the root of the inferior mesenteric artery, 5 × 6 mm in diameter (Fig. 2); however, the primary lesion remained unclear. There were no findings suggesting distant metastasis. According to the Tumor, Node, Metastasis Staging classification of the Union for International Cancer Control, the preoperative evaluation of this colon carcinoma was cT1c-N1acM0, cStage III-A.

On admission, she had a regular pulse of 56 beats/min and a blood pressure of 96/63 mmHg. Electrocardiogram was normal. The patient underwent laparoscopic colectomy with an

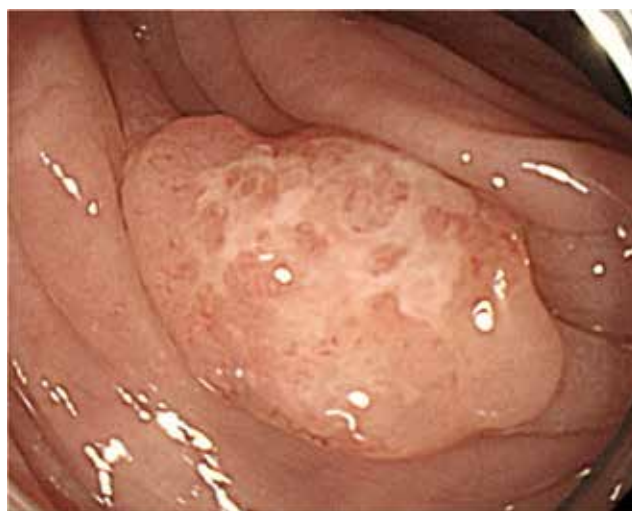

Figure 1. Colonoscopy findings. A 10-mm large semipedunculated tumor in the sigmoid colon.

Received for publication December 21, 2022 ; accepted March 12, 2023.

Address correspondence and reprint requests to Takayuki Sano, MD, Department of Surgery, Saitama Cooperative Hospital, 1317 Kizoro, Kawaguchi-shi, Saitama, Japan and Fax : +81-48-296-7182. E-mail : mz2ue4@bma.biglobe.ne.jp

all-regional lymph node dissection. Intraoperatively, the lesion-like regional lymph node near the root of the inferior mesenteric artery appeared to be a metastatic lymph node with an impression of solidity (Fig. 3). During intraoperative lymph node dissection, a spike in blood pressure of approximately 20 mmHg was noted (Fig. 4). She had a PAF attack on postoperative day 1, she was given oral pilsicainide, and her electrocardiogram became sinus rhythm. However, PAF attacks repeatedly developed; thus, she began to take bisoprolol, bepridil, and apixaban. Moreover, sinus arrest with presyncope repeatedly occurred approximately 5 seconds after tachycardia on postoperative day 4 (Fig. 5). A pacemaker implantation was proposed; however, the patient refused. Bepridil was discontinued, and amiodarone was initiated. Afterward, sinus arrest did not occur. Circulatory dynamics were maintained with medication, and she was discharged 15 days postoperatively.

The postoperative colon cancer evaluation was pT1pN0cM0, pStage I. The resected specimen was a differentiated tubular adenocarcinoma that infiltrated 2000 μ m into the submucosa (Fig.6). Microscopically, large cells grew like a zellballen in the nodule submitted as a lymph node near the root of the inferior mesenteric artery among the excised tissues as lymph nodes of the sigmoid mesocolon. Immunohistochemically, the nodule was positive for chromogranin A. S100 showed a developed sustentacular cell network (Fig. 7). Ki-67 staining indicated

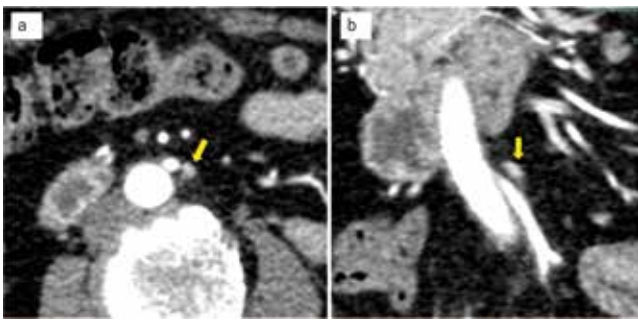


Figure 2. Enhanced computed tomography findings. An axial image (a), a colonic image (b). Enhanced nodule-like regional lymph node near the root of the inferior mesenteric artery (arrow).

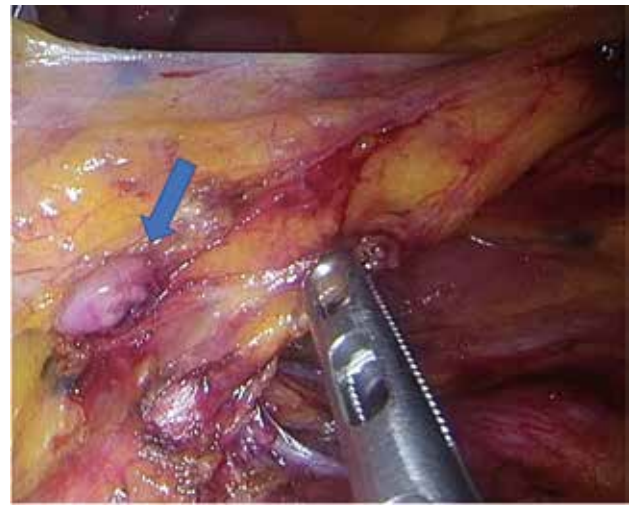


Figure 3. Intraoperative findings. The tumor of paraganglioma resembles a metastatic lymph node with an impression of solidity (arrow).

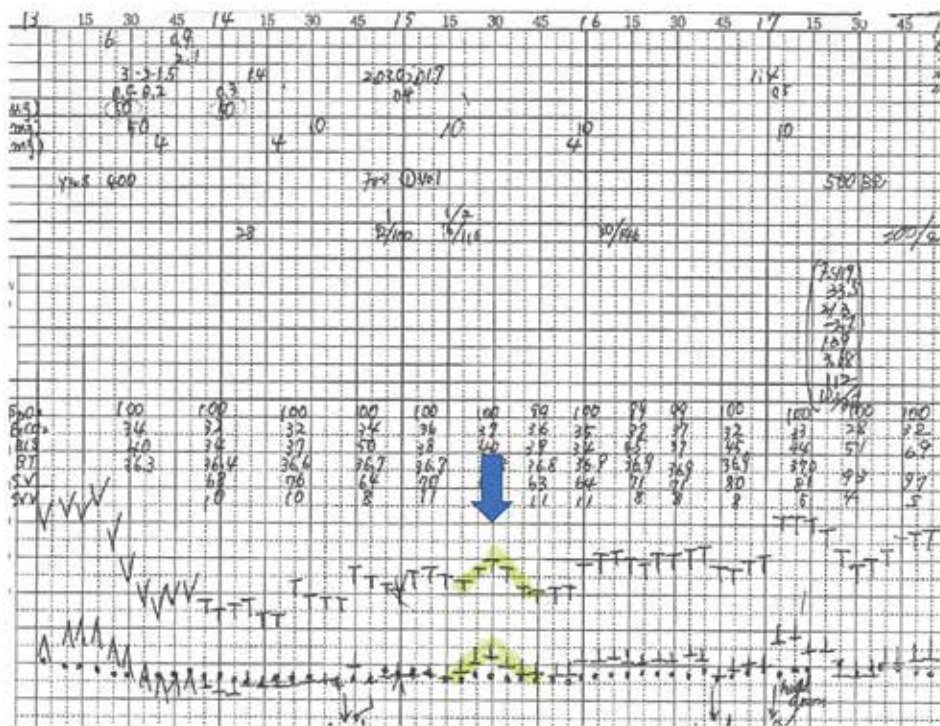


Figure 4. Anesthesia record. Consistent with the timing of lymph node dissection, spike-like blood pressure elevation is noted (arrow).

that the proliferating cells were almost undetectable. Regarding catecholamine synthesis enzymes, tyrosine hydroxylase, dopa decarboxylase, and dopamine beta-hydroxylase were expressed. In contrast, phenylethanolamine N-methyltransferase, which converts norepinephrine to epinephrine, was not expressed (Fig.

8). Since it was not suspected to be a paraganglioma, preoperative blood catecholamine levels were not tested; however, the levels were found to be normal postoperatively. Her symptoms of headache, sweating, and pallor improved postoperatively.




Figure 5. Electrocardiogram findings. Sinus arrest after tachycardia.

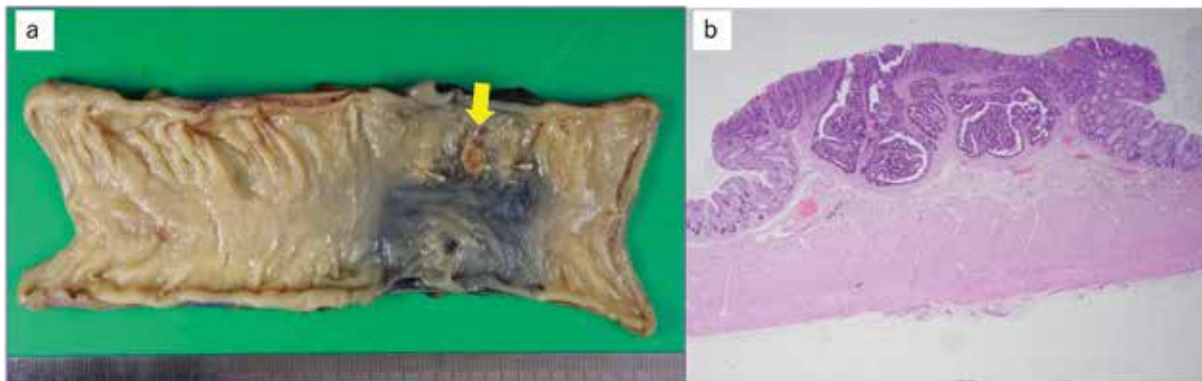


Figure 6. Histopathological findings of resected colon cancer. Macroscopic view (arrow) (a), a lower magnification image of the tumor after hematoxylin–eosin staining (b).

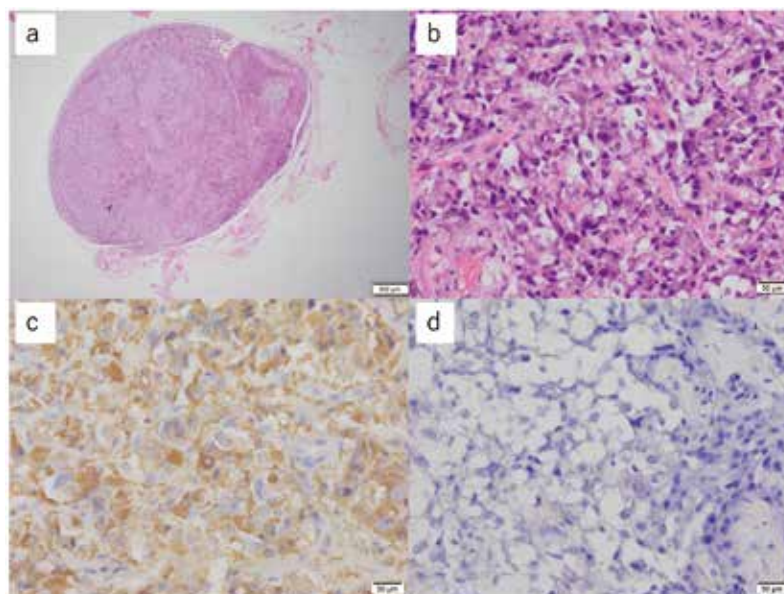


Figure 7. Histopathological findings of resected paraganglioma. A lower magnification image of the nodule after hematoxylin–eosin staining ($\times 12.5$) (a), a higher magnification image ($\times 400$) (b). Immunohistochemical staining is positive for chromogranin A ($\times 400$) (c). S100 shows a developed sustentacular cell network ($\times 400$) (d).

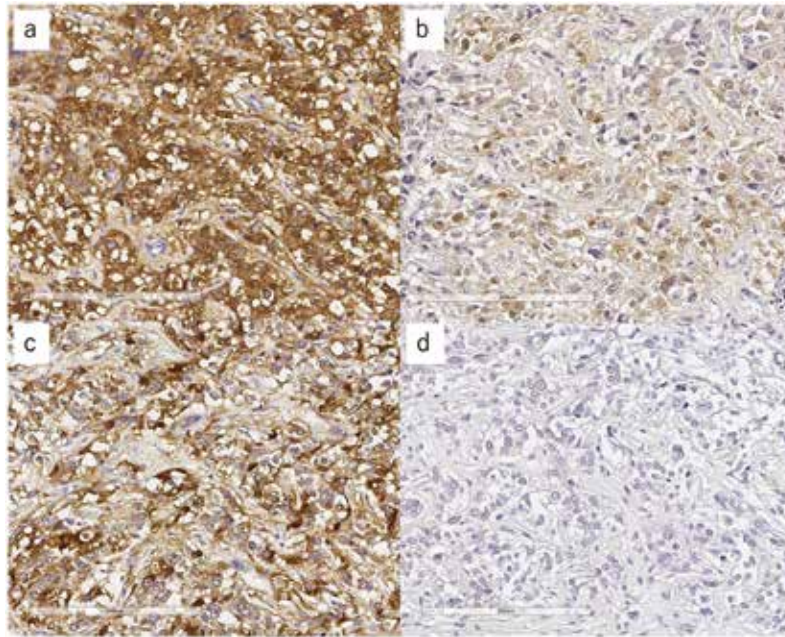


Figure 8. Functional immunohistochemistry of resected paraganglioma ($\times 200$). The tumor shows positive for tyrosine hydroxylase (a), dopa decarboxylase (b), and dopamine beta-hydroxylase (c), and negative for phenylethanolamine N-methyltransferase (d).

DISCUSSION

This case revealed two important clinical suggestions. Sinus arrest can be developed after paraganglioma resection and surgery with lymph node dissection may lead to the diagnosis of paraganglioma.

First, sinus arrest can be developed on day 4 after paraganglioma resection. Several cases reported that patients with pheochromocytoma developed bradycardia, including sinus arrest during the perioperative period (2, 3, 4). There was also a report regarding circulatory failure during the resection of paraganglioma (5). In our case, we managed circulation failure although we did not reach the diagnosis of paraganglioma. Before the pathology diagnosis was made, sinus arrest developed on postoperative day 4, and there were no reports regarding such a timing of sinus arrest after paraganglioma resection. In our case, tyrosine hydroxylase, dopa decarboxylase, and dopamine beta-hydroxylase were expressed. Kimura reported that dopamine beta-hydroxylase is constantly and strongly expressed in pheochromocytoma and paraganglioma regardless of the presence or absence of catecholamine secretion (6). Kimura *et al.* reported that tyrosine hydroxylase is a rate-limiting enzyme for catecholamine biosynthesis and that deficiency of tyrosine hydroxylase is an important feature of extra-adrenal nonfunctioning pheochromocytomas (7). Furthermore, the spike-like increase in blood pressure during lymph node dissection, i.e., during near-tumor manipulation, suggests that catecholamine secretion from the tumor might occur temporarily. The patient originally had paroxysmal headaches, sweating, and pallor and she noticed improvement in these symptoms after surgery. Based on these reports and the facts, it is possible that our case had a functional paraganglioma producing dopamine or norepinephrine; however, epinephrine was not produced.

On the contrary, sinus arrest was reported as a complication of pulmonary vein isolation (8). However, the only time sinus arrest occurred after the patient underwent pulmonary vein

isolation was during the postoperative hospitalization for colon cancer, and no sinus arrest occurred for 2 years thereafter. The patient was preoperatively controlled for PAF with antiarrhythmic agents and beta blockers. Catecholamine secretion could decrease with tumor resection, and the positive chronotropic effect could subsequently decrease. Additionally, the patient resumed oral administration, such as antiarrhythmic. Therefore, tumor resection and oral medication resumption could contribute to sinus arrest. Moreover, bepridil is a multi-channel blocker with a better defibrillation effect than other antiarrhythmic drugs. It exerts a strong defibrillation effect, especially for K channels, because it exerts a blocking effect on I_{Kur} , which is the cardiac ultrarapid activating outward potassium current specific to human atrial myocytes. Bepridil has a stronger inhibitory effect on I_{Kur} than amiodarone; thus, taking amiodarone instead of bepridil improves bradycardia and sinus arrest (9, 10, 11).

Second, surgery with lymph node dissection may lead to the diagnosis and treatment of paraganglioma. Since the 2017 World Health Organization classification, pheochromocytomas and paragangliomas were considered as malignant neoplasms with variable metastatic potential similar to epithelial neuroendocrine neoplasms (12). Surgery is the sole cure for pheochromocytomas and paragangliomas; however, limited biochemical and tumor control of the metastatic disease can be achieved with treatments, such as ^{131}I -metaiodobenzylguanidine treatment, chemotherapy, and radiation (13). In our case, endoscopic findings suggested that the tumor depth reached the submucosa. The frequency of lymph node metastasis is only 10% in pedunculated submucosal invasive colorectal carcinomas with invasion depth $\geq 2000\ \mu\text{m}$ to $<2500\ \mu\text{m}$ (14). However, computed tomography showed a lymph node-like structure with a strong contrast effect near the root of the inferior mesenteric artery. An all-regional lymph node dissection is the standard surgical option for Stage III colon carcinoma according to the Japanese Society for Cancer of the Colon and Rectum Guidelines for the Treatment of Colorectal Cancer; thus, an all-regional lymph

node dissection was performed. Consequently, surgery with lymph node dissection enabled the diagnosis and treatment of paraganglioma in this case.

In conclusion, we reported a rare case of paraganglioma with colon cancer that caused sinus arrest on day 4 after surgical resection. Our case suggests that paraganglioma resection and the resumption of antiarrhythmic drug may contribute to sinus arrest. When arrhythmias affecting the circulation occur post-operatively, the presence of a catecholamine-producing tumor should be considered in addition to cardiac disease.

CONFLICTS OF INTEREST

The authors have no conflicts of interest to disclose and received no financial support for this report.

ACKNOWLEDGEMENTS

We would like to thank Enago (www.enago.jp) for the English language editing.

And we would like to thank Hironobu Sasano, Yuto Yamazaki (Department of Anatomic Pathology, Tohoku University School of Medicine) for conducting the pathological examination.

REFERENCES

- Kimura N, Shiga K, Kaneko K, Oki Y, Sugisawa C, Saito J, Tawara S, Akahori H, Sogabe S, Yamashita T, Takekoshi K, Naruse M, Katabami T: Immunohistochemical expression of choline acetyltransferase and catecholamine-synthesizing enzymes in head-and-neck and thoracoabdominal paragangliomas and pheochromocytomas. *Endocr Pathol* 32(4) : 442-451, 2021
- Yamada Y, Fujiwara H, Banno H, Hikami K, Nakasima M, Tamaki M, Ito N: Complete atrioventricular dissociation and sinus arrest after pheochromocytoma resection. *IJU Case Rep* 3(3) : 108-111, 2020
- Zweiker R, Tiemann M, Eber B, Schumacher M, Fruhwald FM, Lipp R, Lax S, Pristautz H, Klein W: Bradydysrhythmia-related presyncope secondary to pheochromocytoma. *J Intern Med* 242(3) : 249-253, 1997
- Bruch C, Dagres N, Wieneke H, Herborn C, Brandt-Mainz K, Erbel R: Sinus node dysfunction with intermittent sinus arrest and AV-nodal escape rhythm as initial manifestation of pheochromocytoma. *Z Kardiol* 91(1) : 81-87, 2002
- Stiru O, Dragan A, Admache C, Dragulescu PR, Stiru C, Tulin A, Bacalbasa N, Balescu I, Diaconu C, Geana RC, Savu C, Ilescu VA: Abdominal paraaortic paraganglioma: Management of intraoperative hemodynamic emergencies during elective resection procedures (A case presentation). *Exp Ther Med* 21(5) : 543, 2021
- Kimura N: Dopamine β -hydroxylase: an essential and optimal immunohistochemical marker for pheochromocytoma and sympathetic paraganglioma. *Endocr Pathol* 32(2) : 258-261, 2021
- Kimura N, Miura Y, Nagatsu I, Nagura H: Catecholamine synthesizing enzymes in 70 cases of functioning and non-functioning pheochromocytoma and extra-adrenal paraganglioma. *Virchows Arch A Pathol Anat Histopathol* 421(1) : 25-32, 1992
- Takigawa M, Kuwahara T, Okubo K, Takahashi A: Sudden manifestation of sinus arrest nine months after catheter ablation treatment for persistent atrial fibrillation. *J Arrhythm* 31(4) : 238-239, 2015
- Kimura M, Ogawa H, Wakeyama T, Takaki A, Iwami T, Hadano Y, Miyazaki Y, Shimizu A, Matsuzaki M: Cardioversion of amiodarone-insensitive atrial fibrillation by bepridil in heart failure: two case reports. *J Cardiol* 48(6) : 359-365, 2006
- Ford J, Milnes J, Wettwer E, Christ T, Rogers M, Sutton K, Madge D, Virag L, Jost N, Horvath Z, Matschke K, Varro A, Ravens U: Human electrophysiological and pharmacological properties of XEN-D0101: a novel atrial-selective $Kv1.5/I_{Kur}$ inhibitor. *J Cardiovasc Pharmacol* 61(5) : 408-415, 2013
- Wang Z, Fermini B, Nattel S: Sustained depolarization-induced outward current in human atrial myocytes. Evidence for a novel delayed rectifier K^+ current similar to $Kv1.5$ cloned channel currents. *Circ Res* 73(6) : 1061-1076, 1993
- Mete O, Asa SL, Gill AJ, Kimura N, de Krijger RR, Tischler A: Overview of the 2022 WHO classification of paragangliomas and pheochromocytomas. *Endocr Pathol* 33(1) : 90-114, 2022
- Fishbein L: Pheochromocytoma and paraganglioma: genetics, diagnosis, and treatment. *Hematol Oncol Clin North Am* 30(1) : 135-150, 2016
- Kitajima K, Fujimori T, Fujii S, Takeda J, Ohkura Y, Kawamata H, Kumamoto T, Ishiguro S, Kato Y, Shimada T, Iwashita A, Ajioka Y, Watanabe H, Watanabe T, Muto T, Nagasako K: Correlations between lymph node metastasis and depth of submucosal invasion in submucosal invasive colorectal carcinoma: a Japanese collaborative study. *J Gastroenterol* 39(6) : 534-543, 2004