

CASE REPORT

Repeated shunt dysfunction due to Barium allergy that was difficult to differentiate from shunt infection

Asami Kikuchi¹, Shigeomi Yokoya², Hideki Oka², Hiroshi Ohno³, and Akihiko Hino⁴

¹Department of Neurosurgery, Tokyo Women's Medical University Medical Center Adachi, Tokyo, Japan, ²Department of Neurosurgery, Saiseikai Shiga Hospital, Shiga, Japan, ³Department of Intensive Care Unit, Rakuwakai Otowa Hospital, Kyoto, Japan, ⁴Department of Neurosurgery, Otsu City Hospital, Shiga, Japan

Abstract: We encountered a case of repeated shunt dysfunction caused by barium allergy. The patient was a 60-year-old male who underwent ventricular peritoneal shunting for hydrocephalus following subarachnoid hemorrhage due to a ruptured aneurysm; however, it malfunctioned many times. A patch test performed after the third reconstruction was positive for barium. To the best of our knowledge, this is the first case report of shunt malfunction due to barium allergy. The patch test is useful in cases of suspected allergy-related dysfunction. We recommend the introduction of barium into antigen testing using the patch test. *J. Med. Invest.* 70:521-523, August, 2023

Keywords: Shunt dysfunction, barium allergy, shunt infection, hydrocephalus

INTRODUCTION

Ventricular peritoneal shunting (VPS) is a well-established treatment for hydrocephalus and a basic procedure in neurosurgery. Shunt malfunction may occur for a number of reasons, sometimes requiring multiple re-shunting procedures, which is burdensome for both the patient and treating physician. Infection is the most common cause of shunt malfunction, and recent studies described allergic reactions that resulted in aseptic meningitis. Allergic reactions to latex in surgical gloves, ethylene acid to disinfect instruments, and silicone in shunt devices have been reported. (1, 2) However, barium is not known to cause allergic reactions that lead to meningitis and shunt dysfunction.

We herein present a unique case of hydrocephalus after subarachnoid hemorrhage. Shunt dysfunction developed due to barium allergy, which was difficult to differentiate from infection due to repeated fever.

CASE REPORT

First shunting

A 60-year-old man presented with subarachnoid hemorrhage due to a ruptured right anterior communicating artery aneurysm. He showed World Federation of Neurosurgical Societies grade I. Emergency direct clipping was performed. The postoperative period was uneventful. On postoperative day 17, impaired consciousness and enlarged ventricles were noted, and the patient was diagnosed with secondary hydrocephalus. Shunt surgery was performed. On the third day after shunting, fever and impaired consciousness developed, and, thus, spinal fluid was collected from the shunt valve. Cerebrospinal fluid (CSF) findings were 32768/mm³ (92.8% polynuclear cells) and 64.5 mg/dl proteins. Since shunt infection was suspected, the shunt

system was removed on the same day.

There was no redness of the wound, dissection, or obvious pus. CSF and the shunt tube were collected and bacterial cultures were negative.

Fever quickly resolved after the shunt had been removed, and the number of cells in CSF decreased to 316/mm³ on the second day after its removal. Since impaired consciousness persisted due to hydrocephalus, a lumbar drain was placed.

Second shunting

After 27 days of postoperative antibiotic therapy, VPS revision was performed. On the third day after second shunting, fever and impaired consciousness developed and, thus, spinal fluid was collected, which showed an elevated cell count of 5400/mm³ (68.5% polynuclear cells) and 88.2 mg/dl proteins. Since re-infection of the shunt was suspected, it was removed on the same day. There was no redness of the wound, dissection, or obvious pus. Bacterial cultures of the spinal fluid and shunt tube collected at that time were negative.

Fever quickly resolved after shunt removal. The day after shunt removal, an MRI scan of the head showed high-signal DWI deposits in the bilateral ventricles. (Fig. 1) Since infection was suspected, endoscopic irrigation of the ventricle was performed. However, all fungal antibody and CSF culture tests conducted during this period were negative.

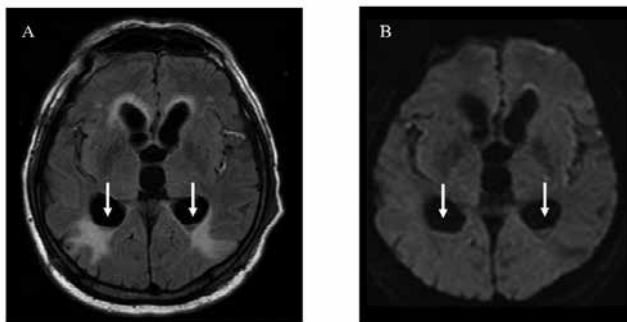


Figure 1. Neuroimaging findings in the present case. MRI shows high-signal deposits (arrows) in the bilateral ventricles on axial (A) FLAIR and axial (B) DWI images.

Received for publication February 2, 2023 ; accepted August 1, 2023.

Address correspondence and reprint requests to Asami Kikuchi, M.D., Department of Neurosurgery, Tokyo Women's Medical University Medical Center Adachi, 4-33-1 Kouhoku, Adachi-ku, Tokyo 123-8558, Japan and Fax : ++81-3-6807-1956. E-mail : kikuchi.asami@twmu.ac.jp

Third shunting

Seventy-four days after the removal of the second shunt, lumboperitoneal shunting (LPS) was performed. Approximately 5 hours after surgery, fever of 38°C developed. The day after surgery, fever persisted and impaired consciousness was observed; therefore, spinal fluid was extracted from the valve, which showed a high cell count of 3100/mm³ (71% polynuclear cells) and 125 mg/dl proteins. We removed the LPS and fever rapidly resolved.

Fourth shunting

Since bacterial culture tests had been negative and the time until the onset of fever decreased following shunting each time, we concluded that infection was not the cause of shunt dysfunction. The recurrence of meningitis or ventriculitis was unlikely in this short time period; therefore, an allergic reaction to the shunt tube was suspected.

A skin patch test was performed on the shunt tube containing silicone, and although there was an irritant reaction, it was negative each time according to the International Contact Dermatitis Research Group criteria. A patch test using the shunt tube containing a small amount of silicone in addition to barium showed a positive reaction, leading to a diagnosis of shunt dysfunction due to barium allergy. A barium-free shunt catheter (Translucent Catheter, Japan Medtronic) was used and VPS was performed. The patient was transferred to a rehabilitation hospital 207 days after the initial surgery. Shunt dysfunction has not occurred in the 7 years since surgery.

DISCUSSION

We encountered a case of barium allergy, which was difficult to differentiate from shunt infection, as a cause of repeated shunt dysfunction. In the present case, after the shunt tube was implanted, the patient repeatedly developed fever and impaired consciousness; however, there were no findings to indicate inflammation, such as redness and tenderness, or an allergic reaction, including a skin rash and pruritus, on the skin where the shunt tube ran, which suggested shunt infection. Various cultures were negative and aseptic meningitis was suspected, with fever developing more rapidly after surgery, which prompted us to suspect allergy. The course of clinical symptoms is shown in Fig. 2.

The results of the present case suggest barium allergy as a cause of shunt dysfunction. To the best of our knowledge, this is the first case report of barium allergy in VPS. Barium is a relatively safe and versatile substance that is mainly used as a gastrointestinal contrast agent. The most frequently reported area of barium complications is gastrointestinal barium angiography, with reports of barium infiltrating the mucosa of the venous plexus and causing a state of shock. (3)

In the field of neurosurgery, there have also been case reports of shunt dysfunction caused by barium in pediatric shunts. In some cases, barium sulfate in the shunt catheter calcified over time, causing it to tear. (4, 5) Therefore, the Translucent catheter (Medtronic Japan), which contains only a small amount of barium sulfate, is now available. This catheter was used in the present case.

Previous studies reported latex allergy (1) and silicone allergy (2) as causes of shunt dysfunction and aseptic meningitis. An increase in eosinophils in CSF or a granulomatous reaction was

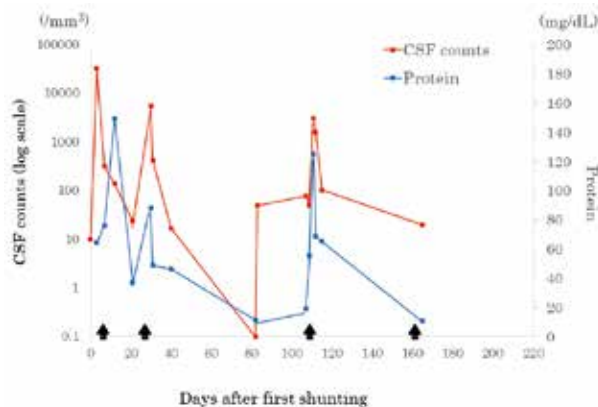


Figure 2. Changes in the cerebrospinal fluid (CSF) cell count and protein levels. Triangles indicate the number of cells. Circles indicate protein levels in spinal fluid. Large arrows on the graph indicate revision surgeries for ventricular peritoneal shunting (VPS) and lumboperitoneal shunting (LPS).

identified as a cause of the obstruction; however, it was also noted that the former may not occur in some cases. Although an increase in CSF eosinophils was not observed in the present case, the cell count (polynuclear cell predominance) was clearly elevated. Since the patch test was positive, it is clear that our patient had a delayed allergic reaction.

It is also possible that the patient became “sensitized” after the first and second shunts, and that the third shunt caused a stronger and immediate allergic reaction.

Inflammatory precipitates from aseptic meningitis have been suggested to obstruct the shunt catheter after the valve. (2). Another study reported more protein deposits on the occluded catheter surface and higher levels of autoantibodies to proteins deposited on the shunt surface. (6) These findings suggest an immunological response to antigens present on the shunt surface, which may play an important role in shunt dysfunction.

We were unable to distinguish whether the immunological changes observed in the present case were directly induced by barium allergy or inflammatory changes due to aseptic meningitis; therefore, we attributed the deposits in the ventricles to either of these factors.

The results of the present case also showed the utility of a patch test to identify allergy. Furthermore, it is useful to perform a patch test using barium as the suspected drug. The introduction of barium as an antigenic specimen in the patch test is recommended. Barium has been used universally in the gastrointestinal field for many years as a substance that is safe for living organisms. It is a component of shunt tubing, albeit in small quantities, and an indispensable material for ensuring X-ray impermeability.

In addition to silicone and barium, other materials for catheter tubing include stainless steel, tantalum, polypropylene, and polytetrafluoroethylene (PTFE). Stainless steel and tantalum do not remain in the body. Polypropylene is less allergenic and PTFE is used to reduce allergenicity, neither of which are causative suspects for allergy. Therefore, we suggest the preferential introduction of barium as a suspect substance.

CONCLUSION

When a patient develops aseptic meningitis after shunting

surgery, as in the present case, allergic reactions need to be suspected, and if silicone or latex is ruled out, barium needs to be considered in the early diagnosis.

CONFLICT OF INTEREST DISCLOSURE

The authors have no personal or institutional interests in the drugs, materials, or devices described in this manuscript.

ACKNOWLEDGMENTS

The authors are thankful to Dr. Mikhail Chernov and Dr. Sumiko Ishizaki for their help during the preparation of this manuscript for publication.

REFERENCES

1. Ellis MJ, Kazina CJ, Del Bigio MR, McDonald PJ : Treatment of recurrent ventriculoperitoneal shunt failure associated with persistent cerebrospinal fluid eosinophilia and latex allergy by use of an "extracted" shunt. *J Neurosurg Pediatr* 1(3) : 237-239, 2008
2. Kambara M, Miyazaki T, Yoshikane T, Sugimoto K, Akiyama Y : A Case of Repeated Shunt Malfunctions with Eosinophilic Meningitis Caused by Silicone Allergy. *No Shinkei Geka* 42(12) : 1125-1130, 2014
3. Javors BR, Applbaum Y, Gerard P : Severe allergic reaction : an unusual complication of barium enema. *Gastrointest Radiol* 9(4) : 357-358, 1984
4. Sharma RK, Takagi K, Yamada Y, Kawase T, Kato Y : Patent Persistent Fibrous Tract in a Patient with Disconnected Lumboperitoneal Shunt. *Asian J Neurosurg* 14(3) : 935-937, 2019
5. Hirose M, Tsutsumi K, Kawahara I, Matsuo Y, Yokoyama H : Fracture of a Ventriculoperitoneal Shunt potentially due to Calcification of the Distal Catheter an Adult patient. *Jpn J Neurosurg* 12 : 753-756, 2003
6. VandeVord PJ, Gupta N, Wilson RB, Vinuya RZ, Schaefer CJ, Canady AI, Wooley PH : Immune reactions associated with silicone-based ventriculo-peritoneal shunt malfunctions in children. *Biomaterials* 25(17) : 3853-386, 2003