

## OTHERS

# A novel computed tomography-based three-column MLP classification of intertrochanteric fracture

Qi-Long Jiang<sup>1</sup>, Yan Li<sup>2</sup>, Xin-Wen Bai<sup>1</sup>, Yu Deng<sup>1</sup>, Hao Hong<sup>1</sup>, Jun Li<sup>1</sup>, Yong Cao<sup>3</sup>, and Xiao-Yu Peng<sup>3</sup>

<sup>1</sup>Department of Orthopaedic Surgery, Chongqing Orthopedic Hospital Of Traditional Chinese Medicine, Chongqing, China, <sup>2</sup>Central Sterile Supply Department, Chonggang General Hospital, Chongqing, China, <sup>3</sup>Department of emergency, Chongqing Orthopedic Hospital Of Traditional Chinese Medicine, Chongqing, China

**Abstract :** **Objectives :** The aim of the present study was to introduce a novel three-dimensional computed tomography (3DCT)-based three-column classification (named “MLP classification system”) of intertrochanteric fractures and evaluate its reproducibility and reliability. **Methods :** From September 2020 to September 2022, a total of 258 consecutive patients (60 male, 198 female ; mean age 81.3 years) with intertrochanteric fractures were included in this study. The fracture in each case was assessed using a novel three-dimensional computed tomography-based three-column classification. Two examiners tested the intra and inter-observer reliability of this new classification system using kappa variance. **Results :** The intertrochanteric region was divided into the medial column, lateral column, and posterior column. Intertrochanteric fractures were documented as M<sub>0/1/2</sub>L<sub>0/1/2/3</sub>P<sub>0/1/2/3</sub>. All fractures were classifiable into the new classification system. The intra-observer kappa values were 0.91 and 0.89, while the inter-observer kappa value was 0.82, both indicating almost perfect reliability. **Conclusion :** This novel 3DCT-based MLP classification system for intertrochanteric fractures is comprehensive, and reproducible with good agreement. It is based on proximal femur biomechanic characteristics and traumatic mechanism, contributing to formulating more reasonable treatment protocols involving various late-model internal fixation devices. *J. Med. Invest.* 70 : 524-529, August, 2023

**Keywords :** Intertrochanteric fracture, Computed tomography, Classification system

## INTRODUCTION

Classification of femoral intertrochanteric fractures is usually based on plain X-ray findings using the Evans, Jensen, or AO/OTA classification system (1-3). However, conventional two-dimensional classification systems are inefficient in getting detailed information to formulate optimal treatment protocols. According to literature published recently, although scholars have proposed several classification systems based on three-dimensional computed tomography, these systems are mainly built based on morphological patterns of fracture fragments, without the involvement of proximal femoral biomechanical characteristics and traumatic mechanism (4-6). Moreover, the consistency and reliability are relatively vulnerable to using these classification methods (3, 7).

In the management of intertrochanteric fractures, cephalomedullary nails have been deemed to be the mainstay of internal fixation options with the advantages of small incisions, minimal invasion, and less blood loss (8). However, inadequate fracture reduction and fixation are associated with high incidences of postoperative complications such as nonunion and cut out of the lag screw or blade (9-11). Based on the biomechanical characteristics and fracture patterns of the proximal femur, various late-model internal fixation devices have been designed for stability augmentation (12-16). It remains confusing to use these classification systems to formulate optimal therapeutic options and sequential rehabilitation schedules (17). Therefore, the present

study was conducted to propose a novel three-dimensional computed tomography-based three-column classification of intertrochanteric fracture and to assess the inter and intra-observer reliability, meanwhile, to optimize device choice of fixations.

## MATERIAL AND METHODS

The study was approved by our institutional review board. Written informed consent was obtained from all subjects.

### *The definition of three columns*

According to the biomechanical characteristics of the proximal femur, three columns were defined as the medial column, lateral column, and posterior column (Figure 1). The definitions and demarcation between columns are described as follows : 1) The medial and lateral columns were classified on the basis of pressure trabecular bone and tension trabecula of the proximal femur (18). This is mainly due to the difference in stress distribution on the proximal femur in the process of walking. Thus, the anterior demarcation line between the medial and lateral columns was drawn in an arc from the middle femoral neck to the middle shaft. 2) Regarding the medial column versus the posterior column, the demarcation line was drawn vertically across the anterior edge of the lesser trochanter (LT) base. 3) The demarcation line of the lateral and posterior columns originated from the anterior edge of the gluteus medius attachment, and ran obliquely to the edge of the vastus lateralis ridge. In other words, the greater trochanter (GT) was divided into two parts. The anterior part was classified into the lateral column, while the posterior part was classified into the posterior column. This is because the gluteus medius and gluteus minimus are comprised of compartments and inserted into the posterior lateral ridge and anterolateral ridge of the greater trochanter (GT)

Received for publication January 12, 2023 ; accepted April 18, 2023.

Address correspondence and reprint requests to QiLong Jiang, Department of Orthopaedic Surgery, Chongqing Orthopedic Hospital Of Traditional Medicine, Chongqing, China, No. 9, Jiefang West Road, Chongqing, 400010, China and E-mail : jys19870607@qq.com

separately, GT fractures frequently arise as a consequence of excessive tension of gluteus medius (19).

The medial and lateral columns work as a lever and bear compressive stress and tensile stress respectively. In this classification, the medial column was subdivided into  $M_0$  (intact),  $M_1$  (simple fracture), and  $M_2$  (wedge or multifragmentary fracture). The lateral column was subdivided into  $L_0$  (intact),  $L_1$  (anterior part of greater trochanter),  $L_2$  (extension between superior and

inferior femoral neck), and  $L_3$  (below femoral neck fundus). The posterior column is composed of the posterior part of GT, LT, and base. This column mainly serves as the attachment site of hip muscles including the gluteus medius and rotator muscles. It was subdivided into  $P_0$  (intact),  $P_1$  (posterior part of GT),  $P_2$  (LT), and  $P_3$  (involvement of both GT and LT). As a consequence, an intertrochanteric fracture can be documented as  $M_{0/1/2}L_{0/1/2/3}P_{0/1/2/3}$  (Figure 2 and Table 1).

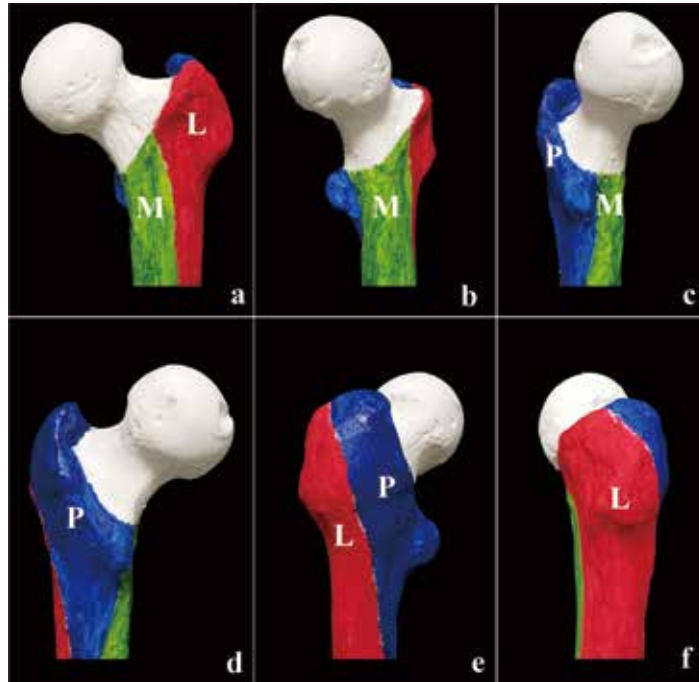


Figure 1. Appearance of Three-column MLP classification of proximal femur. M, medial column (Green area) ; L, lateral column (Red area) ; P, posterior column (Blue area). a-f present circumferential views with rotation.

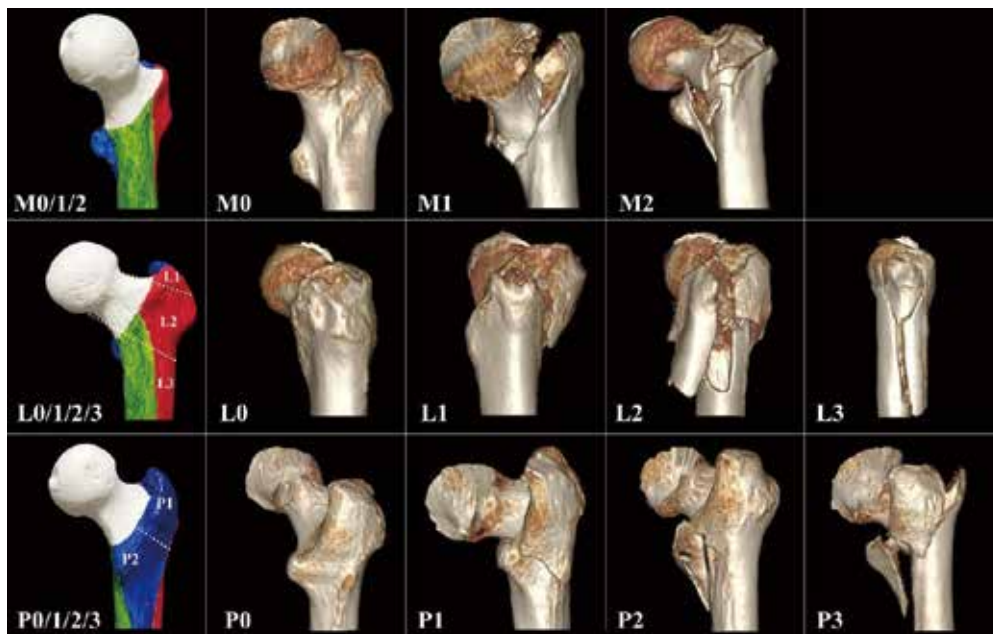

Figure 2. Actual images of three-dimensional computed tomography (3D-CT) in each subtype. A intertrochanteric fracture is characterized as  $M_{0/1/2}L_{0/1/2/3}P_{0/1/2/3}$ . M, medial column (Green area) ;  $M_0$ , intact wall ;  $M_1$ , simple fracture ;  $M_2$ , multifragmentary fracture. L, lateral column (Red area) ;  $L_0$ , intact wall ;  $L_1$ , proximal portion fracture ;  $L_2$ , intermediate portion fracture ;  $L_3$ , distal portion fracture. P, posterior column (Blue area) ;  $P_0$ , intact wall ;  $P_1$ , GT fracture ;  $P_2$ , LT fracture ;  $P_3$ , GT + LT fracture.

Data collection and analysis

This study included 258 consecutive patients who were admitted to our hospital with an intertrochanteric fracture over 2 years from September 2020 to September 2022. Patients with pathologic fractures were excluded. Both plain X-rays and 3DCT-based reconstruction were performed for all study participants. Two orthopedic surgeons (a senior orthopedic surgery resident and an experienced consultant orthopedic surgeon) classified these fracture imaging independently. The first assessment was performed immediately following the CT examination while the second assessment was eight weeks later. The kappa coefficient was used to determine the inter-observer reliability (initial responses of all the evaluators) and intra-observer reliability (the same evaluator's responses between two evaluations with an interval of eight weeks). Statistical analysis was performed using SPSS version 25.0 (SPSS Inc., Chicago, IL, USA). All results are expressed with 95% confidence intervals, generated by 1000 bootstrapping replications ( $\alpha = 0.05$ ).

RESULTS

We studied 258 patients (198 female and 60 male), with a median age of 81.3 years (ranging from 36 to 99 years old). All the fractures were classifiable into the new classification system. The frequency distribution of fracture subtypes is listed in Table 2. By using the three-dimensional classification system in our study, the intra-observer kappa values were 0.91 (JL) and 0.89 (HH), indicating almost perfect reliability, and the inter-observer kappa value was 0.82, indicating almost perfect reliability. The reproducibility and reliability of this novel classification system appeared to be superior to several reported systems(3-7, 20, 21). A comparison between intra and inter-observer reliability in several classification systems is listed in Table 3.

The classification of lateral and posterior columns presented perfect consistency between intra- and inter-observers. For the medial column, there were 19 cases (7.4%) in which the classification was not consistent between the two examiners. The most common reason for disagreement was the fracture line running across the posterior and medial columns, leading to confusion in classifying M<sub>1</sub> or M<sub>2</sub>.

Table 1. The definition of subtypes in each column. A intertrochanteric fracture is characterized as M<sub>0/1/2</sub>L<sub>0/1/2/3</sub>P<sub>0/1/2/3</sub>.

Column	The definition of subgroups			
	M <sub>0</sub>	M <sub>1</sub>	M <sub>2</sub>	
Medial column	intact wall	simple fracture	multifragmentary fracture	
	L <sub>0</sub>	L <sub>1</sub>	L <sub>2</sub>	L <sub>3</sub>
Lateral column	intact wall	proximal portion fracture	intermediate portion fracture	distal portion fracture
	P <sub>0</sub>	P <sub>1</sub>	P <sub>2</sub>	P <sub>3</sub>
Posterior column	intact wall	GT fracture	LT fracture	GT + LT fracture

GT, greater trochanter ; LT, lesser trochanter.

Table 2. Frequency distribution of fracture subtypes in this study and corresponding treatment recommendation.

Fracture type	n (%)	Proposed Treatment modality
M <sub>0</sub> L <sub>0</sub> P <sub>1/2</sub>	11 (4.2%)	Conservative treatment
M <sub>0</sub> L <sub>1</sub> P <sub>0/1/2</sub>	6 (2.3%)	Conservative treatment/fixation of LT
M <sub>1</sub> L <sub>0/1</sub> P <sub>0/1</sub>	92 (35.7%)	Short cephalomedullary nails
M <sub>1</sub> L <sub>0/1</sub> P <sub>2/3</sub>	103 (39.9%)	Short cephalomedullary nails, with/without fixation of LT
M <sub>1</sub> L <sub>2</sub> P <sub>0/1</sub>	2 (0.7%)	Long cephalomedullary nails, with/without lateral column reconstruction
M <sub>1</sub> L <sub>2</sub> P <sub>2/3</sub>	21 (8.1%)	Long cephalomedullary nails + lateral column reconstruction + fixation of posterior column
M <sub>1</sub> L <sub>3</sub> P <sub>0/1/2/3</sub>	14 (5.4%)	Long cephalomedullary nails + lateral column reconstruction, with/without fixation of posterior column
M <sub>2</sub> L <sub>0/1/2/3</sub> P <sub>0/1/2/3</sub>	9 (3.5%)	Medial column support + cephalomedullary nails, with/without lateral and posterior column reconstruction

**Table 3.** Comparison between intra and inter-observer reliability in several classification systems.

Classification system (study)	Intra-observer kappa value	Inter-observer kappa value
AO/OTA-main group (Yıldırım <i>et al.</i> )	0.74	0.70
AO/OTA-subgroup (Yıldırım <i>et al.</i> )	0.49	0.44
Evans- Jensen system (Yıldırım <i>et al.</i> )	0.48	0.50
Tronzo system (Yıldırım <i>et al.</i> )	0.53	0.55
Boyd-Griffin system (Yıldırım <i>et al.</i> )	0.66	0.57
Wada system (Wada <i>et al.</i> )	0.88	0.70
Tang system (BoYin <i>et al.</i> )	0.63	0.64
MLP system (Current study)	0.91 / 0.89	0.82

## DISCUSSION

In the process of standing and walking, the human hip joint bears 2.3–2.8 times the weight of gravity (22). The trabecular bone at the proximal femur is distributed regularly and orderly. Pressure trabecular bone and tension trabecula gradually formed, which are similar to a lever system. The medial wall, acting as a fulcrum, bears compressive stress (18). In the management of intertrochanteric fractures, effective medial buttress will make a valuable contribution towards reducing the occurrence of postoperative complications (e.g. implant failure and coxa vara) (16). According to the degree of stability, we divided the medial column into intact wall ( $M_0$ ), simple fracture ( $M_1$ ), and multifragmentary fracture ( $M_2$ ). For  $M_1$  fractures, reduction with positive or neutral medial cortical support and fixation with cephalomedullary nails is acceptable. Limited sliding between the head-neck fragment and femur shaft can yield secondary stability. This process is favorable to fracture healing (23). The  $M_2$  fracture is conventionally regarded as an unstable pattern, which is approximately relative to the medial multifragmentary fracture pattern (31A3.3) by AO classification-2018. Nevertheless, the occurrence of  $M_2$  fractures is much more infrequent compared to  $M_1$  fractures. Furthermore, the  $M_2$  fractures always appear to be fairly hard to get a rigid buttress with an adequate reduction. Thus, delayed ambulation will be suggested postoperatively, which may be associated with a higher incidence of postoperative complications. To augment the stability of the medial column, some new fixation systems, for instance, triangular support intramedullary nail (Double Medical Technology Inc, China) and medial sustainable nail (Weigao Medical Technology Inc, China) have been utilized (12, 16). In this new classification system, the identification of medial column is the primary process of the whole assessment. Specific fracture information is critical to optimizing fixation choices (Table 2).

On the contrary, the lateral wall of the proximal femur bears tensile stress. Therefore, we defined the lateral column as the region of tension bone trabecular. According to the relative position between the fracture line and femur neck fundus, we divided the lateral column into  $L_0$ ,  $L_1$ ,  $L_2$ , and  $L_3$ , with increasing instability. With increasing attention to the integrity and thickness of the lateral wall, various complementary methods have been devised for the reconstruction and fixation of this region, whether using extramedullary or intramedullary implants (24, 25).  $L_1$  fractures are considered stable fractures and need no extra fixation.  $L_2$  fractures are conventionally defined as transverse fractures or oblique fractures. Concerning this fracture pattern, the balance of the hip lever system has been broken, which may

lead to overload on implants. Therefore, occurrences of implant breakage have been reported frequently (24). Whereas, long cephalomedullary nails are recommended, with or without additional augmentation (e.g. cerclage, screw, and plate). The  $L_3$  fractures are defined as occurrences below the femoral neck fundus in our classification system. To prolong the working length of nails, long cephalomedullary nails combined with additional lateral column reconstruction may be contributory to balancing the strong moment from the hip (26). Based on the assessment of the lateral column, the implant options and auxiliary fixation can be properly determined.

In our observation, the fracture line involving the trochanter runs generally from the anterosuperior edge of the GT toward the LT. On the other hand, GT and LT fragments are frequently poor-reduced and fixed while using extramedullary or intramedullary implants (27). This situation is mainly due to the attachment of the gluteus medius, piriformis, and iliopsoas muscle, which may produce specific fracture mechanisms (19). Thus, we defined the region involving super-posterior GT and LT as the posterior column. GT fracture ( $P_1$ ) and LT fracture ( $P_2$ ) may occur individually or simultaneously ( $P_3$ ). However, the management of fractures involving the posterior column remains ambiguous. In recent literature, it was reported that poor reduction and fixation of LT fragments may be significantly associated with posterior sagging of the femoral neck (28). Fixation with nonabsorbable tape (Alfresa Pharma Co., Ltd., Japan), or twisted steel wires (Alfresa Pharma Co., Ltd., Japan) could be an effective procedure to improve early ambulatory ability (13, 27, 29). The optimal management of fractures involving the posterior column still needs further research.

Based on the 3DCT reconstruction of intertrochanteric fractures, the medial, lateral, and posterior columns can be assessed respectively. The detailed fracture information in each column may attribute to making an optimal fixation strategy. Overall evaluation can be documented as  $M_{0/1/2}L_{0/1/2/3}P_{0/1/2/3}$ . Therefore, treatment protocol involving implant type, working length, auxiliary device, and rehabilitation plan can be properly determined. In this study, 103 patients (39.9%) were classified as  $M_1L_{0/1}P_{2/3}$ , representing the majority of intertrochanteric fractures. For these patterns, short cephalomedullary nails may be recommended, with or without fixation of LT. Another fracture type,  $M_2L_3P_3$  in our classification system, indicates severe comminution of intertrochanteric fractures and may need long cephalomedullary nails and three-column augmentation (8, 26, 30).

Our study has several limitations. First, the sample size was relatively small. Thus, only a few cases were classified into several less frequent fracture types (e.g.  $M_0L_1P_{0/1/2}$ ,  $M_1L_2P_{0/1}$ ). This

may decrease clinical application and promotion value. Second, the recommendations for fracture treatment were based on partial data from previous literature. Surgical recommendations may require further study and systematic review. Third, according to fracture images from 258 consecutive patients, we found that young adults tend to have more transverse fractures or oblique fractures from high-energy mechanisms. Thus, the difference between young and elder patients regarding bony conditions, traumatic mechanisms, fracture patterns, and treatment strategies should be taken into consideration. In conclusion, we proposed this novel classification system for intertrochanteric fractures based on 3DCT findings with good agreement. It is comprehensive, reproducible, and easy to grasp compared to other classification systems. This method is proposed on both proximal femur biomechanic characteristics and traumatic mechanisms. Based on the novel classification system, we can formulate more reasonable treatment protocols involving various late-model internal fixation devices.

### AUTHOR CONTRIBUTIONS

JQL, YL, BXW and DY : main idea and research, contributed equally to this work and should be considered as equal first authors. HH and LJ : two examiners. CY and PXY : data collection, data analysis.

### FUNDING

There is no funding for our article.

### CONFLICT OF INTEREST

The authors declare that they have no Conflict of interest.

### ACKNOWLEDGEMENTS

We would like to give our sincere appreciation to the reviewers for their helpful comments on this article. Thanks to Xin-Yu Jiang for her nice work in creating these exquisite illustrations in this article.

### ETHICAL APPROVAL

This work was approved by the Ethics Committee of the ChongQing Orthopedic Hospital Of Traditional Medicine (No. CQ20220610). All procedures performed in this study were in accordance with the ethical standards of the institutional and/or national research committee.

### INFORMED CONSENT

Written informed consent was obtained from all patients.

### REFERENCES

- Jensen JS : Classification of trochanteric fractures. *Acta Orthop Scand* 51(5) : 803-10, 1980
- Andersen E, Jorgensen LG, Hededam LT : Evans' classification of trochanteric fractures : an assessment of the interobserver and intraobserver reliability. *Injury* 21(6) : 377-8, 1990
- Klaber I, Besa P, Sandoval F, Lobos D, Zamora T, Schweitzer D, Urrutia J : The new AO classification system for intertrochanteric fractures allows better agreement than the original AO classification. An inter- and intra-observer agreement evaluation. *Injury* 52(1) : 102-5, 2021
- Shoda E, Kitada S, Sasaki Y, Hirase H, Niikura T, Lee SY, Sakurai A, Oe K, Sasaki T : Proposal of new classification of femoral trochanteric fracture by three-dimensional computed tomography and relationship to usual plain X-ray classification. *J Orthop Surg (Hong Kong)* 25(1) : 2309499017692700, 2017
- Wada K, Mikami H, Amari R, Toki S, Takai M, Sairyoo K : A novel three-dimensional classification system for intertrochanteric fractures based on computed tomography findings. *J Med Invest* 66(3.4) : 362-6, 2019
- Kalia RB, Arora SS, Sarkar B, Paul S, Singh S : A comprehensive 3D CT based classification of intertrochanteric fracture. *J Clin Orthop Trauma* 30 : 101912, 2022
- Yildirim C, Muratoglu OG, Turan K, Ergun T, Misir A, Aydin M : The intra- and interobserver reliability of five commonly used intertrochanteric femur fracture classification systems. *Jt Dis Relat Surg* 33(1) : 187-92, 2022
- Hoffmann MF, Khoriaty JD, Sietsema DL, Jones CB : Outcome of intramedullary nailing treatment for intertrochanteric femoral fractures. *J Orthop Surg Res* 14(1) : 360, 2019
- Gao Z, Lv Y, Zhou F, Ji H, Tian Y, Zhang Z, Guo Y : Risk factors for implant failure after fixation of proximal femoral fractures with fracture of the lateral femoral wall. *Injury* 49(2) : 315-22, 2018
- Wang Q, Gu XH, Li X, Wu JH, Ju YF, Huang WJ, Wang QG : Management of Low-Energy Basicervical Proximal Femoral Fractures by Proximal Femoral Nail Anti-Rotation. *Orthop Surg* 11(6) : 1173-9, 2019
- Ye KF, Xing Y, Sun C, Cui ZY, Zhou F, Ji HQ, Guo Y, Lyu Y, Yang ZW, Hou GJ, Tian Y, Zhang ZS : Loss of the posteromedial support : a risk factor for implant failure after fixation of AO 31-A2 intertrochanteric fractures. *Chin Med J (Engl)* 133(1) : 41-8, 2020
- Nie S, Li M, Ji H, Li Z, Li W, Zhang H, Licheng Z, Tang P : Biomechanical comparison of medial sustainable nail and proximal femoral nail antirotation in the treatment of an unstable intertrochanteric fracture. *Bone Joint Res* 9(12) : 840-7, 2020
- Usami T, Takada N, Nishida K, Sakai H, Iwata H, Sekiya I, Ueki Y, Murakami H, Kuroyanagi G : Banding with lesser trochanter fragment using nonabsorbable tape in trochanteric femoral fractures. *SICOT J* 7 : 33, 2021
- Wang Y, Chen W, Zhang L, Xiong C, Zhang X, Yu K, Ju J, Chen X, Zhang D, Zhang Y : Finite Element Analysis of Proximal Femur Bionic Nail (PFBN) Compared with Proximal Femoral Nail Antirotation and InterTan in Treatment of Intertrochanteric Fractures. *Orthop Surg* 14(9) : 2245-55, 2022
- Wu HF, Chang CH, Wang GJ, Lai KA, Chen CH : Biomechanical investigation of dynamic hip screw and wire fixation on an unstable intertrochanteric fracture. *Biomed Eng Online* 18(1) : 49, 2019
- Zhang R, Luo P, Hu W, Ke C, Wang J, Guo X : [Biomechanical assessment of newly-designed proximal femoral medial buttress plate for treatment of reverse oblique femoral intertrochanteric fracture]. *Zhongguo Xiu Fu Chong Jian Wai Ke Za Zhi* 31(2) : 165-70, 2017
- Huang SG, Chen B, Zhang Y, Nie FF, Ju L, Li M, Zhang YH : Comparison of the Clinical Effectiveness of PFNA,

- PFLCP, and DHS in Treatment of Unstable Intertrochanteric Femoral Fracture. *Am J Ther* 24(6) : e659-e66, 2017
18. Lotz JC, Cheal EJ, Hayes WC : Stress distributions within the proximal femur during gait and falls : implications for osteoporotic fracture. *Osteoporos Int* 5(4) : 252-61, 1995
  19. Flack NA, Nicholson HD, Woodley SJ : A review of the anatomy of the hip abductor muscles, gluteus medius, gluteus minimus, and tensor fascia lata. *Clin Anat* 25(6) : 697-708, 2012
  20. Wada K, Mikami H, Toki S, Amari R, Takai M, Sairyo K : Intra- and inter-rater reliability of a three-dimensional classification system for intertrochanteric fracture using computed tomography. *Injury* 51(11) : 2682-5, 2020
  21. Yin B, He Y, Wang D, Zhou J : Classification of femur trochanteric fracture : Evaluating the reliability of Tang classification. *Injury* 52(6) : 1500-5, 2021
  22. Bergmann G, Deuretzbacher G, Heller M, Graichen F, Rohlmann A, Strauss J, Duda GN : Hip contact forces and gait patterns from routine activities. *J Biomech* 34(7) : 859-71, 2001
  23. Chang SM, Zhang YQ, Ma Z, Li Q, Dargel J, Eysel P : Fracture reduction with positive medial cortical support : a key element in stability reconstruction for the unstable pertrochanteric hip fractures. *Arch Orthop Trauma Surg* 135(6) : 811-8, 2015
  24. Chantarapanich N, Riansuwan K : Biomechanical performance of short and long cephalomedullary nail constructs for stabilizing different levels of subtrochanteric fracture. *Injury* 53(2) : 323-33, 2022
  25. Jain S, Dawar H, Khare H, Kumar M, Ajmera A : Does augmentation of intramedullary nails by a buttress plate effectively restore lateral wall integrity in intertrochanteric fractures. *Int Orthop* 46(10) : 2365-71, 2022
  26. Irgit K, Richard RD, Beebe MJ, Bowen TR, Kubiak E, Horwitz DS : Reverse Oblique and Transverse Intertrochanteric Femoral Fractures Treated With the Long Cephalomedullary Nail. *J Orthop Trauma* 29(9) : e299-304, 2015
  27. Kim GM, Nam KW, Seo KB, Lim C, Kim J, Park YG : Wiring technique for lesser trochanter fixation in proximal IM nailing of unstable intertrochanteric fractures : A modified candy-package wiring technique. *Injury* 48(2) : 406-13, 2017
  28. Kim KH, Kang MS, Lim EJ, Park ML, Kim JJ : Posterior Sagging After Cephalomedullary Nailing for Intertrochanteric Femur Fracture is Associated with a Separation of the Greater Trochanter. *Geriatr Orthop Surg Rehabil* 11 : 2151459320946013, 2020
  29. Villano M, Innocenti M, Civinini R, Carulli C, Civinini A, Taha ZA, Cozzi Lepri A : The lesser trochanter "Sling fixation technique" in proximal intramedullary nailing of unstable intertrochanteric fractures : A polymer-based cerclage wiring. *J Orthop* 34 : 94-9, 2022
  30. Lee WC, Chou SM, Tan CW, Chng LS, Yam GJM, Chua THI : Intertrochanteric fracture with distal extension : When is the short proximal femoral nail antirotation too short? *Injury* 52(4) : 926-32, 2021