

CASE REPORT

Open Access



# Drug-induced *de novo* thrombotic microangiopathy diagnosed 2 years after renal transplantation: a case report and literature review

Keisuke Ozaki<sup>1</sup>, Tomoya Fukawa<sup>1</sup>, Kunihisa Yamaguchi<sup>1\*</sup>, Keito Shiozaki<sup>2</sup>, Yutaro Sasaki<sup>1</sup>, Sayo Ueda<sup>3</sup>, Kohjiro Nagai<sup>4</sup>, Shu Wakino<sup>3</sup>, Masayuki Takahashi<sup>1</sup> and Hiro-omi Kanayama<sup>1</sup>

## Abstract

**Background** Post-transplant *de novo* thrombotic microangiopathy (TMA) is a rare yet serious complication that generally can develop in renal transplant recipients immediately after reperfusion or several months after transplantation. Here, we report a case of systemic tacrolimus-associated TMA in a patient diagnosed 2 years after renal transplantation.

**Case presentation** A 49-year-old woman presented with severe anemia 18 months after undergoing renal transplantation. Anemia was refractory to recombinant human erythropoietin and was suspected to be due to excessive menstruation. Anemia persisted even after hysterectomy, and thereafter, pancytopenia developed. A bone marrow biopsy was performed and showed no evidence of myeloproliferative neoplasms. Furthermore, an increase in serum lactate dehydrogenase level and the appearance of schistocytes on peripheral blood smear was noted 24 months post-transplant. Other possible causes of *de novo* TMA were excluded, and an allograft biopsy was performed. Pathological findings of the allograft biopsy showed that some afferent arterioles had formed thrombi. Suspecting tacrolimus to be the cause of TMA, 25 months after the transplant, we switched treatment to cyclosporine. Pancytopenia and renal function improved after switching to this calcineurin inhibitor. Subsequently, her allograft renal function stabilized for three years after renal transplantation.

**Conclusion** We encountered a case of secondary drug-induced TMA in the late stages of renal transplantation. Therefore, TMA should be suspected when anemia with hemolysis is observed in recipients of kidney transplant.

**Keywords** Renal transplantation, Thrombotic microangiopathy (TMA), Tacrolimus, Calcineurin inhibitor

\*Correspondence:

Kunihisa Yamaguchi

yamaguchi.kunihisa@tokushima-u.ac.jp

<sup>1</sup> Department of Urology, Institute of Biomedical Sciences, Tokushima University Graduate School, The University of Tokushima, 3-18-15 Kuramoto-Cho, Tokushima 770-8503, Japan

<sup>2</sup> Department of Urology, Tokushima Prefectural Central Hospital, Tokushima, Japan

<sup>3</sup> Department of Nephrology, Institute of Biomedical Sciences, Tokushima University Graduate School, Tokushima, Japan

<sup>4</sup> Department of Nephrology, Shizuoka General Hospital, Shizuoka, Japan

## Background

Post-transplant *de novo* thrombotic microangiopathy (TMA) is a rare yet serious complication in renal transplant recipients. Incidence rates are estimated to be 0.8–15%, with an allograft loss in up to 33–50% of cases [1, 2]. Post-transplant *de novo* TMA with systemic clinical features can develop immediately after reperfusion or several months after transplantation [2–4]. A variety of risks associated with the onset of post-transplant TMA have



© The Author(s) 2023. **Open Access** This article is licensed under a Creative Commons Attribution 4.0 International License, which permits use, sharing, adaptation, distribution and reproduction in any medium or format, as long as you give appropriate credit to the original author(s) and the source, provide a link to the Creative Commons licence, and indicate if changes were made. The images or other third party material in this article are included in the article's Creative Commons licence, unless indicated otherwise in a credit line to the material. If material is not included in the article's Creative Commons licence and your intended use is not permitted by statutory regulation or exceeds the permitted use, you will need to obtain permission directly from the copyright holder. To view a copy of this licence, visit <http://creativecommons.org/licenses/by/4.0/>. The Creative Commons Public Domain Dedication waiver (<http://creativecommons.org/publicdomain/zero/1.0/>) applies to the data made available in this article, unless otherwise stated in a credit line to the data.

been recognized, including immunosuppressive drugs, viral infections, ischemia–reperfusion injury, ABO-blood group incompatible transplantation, and antibody-mediated rejection (AMR) [5, 6]. Calcineurin inhibitors (CNIs) have also been implicated in drug-induced TMA, especially in the early period (3–6 months) after transplantation [7–9].

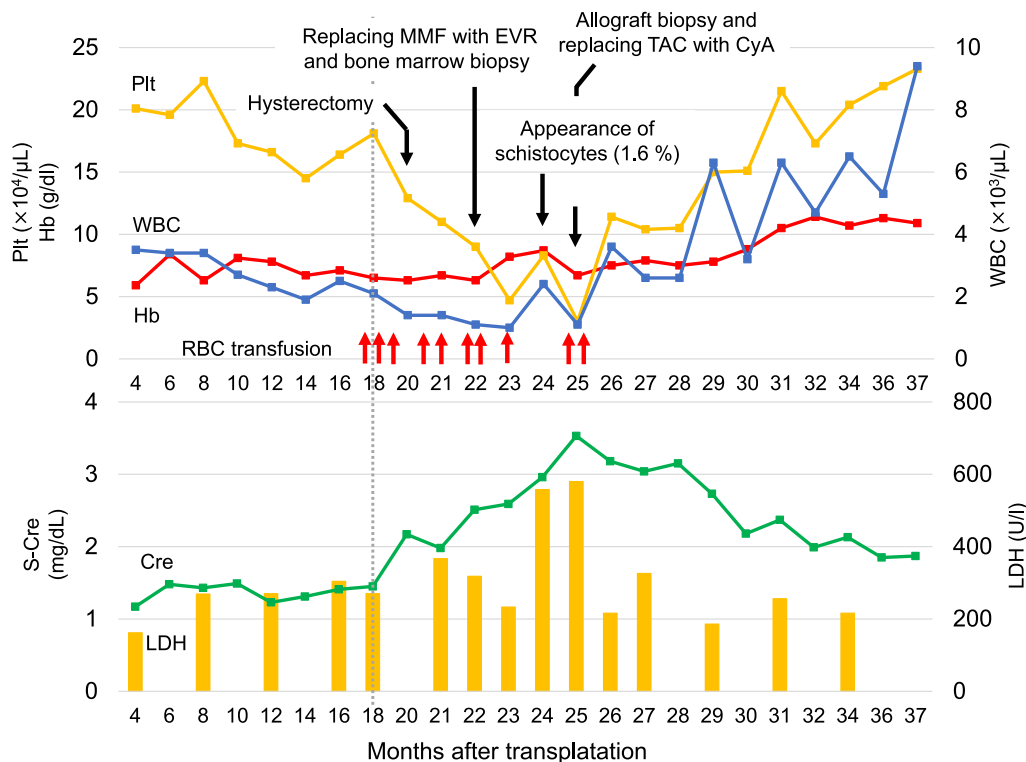
Here, we report a case of tacrolimus (TAC)-associated TMA in a patient diagnosed 2 years after renal transplantation; successfully treated by replacing TAC with cyclosporine (CyA).

**Case presentation**

A 49-year-old woman with end-stage renal failure due to IgA nephropathy received a pre-emptive ABO-blood type-compatible renal transplant from her mother. In addition to nephrogenic anemia, the patient experienced anemic fluctuations due to excessive menstruation. Complement-dependent cytotoxic crossmatch and flow cytometric crossmatch tests yielded negative results. Anti-HLA antibody testing was weakly positive for both Class I and II, using HLA antigen-coated synthetic flow beads (Flow PRA Screening Kit, One Lambda Inc., Canoga Park, CA, USA). She also gave birth three times.

Since the patient was a highly sensitized case and she had received rituximab preoperatively. Induction immunosuppressive therapies included TAC, mycophenolate mofetil (MMF), methylprednisolone (mPSL), and basiliximab (BXM).

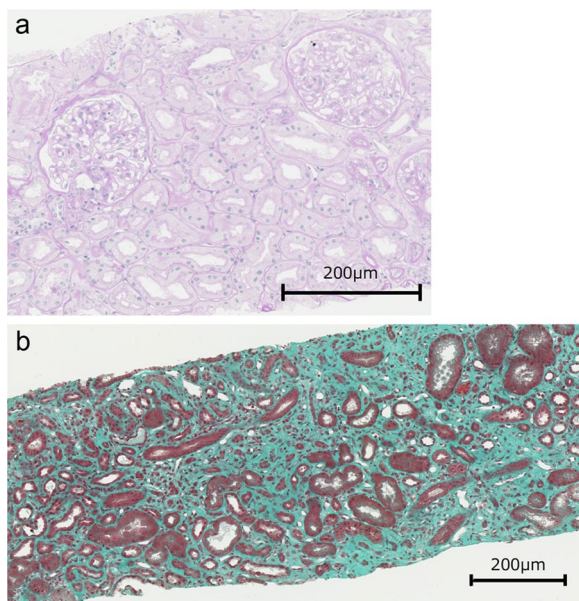
Figure 1 shows the clinical course of the renal transplantation. Although improvement in post-operative renal function was good, hemoglobin remained at 6–8 mg/dL and was refractory to recombinant human erythropoietin (rHuEPO). Therefore, anemia was suspected to be caused by excessive menstruation. Since red blood cell transfusion was repeatedly required for 18 months post-transplantation, hysterectomy was performed at 20 months. Around the same time, serum creatinine levels increased from 1.45 to 2.17 mg/dL. Anemia persisted even after hysterectomy, with new clinical features, including episodes of nausea, fatigue, and abdominal pain. Furthermore, blood investigations revealed pancytopenia. Consequently, she underwent a bone marrow biopsy which revealed no myeloproliferative changes. MMF-induced myelosuppression was suspected; thus, treatment was switched to everolimus (EVR). However, no improvement in renal function or pancytopenia was seen, as anticipated. Thus, *de novo* TMA was suspected due to increased levels of serum lactate dehydrogenase



**Fig. 1** Clinical course of the patient post-kidney transplant. MMF, mycophenolate mofetil; EVR Everolimus, TAC Tacrolimus, CyA Cyclosporine, RBC Red blood cells

(LDH) and the presence of schistocytes in the peripheral blood smear. The disintegrin and metalloprotease with thrombospondin type I repeats-13 (ADAMTS13) activity were within normal range (72%), and ADAMTS13 inhibitor was negative. C3 and C4 complement levels were all within normal range. No abnormalities were found in the coagulation or fibrinolytic blood profiles. Other possible causes of *de novo* TMA, such as bacterial or viral infections (Epstein-Barr virus, cytomegalovirus, and polyoma virus), were excluded. Doppler ultrasonography of the allograft revealed normal blood flow and no increased vascular resistance, following which, an allograft biopsy was performed. Pathologically, the allograft biopsy showed no signs of antibody-mediated rejection (C4d negative). And no afferent arterioles showed thrombus formation, which is not a typical histological finding of TMA (Fig. 2). Suspecting TAC as the cause for TMA, TAC was replaced with CyA 25 months after transplantation. The trough value of TAC was between 5–6 ng/mL.

We found that renal function and pancytopenia improved after switching from CNIs. Additionally, RBC fragmentation disappeared and the LDH level normalized. The patient's fatigue and abdominal pain reduced rapidly; renal function subsequently stabilized for three years after renal transplantation.



**Fig. 2** a Periodic acid-Schiff stain b Masson trichrome stain was used. Pathologically, the allograft biopsy showed atrophy and fibrosis of the tubules, diagnosed as moderate interstitial fibrosis and tubular atrophy (IF/TA, Grade II), according to the Banff classification of 2017

## Discussion

TMA is a condition in which microvascular thrombosis occurs due to abnormalities in the vessel walls of small arteries and capillaries. TMA typically presents as a triad of hemolytic anemia, thrombocytopenia, and organ damage due to microcirculatory disturbances. Overall, *de novo* systemic TMA is reported to occur mostly within the first month after transplantation [10]. Post-transplant TMA can be diagnosed pathologically on a routine renal biopsy without evidence of laboratory abnormalities [11]. Table 1 shows a literature review of case reports of *de novo* TAC-induced TMA after renal transplantation [4, 9, 11–17].

Diagnosis of hemolytic anemia is important for the early detection of TMA; thus, LDH levels, peripheral blood smear, Coombs test, haptoglobin, and other TMA-oriented tests should be performed. In our case, although orthocytic anemia, pancytopenia, and renal impairment were observed, hemolytic changes such as elevated LDH and the appearance of schistocytes were not identified until 20 months post-transplantation. Thus, a delayed onset of symptoms during the prime period of TMA makes diagnosis difficult. Here, considering that two years had passed since renal transplantation, we had to rule out the following conditions: AMR, TMA development due to infection, drug-induced myelosuppression, and myeloproliferative neoplasm. Accordingly, we came to an exclusionary diagnosis of TMA due to TAC.

CNIs are known to cause transplant-related TMA, especially in the early period (3–6 months) after transplantation [8, 9]. Various mechanisms contribute to the onset of TMA with the use of CNIs. Previous studies on rats treated with CyA reported that biosynthesis of vasoconstricting substances, such as thromboxane A2 and endothelin, increased; the expression of vasoconstrictor molecules, such as prostaglandin E2 and prostacyclin, decreased. This suggested that a loss of equilibrium in vasoactive peptides leads to arteriolar vasoconstriction [18]. Platelet-activating, pro-coagulant, and anti-fibrinolytic effects of CNIs have also been implicated in the development of TMA, especially in cases where the endothelium is already injured due to other mechanisms, such as ischemia–reperfusion injury and antibody-mediated rejection [19, 20]. The incidence rate of drug-induced TMA due to TAC is less frequently reported than that due to CyA [9]. CyA-induced TMA has been reported to develop in a dose-dependent manner [21], consistent with the report that CyA is associated with vascular endothelial damage. However, the association between the onset of TAC-induced TMA and its dose remains unclear [9].

In a study of 26 patients who underwent renal or combined kidney-pancreas transplantation, TMA was

**Table 1** Recent reports of *de novo* TAC-induced TMA after renal transplantation

Age	Sex	Original disease	ABO compatibility	Donor	Clinical onset (days)	TAC trough level (ng/mL)	Clinical features	Dose adjust of TAC	Other treatment	Clinical follow-up	Outcome	References
56	F	CGN	Compatible	Living	4	15–20 (div.)	Systemic Plt, Hb, Epigastralgia, Diarrhea	Reduce	PE, Transfusion, ECUM		Good	[12]
55	M	CGN	Compatible	Deceased	4	4.8	Systemic Plt, Hb	Replace with EVR	PE, RIT		Good	[13]
31	F	Lupus nephritis	Unknown	Living	6	Unknown	Systemic Plt, Hb, Bloody diarrhea	Discontinuation	PE	Ischemic colitis, Acute rejection	Graft loss	[4]
59	M	Diabetic nephropathy	Incompatible	Living	9	28	Systemic Plt, Hb	Reduce	PE, DFPP, mPSL pulse therapy, RIT		Good	[14]
68	M	Unknown	Compatible	Deceased	11	11.9–27.9	Localized	Replace with SRL	None	DGF	Good	[15]
44	M	ADPKD	Compatible	Deceased	11	3.8	Localized	Discontinuation	PE, ECU	Discontinued ECU after 10 mos	Good	[16]
11	M	Renal venous thrombosis	Compatible	Deceased	12	9.9	Localized	Replace with EVR	None		Good	[17]
17	M	Unknown	Compatible	Deceased	4	8.5	Localized	Replace with SRL	None		Good	[11]
38	M	Diabetic nephropathy	Compatible	Deceased	6	Unknown	Localized	Reduce	PE	Reccurrence	Good	[9]
30	F	Lupus nephritis	Compatible	Deceased	14	12	Localized	Replace with CyA	None		Graft loss	[9]
49	F	IgA nephropathy	Compatible	Living	24	5–6	Systemic Pancytopenia, nausea, fatigue	Replace with CyA	None	No recurrence for 1 year	Good	our case

CGN Chronic glomerulonephritis, ADPKD Autosomal dominant polycystic kidney disease, EVR Everolimus, SRL Sirolimus, PE Plasma exchange, DFPP Double filtration plasmapheresis, RIT Rituximab, DGF Delayed graft function

diagnosed by episodic allograft biopsy. In this study, 24 and 2 patients received CyA and TAC, respectively. Systemic TMA leads to early graft rejection more frequently than does localized TMA. Only 2 of the 26 patients receiving systemic TMA showed changes other than those seen in renal histology [22]. In a study by Schwimmer et al., 54% of patients receiving systemic TMA developed acute kidney injury requiring dialysis, and 38% showed TMA-related graft loss. Conversely, no patients with localized TMA required dialysis or experienced early graft loss [1].

Optimal treatment for TMA after renal transplantation, including discontinuation of the suspected drug and modification of immunosuppressive agents, remains controversial. Kwon et al. reported that changing the CNI resulted in good graft function at one year in 81% of TMA patients post-transplantation [23]. On the other hand, Zarifian et al. showed that although an improvement was observed in 81% of patients who switched to another CNI, 30.1% lost allograft renal function due to TMA [22]. Given that the cause of CNI-induced TMA is vascular endothelial damage, plasma exchange is often ineffective [22].

It has been reported that in cases of secondary TMA development (including infection, ischemia–reperfusion injury, and drugs), abnormal complement regulation may have occurred, and triggered the development of TMA [24]. Thus, withdrawal of CNI treatment alone might not be sufficient to reverse adverse effects of the alternate pathway of complement activation associated with these conditions [2, 9]. In such cases, plasma exchange could be useful. Furthermore, eculizumab, an anti-complement C5 inhibitor, has shown efficacy in many resistant cases of *de novo* post-transplant TMA [25–27], including TAC-induced TMA [16]. Hence, the use of eculizumab can be considered in refractory cases after CNI switching.

One pediatric case of localized TAC-induced TMA showed complete resolution after switching to CNIs, with no chronic changes on repeat biopsy [11]. In another study including 26 patients with CyA-induced TMA, 11 patients underwent post-TMA biopsies that showed a high percentage of chronic vascular changes (73%) [23]. However, *de novo* TMA can recur after switching to CNIs [4]. Renal allograft survival is clearly reduced with the development of post-transplant TMA [23, 28, 29] and is worse with recurrent disease [30]. In our case, renal function progressively improved after switching to CNI, and there was no recurrence for one year; however, long-term follow-up of renal function proved crucial in preventing TMA recurrence.

TAC plays a central role in the prevention of graft rejection, but can be associated with adverse events,

such as nephrotoxicity, and can lead to TMA. The diagnosis required several differentiations; however, the CNI change was effective, and renal function improved to pre-treatment levels. Long-term follow-up is required in the future.

## Conclusion

We encountered a case of secondary drug-induced TMA after renal transplantation. We conclude that TMA should be suspected in cases presenting with anemia and hemolysis, regardless of the time since renal transplantation.

## Abbreviations

TMA	Thrombotic microangiopathy
AMR	Antibody-mediated rejection
CNI	Calcineurin inhibitor
TAC	Tacrolimus
CyA	Cyclosporine
MMF	Mycophenolate mofetil
mPSL	Methylprednisolone
BXM	Basiliximab
rHuEPO	Recombinant human erythropoietin
EVR	Everolimus
LDH	Lactate dehydrogenase
ADAMTS13	A disintegrin and metalloprotease with thrombospondin type I repeats-13

## Acknowledgements

Not applicable.

## Author contributions

K.O. treated the patient and wrote the manuscript. T.F. treated the patient and supervised the manuscript. K.Y. treated the patient and designed the manuscript. S.U., K.N., S.W. supplied the pathology reports. All authors read and approved the final manuscript.

## Funding

None.

## Availability of data and materials

All data analyzed during this study are included in this published article.

## Declarations

### Ethics approval and consent to participate

The authors have no ethical conflicts to disclose. The present case report was approved by our institution's Institutional Review Board.

### Consent for publication

Written informed consent was obtained from the patient.

### Competing interests

The authors have no competing interests and do not have any relationships to disclose.

Received: 28 July 2022 Accepted: 6 December 2022

Published online: 04 January 2023

## References

- Schwimmer J, Nadasdy TA, Spitalnik PF, Kaplan KL, Zand MS. *De novo* thrombotic microangiopathy in renal transplant recipients: a comparison

- of hemolytic uremic syndrome with localized renal thrombotic microangiopathy. *Am J Kidney Dis.* 2003;41:471–9. <https://doi.org/10.1053/ajkd.2003.50058>.
2. Reynolds JC, Agodola LY, Yuan CM, Abbott KC. Thrombotic microangiopathy after renal transplantation in the United States. *Am J Kidney Dis.* 2003;42:1058–68. <https://doi.org/10.1016/j.ajkd.2003.07.008>.
  3. Tasaki M, Saito K, Nakagawa Y, Imai N, Ito Y, Yoshida Y, et al. Analysis of the prevalence of systemic *de novo* thrombotic microangiopathy after ABO-incompatible kidney transplantation and the associated risk factors. *Int J Urol.* 2019;26:1128–37. <https://doi.org/10.1111/iju.14118>.
  4. Pham PT, Peng A, Wilkinson AH, Gritsch HA, Lassman C, Pham PC, et al. Cyclosporine and tacrolimus-associated thrombotic microangiopathy. *Am J Kidney Dis.* 2000;36:844–50. <https://doi.org/10.1053/ajkd.2000.17690>.
  5. Okumi M, Toki D, Nozaki T, Shimizu T, Shirakawa H, Omoto K, et al. ABO-incompatible living kidney transplants: evolution of outcomes and immunosuppressive management. *Am J Transplant.* 2016;16:886–96. <https://doi.org/10.1111/ajt.13502>.
  6. Satoskar AA, Pelletier R, Adams P, Nadasdy GM, Brodsky S, Pesavento T, et al. *De novo* thrombotic microangiopathy in renal allograft biopsies—role of antibody-mediated rejection. *Am J Transplant.* 2010;10:1804–11. <https://doi.org/10.1111/j.1600-6143.2010.03178.x>.
  7. Wu K, Budde K, Schmidt D, Neumayer HH, Lehner L, Bamouid J, et al. The inferior impact of antibody-mediated rejection on the clinical outcome of kidney allografts that develop *de novo* thrombotic microangiopathy. *Clin Transplant.* 2016;30:105–17. <https://doi.org/10.1111/ctr.12645>.
  8. Naesens M, Kuypers DR, Sarwal M. Calcineurin inhibitor nephrotoxicity. *Clin J Am Soc Nephrol.* 2009;4:481–508. <https://doi.org/10.2215/CJN.04800908>.
  9. Trimarchi HM, Truong LD, Brennan S, Gonzalez JM, Suki WN. FK506-associated thrombotic microangiopathy: report of two cases and review of the literature. *Transplantation.* 1999;67:539–44. <https://doi.org/10.1097/00007890-199902270-00009>.
  10. Pham PT, Pham PC, Wilkinson AH. Thrombotic microangiopathy following organ transplantation. *Kidney Int* 2003;63:1959 <https://doi.org/10.1046/j.1523-1755.2003.00950.x>
  11. Hastings MC, Wyatt RJ, Ault BH, Jones DP, Lau KK, Gaber AO, et al. Diagnosis of *de novo* localized thrombotic microangiopathy by surveillance biopsy. *Pediatr Nephrol.* 2007;22:742–6. <https://doi.org/10.1007/s00467-006-0392-z>.
  12. Saito M, Satoh S, Kagaya H, Tsuruta H, Obara T, Kumazawa T, et al. Thrombotic microangiopathy developing in early stage after renal transplantation with a high trough level of tacrolimus. *Clin Exp Nephrol.* 2008;12:312–5. <https://doi.org/10.1007/s10157-008-0037-6>.
  13. Hayashi Y, Nagahara A, Kawashima A, Kakuta Y, Ujike T, Abe T, et al. A case of successful recovery of renal allograft function following a diagnosis of thrombotic microangiopathy clinically made in the immediate post-transplant period. *Nihon Hinyokika Gakkai Zasshi.* 2017;108:166–9. <https://doi.org/10.5980/jpnjurol.108.166>.
  14. Takeda A, Ohtsuka Y, Horike K, Inaguma D, Goto N, Watarai Y, et al. A case of tacrolimus-associated thrombotic microangiopathy after ABO-blood-type-incompatible renal transplantation. *Clin Transplant.* 2011;25(Suppl 23):15–8. <https://doi.org/10.1111/j.1399-0012.2011.01453.x>.
  15. Carson JM, Newman ED, Farber JL, Filippone EJ. Tacrolimus-induced thrombotic microangiopathy: natural history of a severe, acute vasculopathy. *Clin Nephrol.* 2012;77:79–84. <https://doi.org/10.5414/cn107036>.
  16. Safa K, Logan MS, Batal I, Gabardi S, Rennke HG, Abdi R. Eculizumab for drug-induced *de novo* posttransplantation thrombotic microangiopathy: a case report. *Clin Nephrol.* 2015;83:125–9. <https://doi.org/10.5414/CN108163>.
  17. Cortina G, Trojer R, Waldegger S, Schneeberger S, Gut N, Hofer J. *De novo* tacrolimus-induced thrombotic microangiopathy in the early stage after renal transplantation successfully treated with conversion to everolimus. *Pediatr Nephrol.* 2015;30:693–7. <https://doi.org/10.1007/s00467-014-3036-8>.
  18. Ramírez C, Olmo A, O'Valle F, Masseroli M, Aguilar M, Gómez-Morales M, et al. Role of intrarenal endothelin 1, endothelin 3, and angiotensin II expression in chronic cyclosporin A nephrotoxicity in rats. *Exp Nephrol.* 2000;8:161–72. <https://doi.org/10.1159/000020664>.
  19. Sahin G, Akay OM, Bal C, Yalcin AU, Gulbas Z. The effect of calcineurin inhibitors on endothelial and platelet function in renal transplant patients. *Clin Nephrol.* 2011;76:218–25.
  20. Tomasiak M, Rusak T, Gacko M, Stelmach H. Cyclosporine enhances platelet procoagulant activity. *Nephrol Dial Transp.* 2007;22:1750–6. <https://doi.org/10.1093/ndt/gfl836>.
  21. Zakarija A, Bennett C. Drug-induced thrombotic microangiopathy. *Semin Thromb Hemost.* 2005;31:681–90. <https://doi.org/10.1055/s-2005-925474>.
  22. Zarifian A, Meleg-Smith S, O'Donovan R, Tesi RJ, Batuman V. Cyclosporine-associated thrombotic microangiopathy in renal allografts. *Kidney Int.* 1999;55:2457–66. <https://doi.org/10.1046/j.1523-1755.1999.00492.x>.
  23. Kwon O, Hong SM, Sutton TA, Temm CJ. Preservation of peritubular capillary endothelial integrity and increasing pericytes may be critical to recovery from posts ischemic acute kidney injury. *Am J Physiol Ren Physiol.* 2008;295:F351–9. <https://doi.org/10.1152/ajprenal.90276.2008>.
  24. Zuber J, Le Quintrec M, Sberro-Soussan R, Loirat C, Frémeaux-Bacchi V, Legendre C. New insights into postrenal transplant hemolytic uremic syndrome. *Nat Rev Nephrol.* 2011;7:23–35. <https://doi.org/10.1038/nrneph.2010.155>.
  25. Dedhia P, Govil A, Mogilishetty G, Alloway RR, Woodle ES, Abu Jawdeh BG. Eculizumab and Belatacept for *de novo* atypical hemolytic uremic syndrome associated with CFHR3-CFHR1 deletion in a kidney transplant recipient: a case report. *Transplant Proc.* 2017;49:188–92. <https://doi.org/10.1016/j.transproceed.2016.11.008>.
  26. Yamamoto T, Watarai Y, Futamura K, Okada M, Tsujita M, Hiramitsu T, et al. Efficacy of eculizumab therapy for atypical hemolytic uremic syndrome recurrence and antibody-mediated rejection progress after renal transplantation with preformed donor-specific antibodies: case report. *Transplant Proc.* 2017;49:159–62. <https://doi.org/10.1016/j.transproceed.2016.10.013>.
  27. Ikeda T, Okumi M, Unagami K, Kanzawa T, Sawada A, Kawanishi K, et al. Two cases of kidney transplantation-associated thrombotic microangiopathy successfully treated with eculizumab. *Nephrology (Carlton).* 2016;21(Suppl 1):35–40. <https://doi.org/10.1111/nep.12768>.
  28. Campistol JM, Arias M, Ariceta G, Blasco M, Espinosa L, Espinosa M, et al. An update for atypical haemolytic uremic syndrome: diagnosis and treatment. *Consen Doc Nefrologia.* 2015;35:421–47. <https://doi.org/10.1016/j.nefro.2015.07.005>.
  29. Karthikeyan V, Parasuraman R, Shah V, Vera E, Venkat KK. Outcome of plasma exchange therapy in thrombotic microangiopathy after renal transplantation. *Am J Transplant.* 2003;3:1289–94. <https://doi.org/10.1046/j.1600-6143.2003.00222.x>.
  30. Murer L, Zacchello G, Bianchi D, Dall'amico R, Montini G, Andreetta B, et al. Thrombotic microangiopathy associated with parvovirus B 19 infection after renal transplantation. *J Am Soc Nephrol* 2000;11(6): 1132–7. <https://doi.org/10.1681/ASN.V1161132>

## Publisher's Note

Springer Nature remains neutral with regard to jurisdictional claims in published maps and institutional affiliations.

Ready to submit your research? Choose BMC and benefit from:

- fast, convenient online submission
- thorough peer review by experienced researchers in your field
- rapid publication on acceptance
- support for research data, including large and complex data types
- gold Open Access which fosters wider collaboration and increased citations
- maximum visibility for your research: over 100M website views per year

At BMC, research is always in progress.

Learn more [biomedcentral.com/submissions](https://biomedcentral.com/submissions)

