

ORIGINAL**Pancreatoduodenectomy combined with intestinal de-rotation as a complete artery-first approach for inexperienced surgeons**

Yuji Morine M.D., Yu Saito M.D., Shinichiro Yamada M.D., Teraoku Hiroki M.D., Tetsuya Ikemoto M.D., and Mitsuo Shimada M.D.

Department of Surgery, Institute of Biomedical Sciences, Tokushima University Graduate School, Tokushima 770-8503, Japan

Abstract : **Background :** Recent technical advances have reduced the incidence of intraoperative complications associated with pancreatoduodenectomy (PD). We aimed to determine whether inexperienced surgeons (ISs) would be as successful as experienced surgeons (ESs) when performing the complete artery-first approach using the intestinal de-rotation method of PD. **Methods :** Seventy patients who underwent PD using the intestinal de-rotation method in Tokushima University Hospital were enrolled in the present study. Intra- and post-operative parameters were compared between patients operated on by ESs (n=20) or ISs (n=50). **Results :** The surgical procedure lasted longer in the IS group (ES: 402 ± 68 min vs. IS: 483 ± 51 min, $p < 0.0001$), but the volume of blood loss was similar ($p = 0.7304$). There was no mortality in either group, and the incidences of postoperative complications with a Clavien-Dindo grade of >III did not differ between the groups. Grade B postoperative pancreatic fistulae developed in 20.0% of patients in the ES group and 22.0% in the IS group ($p = 0.9569$). Finally, the postoperative hospital stay of the IS group (32 ± 33 days) was equivalent to that of the ES group (33 ± 16 days) ($p = 0.9256$). **Conclusion :** ISs were able to perform similarly successful PDs using the intestinal de-rotation method to ESs. *J. Med. Invest.* 71 : 75-81, February, 2024

Keywords : pancreatoduodenectomy, superior mesenteric artery, inferior pancreatoduodenal artery, inexperienced surgeon

INTRODUCTION

Recent advances in the surgical techniques available for pancreatoduodenectomy (PD), including the use of vessel sealing devices and preoperative three-dimensional simulations or intraoperative real-time navigation methods have contributed to a higher incidence of tumor-negative surgical margins and a lower incidence of intraoperative hemorrhage (1-4). However, PD is still considered to be highly invasive and technically difficult, particularly for inexperienced surgeons (ISs), and can be associated with massive intraoperative hemorrhage during the dissection of the pancreatic head from the superior mesenteric artery (SMA) and the portal system.

To avoid this intraoperative complication, an artery-first approach has evolved through means of multi-directional approaches to the early separation of the peri-pancreatic feeding arteries from the SMA (5, 6). This approach allows the determination of whether the tumor can be resected from the SMA with a clear surgical margin or whether the SMA is inseparable from the tumor, rendering it unresectable, prior to the surgery reaching an irreversible stage. The artery-first approaches used to date can be summarized as superior, anterior, posterior, left posterior, right/medial uncinate, and mesenteric (5-16). Most of these approaches are designed to facilitate the early separation of the inferior pancreato-duodenal artery (IPDA), which is the principal pancreatic artery arising from the SMA. However, the

exposure of multiple peripancreatic feeding arteries is technically challenging, particularly for ISs, because the IPDA and the first-second jejunal arteries arise from the posterior surface of the SMA in a location that is difficult to surgically access.

The original intestinal de-rotation method was described by Sugiyama and was used to simplify the anatomical situation around the SMA and superior mesenteric vein (SMV) (17). The method involves the elimination of the 270° counter-clockwise rotation of the small intestine around the SMA. The biggest advantage of this method is that by moving the SMA to the right and posterior to the SMV, a flat mesenteric plane can be established along the right side of the SMA. This method basically represents a subtype of the right/medial uncinate approach and is intended to permit easy manipulation of the IPDA and some of the jejunal arteries.

We have modified the original method with the aim of developing a complete artery-first approach. The modified version consists of a two-step procedure: the first step replicates the original intestinal de-rotation method, and the second step involves a switch to the posterior approach to separate all the superior feeding arteries from the SMA after the IPDA and first jejunal artery (J1a) have been manipulated. Because of the complexity of this procedure, in the present study, we aimed to determine whether the intestinal de-rotation method for PD would be as successful in the hands of ISs as it is in those of experienced surgeons (ESs).

Abbreviations

PD : pancreatoduodenectomy ; ISs : inexperienced surgeons ; ESs : experienced surgeons ; SMA : superior mesenteric artery ; SMV : superior mesenteric vein ; IPDA : inferior pancreatoduodenal artery ; IPDV : inferior pancreatoduodenal vein ; J1a : first jejunal artery ; J1v : first jejunal vein ; PV : portal vein ; CHA : common hepatic artery ; GDA : gastroduodenal artery ; SD : standard deviation

Received for publication July 24, 2023 ; accepted November 23, 2023.

Address correspondence and reprint requests to Yuji Morine M.D., FACS, Department of Surgery, Institute of Biomedical Sciences, Tokushima University Graduate School, 3-18-15 Kuramoto-cho, Tokushima 770-8503, Japan and Fax : +81-88-631-9698. E-mail : ymorine@tokushima-u.ac.jp

MATERIAL AND METHODS

Surgical procedure

We performed a subtotal stomach-preserving PDs to remove tumors located close to the head of the pancreas and lower bile duct in the patients. An upper midline abdominal incision was performed, then the intestine was de-rotated as previously described (17) (Fig. 1). Duodenal mobilization was performed, and the distal half of the duodenum was reflected. The right-sided colon was mobilized along the fusion fissure and the ileocecal area was completely dissected toward the Treiz ligament, along the left side of the small intestinal mesentery. Then, the lesser sac was entered and the anterior surface of the SMV was identified along the lower aspect of the head of the pancreas. After the division of the Treiz ligament, the duodenum, distal small intestine, and right-sided colon were rotated clockwise around the axis of the SMA. This rotation linearizes the intestine from the second quarter of the duodenum to the jejunum and positions the SMA to the right of the SMV (Fig. 2). As a consequence, a flat mesenteric plane is established along the right side of the SMA without any substantial traction being necessary, and the involvement of the SMA in the tumor can be easily checked.

Subsequently, the upper jejunum was transected and the

mesentery was incised toward the SMA. The common root of the IPDA and J1a could then be easily dissected and separated from the SMA, because they could be directly visualized (Fig. 3). The SMA nerve plexus was dissected as required, according to the extent of the tumor. In addition, the first jejunal vein (J1v), including the inferior pancreato-duodenal vein (IPDV), could also be manipulated *via* this approach. After the division of the IPDA and J1a, the resection line was extended toward a caudal direction of SMA using a right posterior approach. Subsequently, all the arteries originating from the SMA were separated, as part of the complete artery-first approach, and the head of the pancreas was separated from the SMA (dissection of pancreatic head plexus I and II), while confirming the dorsal side of SMV and portal vein (PV) (Fig. 4). The posterior part of the head of the pancreas could then be completely separated from the SMA. In this way the surgeon could avoid the “point of no return” associated with the standard procedure and instead identify whether the tumors were non-resectable at an early stage of the procedure.

Next, the hepatoduodenal ligament was dissected, skeletonization of the hepatic artery and PV was performed, and the gallbladder and common bile duct were isolated. The common hepatic artery (CHA) was dissected as far as the celiac trunk, and the gastroduodenal artery was separated, after confirming

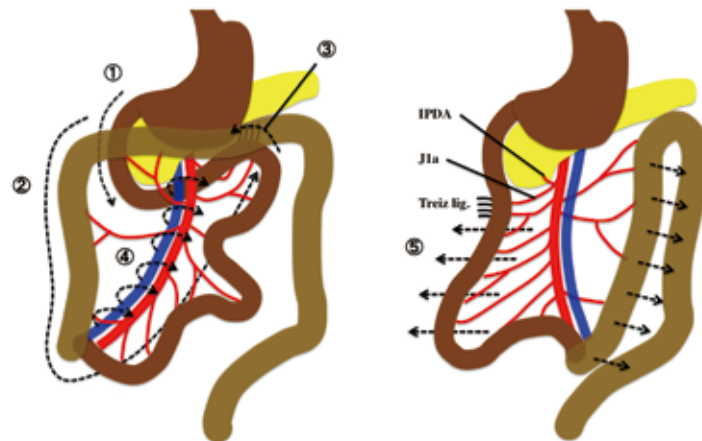


Figure 1. The de-rotation procedure

This consisted of five components, as follows: ① Kocker's maneuver, ② Mobilization of the right-sided colon and dissection of the attachment of the small intestinal mesentery, ③ Division of the Treiz ligament, ④ Clockwise rotation of the mesentery around the SMA axis, and ⑤ Linearization of the gut from the duodenum to upper jejunum.

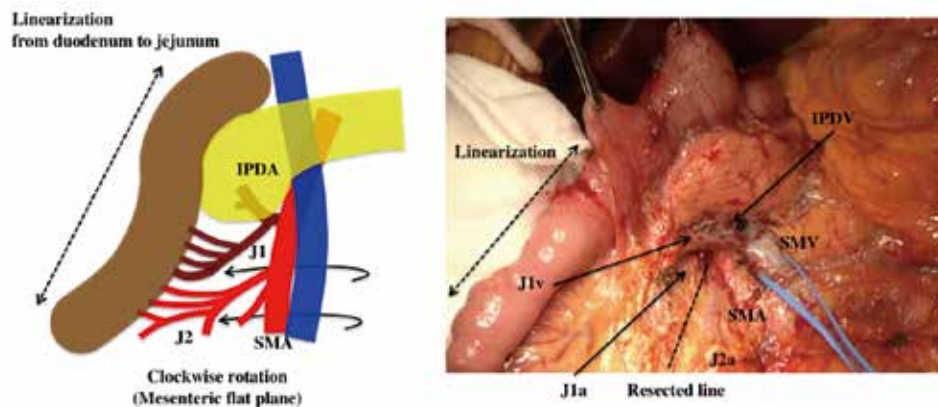


Figure 2. Linearization of the duodenum and upper jejunum reveals the SMA to the right of the SMV. A resection line along the first jejunal artery can be easily established.

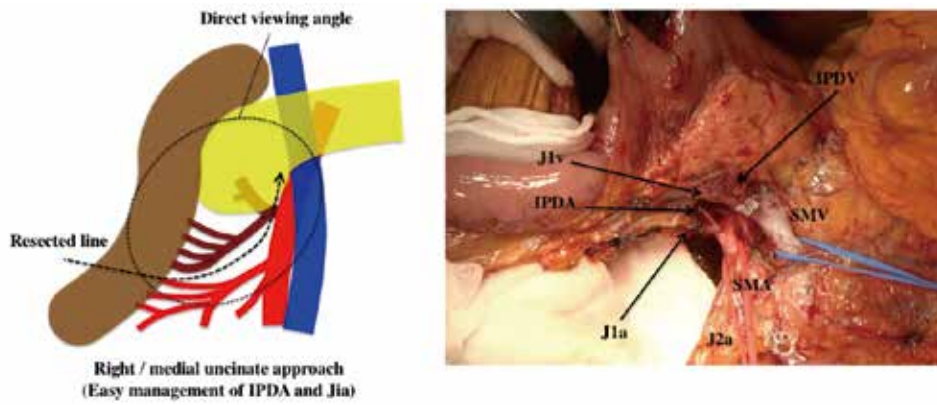


Figure 3. After the separation of the upper jejunum and mesentery, the root of the IPDA and J1a can be directly visualized

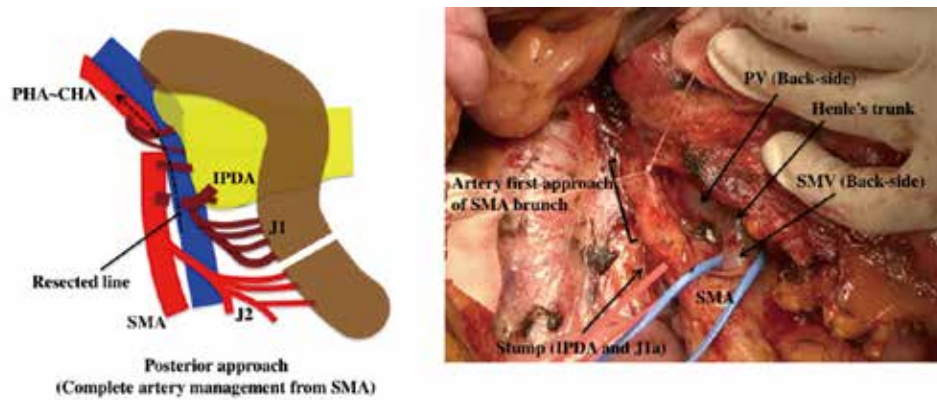


Figure 4. A posterior view, showing all the superior feeding arteries, separated along the resection line from the SMA
The SMA nerve plexus is dissected if it is involved in the tumor.

hepatic arterial flow by clamping. The stomach was divided using a stapler device.

For the next step, the right posterior approach was used once again ; the posterior part of the head of the pancreas was separated from the SMV, without dividing the pancreatic neck (Fig. 5). If the portal venous system was involved in the tumor, the affected portion of the vein was swiftly resected, then an end-to-end anastomosis was performed. At this stage, PD using the intestinal de-rotation method could be safely performed, after which the intestine was restored to its preoperative position and orientation. The right colon and mesentery of the small intestine were then anchored to the retroperitoneum using several sutures and the digestive system was constructed using a modified version of Child's procedure. For the end-to-side anastomotic pancreatico-jejunostomy, the modified Kakita or modified Blumgart anastomosis was performed, with the placement of an internal pancreatic ductal drainage stent (18, 19), and an end-to-side hepaticojejunostomy was performed approximately 15 cm distal to the site of the pancreatico-jejunostomy using a single layer of continuous sutures with absorbable suture. The end-to-side anastomotic gastro-jejunostomy was performed *via* an ante-colic approach using an Albert-Lembert anastomosis, and the side-to-side jejuno-jejunostomy (Brawn's anastomosis) was performed between approximately 40 cm distal to the site of the hepaticojejunostomy and approximately 15 cm distal to the

site of the gastro-jejunostomy, using an Albert-Lembert anastomosis. After careful hemostasis, the dorsal aspect of the pancreatojejunostomy site was covered with the greater omentum. Two closed drains were individually placed on the ventral aspect of the pancreatojejunostomy site and in the right retroperitoneal space.

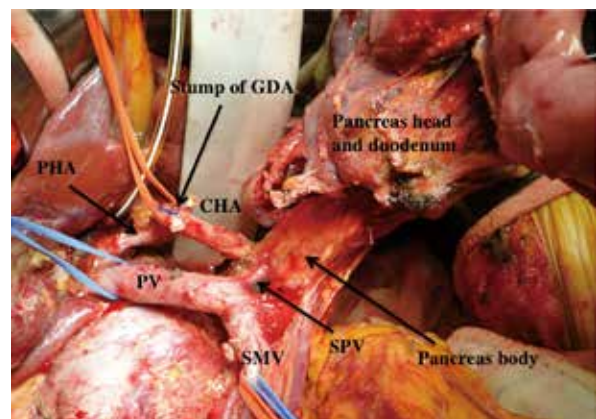


Figure 5. Final posterior view showing the complete separation of the head of the pancreas and duodenum from the SMA and SMV, without the separation of the neck of the pancreas

Patients

Seventy patients who underwent pancreatoduodenectomy with the intestinal de-rotation method between June 2014 and June 2018 in Tokushima University Hospital were retrospectively enrolled in the study. Patients who had undergone hepatobiliary surgery prior to the PD were excluded. All the patients had undergone R0 resections. This study was conducted in accordance with the tenets of the Declaration of Helsinki, and approved by the Institutional Review Board of the University of Tokushima Graduate School authorized (approved no. : 3215) and also, all the patients provided their written informed consent.

The participants comprised 38 male and 32 female with a mean age of 70.7 years (range 20–86 years). The patients were allocated to an ES group if their surgery had been performed by a surgeon who was certified by the Japanese Society of Hepato-Biliary-Pancreatic Surgery, or to an IS group if their surgery had been performed by a surgeon with <12 years' experience of general surgery. We retrospectively compared data relating to pre- and intra-operative factors and postoperative complications between these two groups.

Postoperative complications were categorized using the Clavien-Dindo scale. Postoperative pancreatic fistula (POPF) was defined using the International Study Group of Pancreatic Fistula criteria and delayed gastric emptying was defined using the International Study Group of Pancreatic Surgery criteria.

Statistics

Statistical analyses were performed using JMP 11.2.0. software (SAS, Campus Drive, Cary, NC, USA). Data are presented as the mean \pm standard deviation (SD). The relationships between the group and clinicopathological variables were analysed using the Mann–Whitney *U*-test or Fisher's exact test. Statistical significance was accepted when $p < 0.05$.

RESULTS

Patient characteristics and intraoperative outcomes

ISs performed the surgery using the de-rotation method in 50 patients (71.4%). Table 1 shows a comparison of the clinicopathological characteristics of the patients and the intraoperative outcomes, according to the experience of the surgeon. No significant difference between the ES and IS groups was observed with respect to the general status of the patients, including the body mass index (BMI) of the patients. The type of tumor of the head of the pancreas and the surgical indications were similar in the two groups.

Regarding the intraoperative outcomes, six patients in the ES group (12.0%) underwent combined portal vein resection, which was not significantly different to the IS group ($p = 0.7348$). The durations of surgery in the ES and IS groups were 402 ± 68 min

Table 1. Patient characteristics and intraoperative factors

Factors		ES group (n = 20)	IS group (n = 50)	p value
<u>Patient characteristics</u>				
Age	Mean \pm SD (year)	72.0 \pm 9.8	70.2 \pm 10.8	0.5367
Gender	Male / Female	10 / 10	28 / 22	0.6489
BMI	Mean \pm SD	22.0 \pm 3.2	22.2 \pm 3.1	0.7782
Diabetes mellitus	- / +	15 / 5	33 / 17	0.4637
Serum albumin levels	Mean \pm SD (g/dl)	3.6 \pm 0.6	3.7 \pm 0.5	0.3536
Serum total bilirubin levels	Mean \pm SD (mg/dl)	2.2 \pm 3.4	1.4 \pm 1.4	0.1746
Preoperative biliary drainage	- / +	7 / 13	23 / 27	0.4008
Disease	Malignant / Benign	16 / 3	18 / 4	0.8391
Type of tumor	Pancreas cancer	8	21	0.6487
	Biliary cancer	8	8	
	Duodenal cancer	0	2	
	IPMN	0	5	
	NET	1	3	
	Metastatic tumor	1	2	
	Benign disease	2	2	
Preoperative chemotherapy	- / +	17 / 3	45 / 5	0.5525
<u>Intraoperative outcomes</u>				
Portal vein resection	- / +	17 / 3	44 / 6	0.7348
Operative time	Mean \pm SD (min)	402 \pm 68	483 \pm 51	<0.0001
Blood loss	Mean \pm SD (min)	252 \pm 190	269 \pm 188	0.7304
Pancreas state	Hard / Soft	8 / 12	18 / 32	0.7544
Main pancreatic duct	Mean \pm SD (mm)	3.5 \pm 1.2	4.4 \pm 2.0	0.0614
Pancreaticoduodenectomy	Kakita / Blumgart	15 / 5	37 / 13	0.9311

and 483 ± 51 min; thus, surgery was significantly longer in the IS group ($p < 0.0001$). Meanwhile, the blood loss was similar in the two groups ($p = 0.6584$). The state of the pancreas (hard or soft) was similar in the two groups. The main pancreatic duct in the ES and IS groups were 3.5 ± 1.2 mm and 4.4 ± 2.0 mm, and tended to be thick in the IS group ($p = 0.0614$). Finally, there were no critical events or accidents during surgery in either groups.

Postoperative course and complications

There was no mortality during the present study, and the incidence of postoperative complications, which was defined as a Clavien-Dindo grade of $>III$, did not differ between the two groups. POPF was a major cause of postoperative complications, and Grade B pancreatic fistulae developed in four patients (20.0%) in the ES group and four patients (22.0%) in the IS group, and there was no significant difference in incidence between the groups. Two patient in the both ES and IS groups developed intra-abdominal abscess. Two patients in the IS group, intra-abdominal hemorrhage was provoked. The postoperative hospital stay of the IS group (32 ± 33 days) was similar compared to that of the ES group (33 ± 16 days) ($p = 0.9256$).

DISCUSSION

In the present study, we have used the intestinal de-rotation method when performing PD, which involved the use of both right/medial uncinete and posterior approaches after 270° counter-clockwise rotation of the small intestine around the SMA axis. The advantage of this method is that the SMA, SMV, and some of the branching jejunal vessels can be visualized in a single plane by linearizing the duodenum. As further consequences, a resection line along the first jejunal artery can be easily established and the root of the IPDA can be directly visualized. Subsequently, we used the posterior approach for the separation of all the superior feeding arteries from the SMA. The use of this method permitted us to easily achieve a complete artery-first approach for the SMA during PD, and the method was suitable for ISs. Indeed, we found no significant differences

in the peri-operative outcomes or the quality of the surgery, except for operative time, between patients who were operated on by ESs or ISs.

Several previous reports have asserted the superiority of the artery-first approach (5, 6), and two recent meta-analyses have demonstrated that the artery-first approach to PD may be associated with superior perioperative outcomes, including intraoperative blood loss, the incidence of Grade B/C pancreatic fistula, and the duration of the postoperative hospital stay, compared with alternative approaches (20, 21). Furthermore, the good surgical outcomes and R0 resectability improve the patients' long-term prognosis. Therefore, artery-first approaches have become standard for PD.

Six types of artery-first approach to PD can be defined: the superior, anterior, posterior, left posterior, right/medial uncinete, and mesenteric approaches. Five of these, not including the superior approach, aim to isolate the IPDA at an early stage of the procedure. For instance, the mesenteric approach, which was first proposed by Nakao and is becoming the standard artery-first approach for tumors of the head of the pancreas in Japan, involves the initial isolation of the SMA and SMV at the base of the transverse mesocolon, before the mobilization of the head of the pancreas, and permits the ready and early dissection of the right lateral border of the SMA (22). However, the IPDA and first-second jejunal arteries often share a common trunk and arise from the posterior surface of the SMA within a relatively narrow working space. Therefore, the exposure of these multiple peripancreatic feeding arteries is technically difficult and challenging for ISs, especially in patients in whom the IPDA arises from the caudal site of SMA. Other artery-first approaches are associated with similar difficulties because of a restricted view of the SMA.

In the present study, we have reviewed the use of the intestinal de-rotation method and shown how the technical difficulties of the artery-first approach to PD can be reduced for ISs using this method. It permits easier manipulation of the root of the IPDA, IPDV, and some branching jejunal vessels that connect to the SMA and SMV by providing a wide, flat surgical field that can be viewed directly. Because of this, ESs can readily provide

Table 2. Postoperative course and complications

Factors		ES group (n = 19)	IS group (n = 22)	p value
Clavien dindo $>III$	- / +	16 / 4	36 / 14	0.4890
Clavien dindo	Grade I	0	3	0.5641
	Grade II	4	5	
	Grade IIIa	4	13	
	Grade IIIb	0	1	
	Grade IV	0	0	
	Grade V	0	0	
POPF	None / A / B	15 / 1 / 4	36 / 3 / 11	0.9659
Delayed gastric empty	- / +	20 / 0	47 / 3	0.2628
Intra-abdominal abscess	- / +	18 / 2	48 / 2	0.3286
Intra-abdominal hemorrhage	- / +	20 / 0	48 / 2	0.3642
Liver abscess	- / +	20 / 0	49 / 1	0.5241
Chylous ascites	- / +	19 / 1	46 / 4	0.6597
Postoperative hospital stay	Mean \pm SD (day)	33 ± 16	32 ± 33	0.9256

support for ISs, who can obtain safe and stable peri-operative outcomes using this method, while operative time was somewhat prolonged.

The present study had several limitations. It was retrospective and relatively small; therefore there may be some bias in the outcomes. However, we were able to demonstrate that intestinal de-rotation may represent a useful artery-first approach to PD. A larger, prospective randomized trial should be conducted in the future to confirm these findings.

ACKNOWLEDGEMENTS

Not applicable.

AUTHORS' CONTRIBUTIONS

Yuji Morine designed this study and acquired the data and drafted the article. All the authors equally took part in the conception of this study; acquisition, drafting and revising of the paper; final approval of the paper; and agreement to be accountable for the integrity of the case report. All authors read and approved the final manuscript.

FUNDING

There was no funding which need to be reported.

AVAILABILITY OF DATA AND MATERIAL

The datasets during and/or analyzed during the current study available from the corresponding author on reasonable request.

DECLARATIONS

Ethical approval and consent to participate

All procedures performed in studies involving human participants were in accordance with the ethical standards of the Institutional Review Board of the University of Tokushima Graduate School (approved no. : 3215) and with the 1964 Helsinki declaration and its later amendments or comparable ethical standards. All the patients provided their written informed consent in this study.

Consent for publication

All the patients provided their written informed consent for publication.

Competing interests

The authors declare that they have no competing interest.

REFERENCES

1. Kawai M, Tani M, Ina S, Hirono S, Nishioka R, Miyazawa M, Uchiyama K, Shimamoto T, Yamaue H : CLIP Method (Preoperative CT Image-Assessed Ligation of Inferior Pancreaticoduodenal Artery) Reduces Intraoperative Bleeding During Pancreaticoduodenectomy. *World J Surg* 21(1) : 82-87, 2008
2. Horiguchi A, Ishihara S, Ito M, Asano Y, Yamamoto T, Miyakawa S : Three-dimensional Models of Arteries Constructed Using Multidetector-Row CT Images to Perform Pancreaticoduodenectomy Safely Following Dissection of the Inferior Pancreaticoduodenal Artery. *J Hepatobiliary Pancreatic Sci* 17(4) : 523-526, 2010
3. Marzano E, Piardi T, Soler L, Diana M, Mutter D, Marescaux J, Pessaux P : Augmented Reality-Guided Artery-First Pancreatico-Duodenectomy. *J Gastroenterol Surg* 17(11) : 1980-1983, 2013
4. Onda S, Okamoto T, Kanehira M, Suzuki F, Ito R, Fujioka S, Suzuki N, Hattori A, Yanaga K : Identification of Inferior Pancreaticoduodenal Artery During Pancreaticoduodenectomy Using Augmented Reality-Based Navigation System. *J Hepatobiliary Pancreatic Sci* 21(4) : 287-287, 2014
5. P Sanjay, K Takaori, S Govil, S V Shrikhande, J A Windsor : 'Artery-first' Approaches to Pancreaticoduodenectomy. *Br J Surg* 99(8) : 1027-1035, 2012
6. Pandanaboyana S, Bell R, Windsor J : Artery first approach to pancreaticoduodenectomy : current status. *ANZ J Surg* 86(3) : 127-132, 2016
7. Weitz J, Rahbari N, Koch M, Büchler MW : The "Artery First" Approach for Resection of Pancreatic Head Cancer. *J Am Coll Surg* 210 (2) : e1-4, 2010
8. Dumitrascu T, David L, Popescu I : Posterior versus standard approach in pancreaticoduodenectomy : a case-match study. *Langenbecks Arch Surg* 395 : 677-684, 2010
9. Hackert T, Werner J, Weitz J, Schmidt J, Büchler MW : Uncinate process first—a novel approach for pancreatic head resection. *Langenbecks Arch Surg* 395 : 1161-1164, 2010
10. Shrikhande SV, Barreto SG, Bodhankar YD, Suradkar K, Shetty G, Hawaldar R, Goel M, Shukla PJ : Superior mesenteric artery first combined with uncinate process approach versus uncinate process first approach in pancreaticoduodenectomy : a comparative study evaluating perioperative outcomes. *Langenbecks Arch Surg* 396 : 1205-1212, 2011
11. Kawabata Y, Tanaka T, Nishi T, Monma H, Yano S, Tajima Y : Appraisal of a total meso-pancreatoduodenum excision with pancreaticoduodenectomy for pancreatic head carcinoma. *EJSO* 38 : 574-579, 2018
12. Peng F, Wang M, Zhu F, Tian R, Shi CJ, Xu M, Wang X, Shen M, Hu J, Peng SY, Qin RY : "Total Arterial Devascularization First" Technique for Resection of Pancreatic Head Cancer During Pancreaticoduodenectomy. *J Huazhong Univ Sci Technol* 33(5) : 687-691, 2013
13. Nakamura M, Nakashima H, Tsutsumi K, Matsumoto H, Muta Y, Ueno D, Yoshida K, Hino K, Urakami A, Tanaka M : First jejunal vein oriented mesenteric excision for pancreaticoduodenectomy. *J Gastroenterol* 489 : 89-995, 2013
14. Rose JB, Rocha F, Alseidi A, Helton S : Posterior 'Superior Mesenteric Artery First' Approach for Resection of Locally Advanced Pancreatic Cancer. *Ann Surg Oncol* 21 : 1927-1928, 2014
15. Fujioka S, Misawa T, Yanaga K : Isolating tape method is useful for an early judgment of curability during pancreaticoduodenectomy for pancreatic cancer. *J Hepatobiliary Pancreat Sci* 23 : E20-E24, 2016
16. Zhu J, Han D, Li X, Pan F, Ma J, Kou J, Fan H, Lang R, He Q : Inferior Infracolic 'Superior Mesenteric Artery First' Approach with a No-Touch Isolation Surgical Technique in Patients with a Borderline Resectable Cancer of the Pancreatic Head. *Ann Surg Oncol* 23 : S976-S980, 2016
17. Sugiyama M, Suzuki Y, Nakazato T, Yokoyama M, Kogure M, Abe N, Masaki T, Mori T : Intestinal derotation procedure for facilitating pancreaticoduodenectomy. *Surgery* 159(5) : 1325-1332, 2016
18. Kakita A, Yoshida M, Takahashi T : History of pancreaticojejunostomy in pancreaticoduodenectomy : development

- of a more reliable anastomosis technique. *J Hepatobiliary Pancreat Surg* 8 : 230-237, 2001
19. Fujii T, Sugimoto H, Yamada S, Kanda M, Suenaga M, Takami H, Hattori M, Inokawa Y, Nomoto S, Fujiwara M, Kodera Y : Modified Blumgart anastomosis for pancreaticojejunostomy : technical improvement in matched historical control study. *J Gastrointest Surg* 18(6) : 1108-15, 2014
 20. Negoii I, Hostiuc S, Runcanu A, Negoii RI, Beuran M : Superior Mesenteric Artery First Approach Versus Standard Pancreaticoduodenectomy : A Systematic Review and Meta-Analysis. *Hepatobiliary Pancreat Dis Int* 16(2) : 127-138, 2017
 21. Ironside N, Barreto SG, Loveday B, Shrikhande SV, Windsor JA, Pandanaboyana S : Meta-analysis of an Artery-First Approach Versus Standard Pancreatoduodenectomy on Perioperative Outcomes and Survival. *Br J Surg* 105(6) : 628-636, 2018
 22. Nakao A, Takagi H : Isolated Pancreatectomy for Pancreatic Head Carcinoma Using Catheter Bypass of the Portal Vein. *Hepatogastroenterology* 40(5) : 426-429, 1993