

CASE REPORT

Full-Endoscopic Foraminal Decompression for Foraminal Stenosis Following Osteoporotic Vertebral Fracture in an Elderly Woman Under Local Anesthesia : A Case Report

Yu Otake^{1,2}, Fumitake Tezuka¹, Kazuta Yamashita¹, Masatoshi Morimoto¹, Kosuke Sugiura¹, Makoto Takeuchi¹, Shunsuke Tamaki¹, Junzo Fujitani¹, Hiroshi Kageyama¹, and Koichi Sairyo¹

¹Department of Orthopedics, Tokushima University, Tokushima, Japan, ²Department of Orthopedic Surgery, St. Lukas Hospital, Tokyo, Japan

Abstract : Osteoporotic vertebral fracture (OVF) is common in the elderly population. In this report, we describe a case with radiculopathy due to foraminal stenosis caused by OVF in a very elderly patient that was treated successfully by full-endoscopic foraminotomy under local anesthesia. The patient was an 89-year-old woman who presented with a chief complaint of left leg pain for 5 years. She visited a couple of hospitals and finally consulted us to determine the exact cause of the pain. Computed tomography scans were obtained and selective nerve root block at L3 was performed. The diagnosis was radiculopathy at L3 due to foraminal stenosis following OVF. The patient had severe heart disease, so we decided to avoid surgery under general anesthesia and planned full-endoscopic spine surgery under local anesthesia. We performed transforaminal full-endoscopic lumbar foraminotomy at L3-L4 to decompress the L3 nerve root. The leg pain disappeared completely immediately after surgery. Postoperative computed tomography confirmed appropriate bone resection. The leg pain did not recur during a year of postoperative follow-up. OVF may cause lumbar radiculopathy as a result of foraminal stenosis, and transforaminal full-endoscopic lumbar foraminotomy under local anesthesia would be the best option in an elderly patient with poor general condition. *J. Med. Invest.* 71 : 179-183, February, 2024

Keywords : full-endoscopic spine surgery, foraminal stenosis, osteoporotic vertebral fracture, local anesthesia, aged population

INTRODUCTION

Osteoporotic vertebral fracture (OVF) is common in the elderly (1). The main symptom is low back pain, and conservative therapy is usually recommended as initial treatment (2-4). However, surgical intervention is required if bony fragments compress neural tissue, such as the spinal cord, nerve roots, or cauda equina (5, 6). Foraminal stenosis following a compression fracture can cause radiculopathy, but this pathology seems to be comparatively rare (7). Sasaki *et al.* (7) reviewed 66 cases with compression fracture and found that only 3 (4.5%) had foraminal stenosis.

Of the 3 types of canal stenosis-foraminal, lateral recess and central stenosis-foraminal stenosis is the most challenging because it is hard to decompress using traditional posterior surgery. The gold standard treatment for foraminal stenosis would be spinal fusion following decompression (8, 9). However, spinal fusion is highly invasive. Minimally invasive full-endoscopic spinal surgery (FESS) was recently developed (10-12) and can be used to decompress foraminal stenosis without fusion under local anesthesia (13, 14). Therefore, foraminotomy with FESS would be the least invasive surgical treatment for foraminal stenosis.

In this report, we describe a case of foraminal stenosis following compression fracture that was treated by foraminotomy with FESS.

CASE REPORT

The patient was an 89-year-old woman who had complained of low back pain and left anterior thigh pain while walking for 5 years. She had been diagnosed as having OVF at L3 (Fig 1) and was treated conservatively; however, her symptoms worsened and she was referred to our department for further examination and surgical treatment. On physical examination, there was no muscle weakness in either of the lower limbs on manual muscle testing. A femoral nerve stretch test was positive on the left side. Deep tendon reflexes were normal bilaterally. L3 vertebral fracture had achieved bone union on plain radiographs and computed tomography (CT) scans. On lateral dynamic (flexion-extension) images (Fig 1C and 1D), there was no slippage and only 5 degrees of the spinal movement between L2 caudal endplate and L4 cranial endplate. Based on the findings on magnetic resonance imaging (Fig 2) and CT scans (Fig 3A, 3B), the diagnosis was left L3-L4 intervertebral foraminal stenosis associated with a vertebral fracture at L3. The pain in the left anterior thigh was reproduced during selective nerve root block with 1% xylocaine at L3 on the left side. Therefore, we attributed her symptoms to an L3 nerve root disorder caused by stenosis of the intervertebral foramen at L3-L4 following a vertebral fracture. Because she had severe chronic heart failure and a past medical history of transcatheter aortic valve implantation, we decided to avoid lumbar instrumentation surgery with general anesthesia and planned left-sided transforaminal full-endoscopic lumbar foraminotomy at L3-L4 under local anesthesia.

Surgical procedure

The patient was placed prone on a standard spine frame and operated on under local anesthesia. The optimal position for insertion of the cannula was determined to be 5.5 cm to the left of the midline on preoperative CT images. After marking and draping, local anesthesia was performed using 1% xylocaine.

Received for publication November 20, 2022; accepted January 11, 2024.

Address correspondence and reprint requests to Koichi Sairyo, MD, PhD, Professor and Chairman, Department of Orthopedics, Tokushima University Graduate School, 3-18-15 Kuramoto, Tokushima 770-8503, Japan and Fax: +81-88-633-0178. E-mail: sairyo@kaiyokun@gmail.com

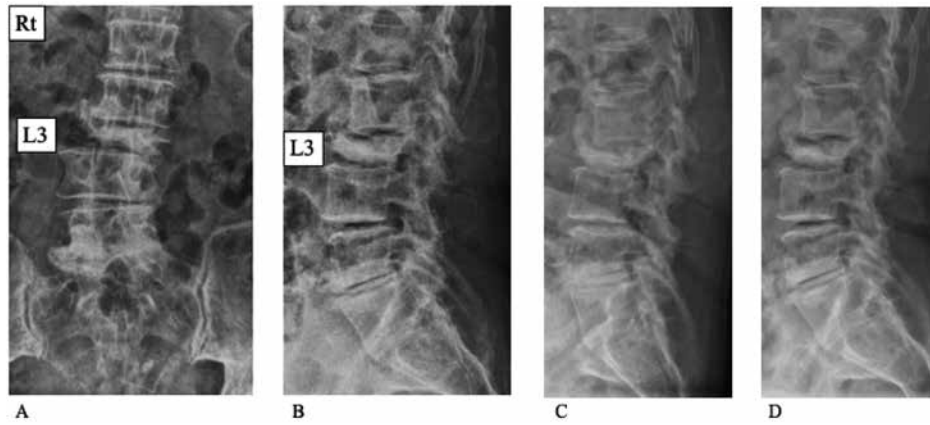


Fig 1. Preoperative plain radiographs of the lumbar spine. A : Scoliotic change due to the collapsed L3 vertebra and lumbar spondylosis. B : L3 vertebral fracture (the height of vertebral body collapsed by less than 50%) and local kyphotic change at the L2-L3 intervertebral disc level. C : Lateral view in flexion (anterior flexion). D : Lateral view in extension (posterior flexion).

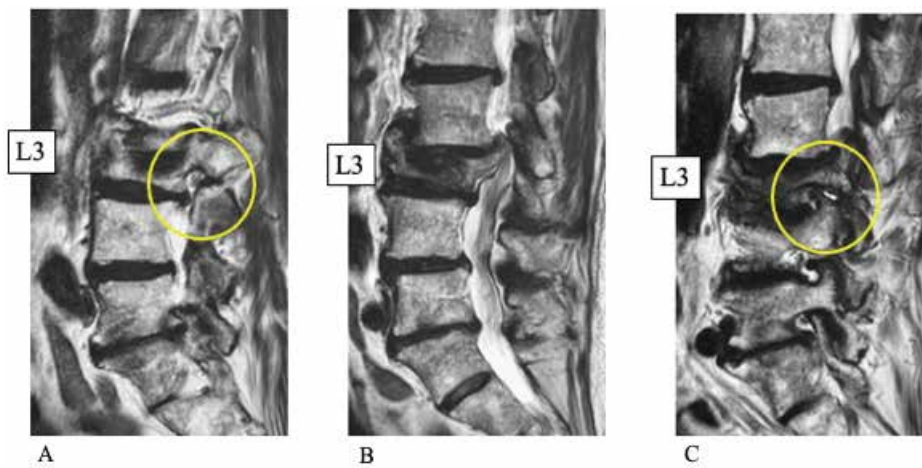


Fig 2. Preoperative T2-weighted magnetic resonance images. A : Right para-sagittal slice showing no foraminal stenosis at L3-L4 (yellow circle). B : Mid-sagittal slice showing spinal canal stenosis due to a posterior wall fracture of the L3 vertebral body. C : Left para-sagittal slice showing foraminal stenosis at L3-L4 due to the superior articular process of L4 and disc bulging at L3-L4 (yellow circle), which caused left L3 nerve root impingement.

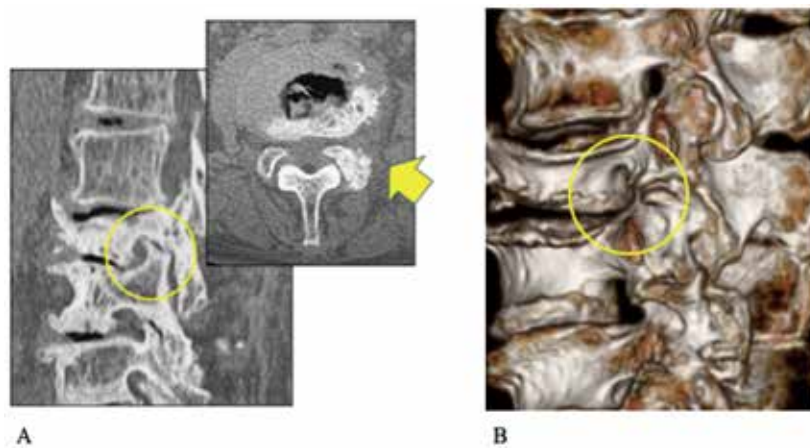


Fig 3. Preoperative computed tomography (CT) images. A : Multi-planar reconstructed sagittal CT image showing foraminal stenosis due to the superior articular process (SAP) of L4 (yellow circle) and an axial CT image showing sclerotic change and a bone spur on the left SAP of L4 (yellow arrow). B : Three-dimensional reconstructed CT image showing narrowing of the intervertebral foramen on the left at L3-L4.

The patient was then fully anesthetized up to the base of the L4 pedicle, and intraoperative discography was performed using 2 ml of a mixture of contrast medium and indigo carmine while checking the lateral view radiographically. We made an approximately 8-mm skin incision and enlarged the corridor sequentially using serial dilators via a transforaminal approach. We then placed an external cylinder and inserted an endoscope into the intervertebral foramen. Next, we removed the superior articular processes above the upper pedicle line at L4 and performed bony decompression around the L3 nerve root. We also excised the dorsal yellow ligament to ensure that the L3 nerve root was completely decompressed. After adequate hemostasis, we removed the endoscope and closed the wound. There were no surgery-related complications.

Postoperative course

Immediately after the surgery, the left anterior thigh pain improved and the patient started walking 1 hour later. By the next morning, the pain had disappeared. There were no intraoperative or postoperative complications, such as dural tear, epidural hematoma, or exiting nerve root injury. Her postoperative course was excellent, with no recurrence of pain and no limitation of activity within the year following surgery. Postoperative CT showed enlargement of the L3-L4 intervertebral foramen (Fig 4A, 4B).

DISCUSSION

Foraminal stenosis with compression fracture

Compression fracture is very common in the elderly population, and the main symptom is low back pain, not radiculopathy. In a multicenter study at 15 hospitals, Ito *et al.* (15) found that only 5.5% of 738 patients with OVF had neurological symptoms. Foraminal stenosis causing radiculopathy is rarely associated with a compression fracture. However, foraminal stenosis following compression fracture is not uncommon at lumbar levels below L3. Nakajima *et al.* (16) found that 18 (60%) of 30 cases with OVF below L3 had foraminal stenosis, which they treated by decompression with short fusion using a posterior approach. Lin *et al.* (17) reviewed 15 cases with foraminal stenosis after compression fracture and found that 12 (80%) had a compression

fracture below L3. Similarly, Philips *et al.* (18) reported 3 cases of foraminal stenosis following OVF, all of which were at L3. Therefore, a compression fracture is more likely to be accompanied by foraminal stenosis at a lower lumbar level than at a thoracolumbar level. Indeed, our patient developed symptoms following OVF at L3.

Surgical strategy for foraminal stenosis

The gold standard surgical treatment for foraminal stenosis would be decompression and fusion (8, 9) under general anesthesia. Fujibayashi *et al.* (8) investigated transforaminal lumbar interbody fusion via a paraspinous approach for foraminal stenosis and concluded that this technique is a minimally invasive, safe, and secure procedure for treating lumbar foraminal lesions. Lateral access fusion surgery is another surgical technique that can be used for indirect decompression of foraminal stenosis. Mahatthanatrakul *et al.* (9) performed oblique lumbar interbody fusion to obtain indirect decompression in 46 cases with foraminal stenosis. They measured the foraminal cross-sectional area before and after surgery and found an increase of more than 40% postoperatively. In a review of 66 cases of OVF, Sasaki *et al.* (7) found radiculopathy in 10 cases, 3 of which had foraminal stenosis. Conservative treatment was effective in 1 case and the remaining 2 needed surgical treatment. One of the 2 cases had foraminal stenosis with canal stenosis that was treated by decompression with posterior fusion surgery. In the remaining case, they performed vertebroplasty using hydroxyapatite blocks in the pedicle; however, the clinical outcome was not good. Therefore, fusion following decompression seems to be effective for foraminal stenosis following OVF. Although decompression and fusion surgery is undoubtedly the gold standard, a minimally invasive approach may be preferable in elderly patients with osteoporosis.

Micro-endoscopic discectomy (MED) is another type of minimally invasive surgery that can be used for foraminal decompression (19). Decompression without fusion surgery has been attempted using MED. Ishimoto *et al.* (20) used MED to decompress foraminal stenosis at L2 following an OVF in an 80-year-old woman. MED using a tubular retractor is a minimally invasive technique that would be categorized as endoscope-assisted surgery (21). MED requires a 16-mm skin incision and general anesthesia (22). However, transforaminal FESS can be

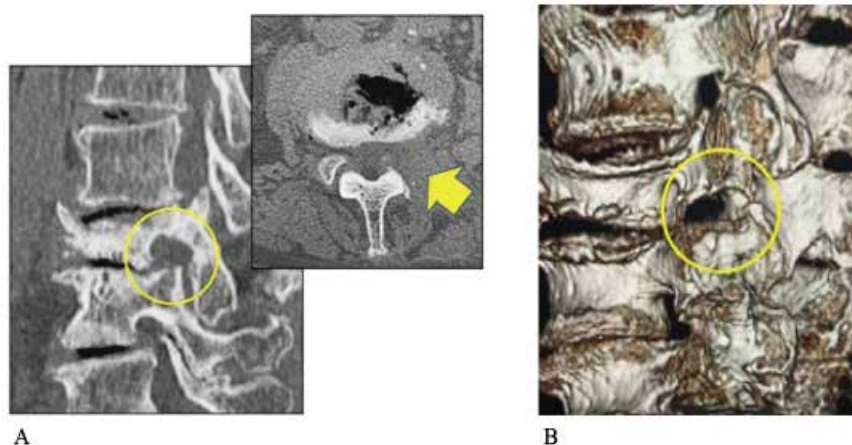


Fig 4. Postoperative CT images. A : Multi-planar reconstructed sagittal and axial CT images showing adequate bony decompression after resection of the left SAP of L4 (yellow circle and arrow). B : Three-dimensional reconstructed CT image showing enlargement of the intervertebral foramen on the left at L3-L4.

conducted with a skin incision that is only 7-8 mm (10-14). FESS is the best option for elderly patients with poor general condition and foraminal stenosis following OVF because it is minimally invasive and can be performed under local anesthesia (23, 24). However, information on this surgical technique in the literature remains sparse (17, 18, 25).

Full-endoscopic foraminotomy

In 2022, Zhao *et al.* (25) reported use of FESS foraminotomy without fusion surgery to treat a compression fracture at L4 in a 79-year-old man with foraminal stenosis. In that report, they mentioned that internal fixation is not suitable for elderly patients with osteoporosis in view of the greater risks of loosening of the internal fixation device and adverse reactions caused by surgical invasiveness in these patients. Another 2 articles reached a similar conclusion regarding the effectiveness of minimally invasive FESS in elderly patients (17, 18). Based on the literature (17, 18, 25) and our experience in the present case of this 89-year-old woman, we believe that foraminotomy for foraminal stenosis following OVF in elderly patients has the advantages of being minimally invasive in terms of the back muscles, requiring only a 7- to 8-mm skin incision, allowing ambulation soon after surgery, being feasible even in elderly patients with poor general condition under local anesthesia, and allowing direct visualization of the exiting nerve during decompression. Although this patient had achieved bone union after vertebral fracture and had no spinal instability, we don't have the patients with spinal instability due to non-union who treated by this surgery. We recommend that full-endoscopic foraminotomy should be the surgical treatment for the patients with foraminal stenosis related to OVF without spinal instability.

In conclusion, OVF may induce lumbar radiculopathy due to foraminal stenosis. Foraminotomy with FESS under local anesthesia could be the best option in elderly patients with poor general condition.

DISCLOSURE OF CONFLICT OF INTEREST

The authors have no conflict of interest concerning the materials or methods used in this study or the findings specified in this paper.

ETHICS DECLARATIONS

This study has been performed in accordance with the Declaration of Helsinki. The patient agreed the informed consent form for the publication as a case report.

REFERENCES

- Hagino H : Epidemiology of osteoporotic fractures. *Clin Calcium* 13 : 995-1002, 2003
- Jang HD, Kim EH, Lee JC, Choi SW, Kim K, Shin BJ : Current Concepts in the Management of Osteoporotic Vertebral Fractures : A Narrative Review. *Asian Spine J* 14 : 898-909, 2020
- Prost S, Pesenti S, Fuentes S, Tropiano P, Blondel B : Treatment of osteoporotic vertebral fractures. *Orthop Traumatol Surg Res* 107 : 102779, 2021
- Kato T, Inose H, Ichimura S, Tokuhashi Y, Nakamura H, Hoshino M, Togawa D, Hirano T, Haro H, Ohba T, Tsuji T, Sato K, Sasao Y, Takahata M, Otani K, Momoshima S, Tateishi U, Tomita M, Takemasa R, Yuasa M, Hirai T, Yoshii T, Okawa A : Comparison of Rigid and Soft-Brace Treatments for Acute Osteoporotic Vertebral Compression Fracture : A Prospective, Randomized, Multicenter Study. *J Clin Med* 8 : 198, 2019
- Yaman O, Zileli M, Sharif S : Decompression and fusion surgery for osteoporotic vertebral fractures : WFNS Spine Committee Recommendations. *J Neurosurg Sci Online* ahead of print 2022 Apr 5
- Terai H, Takahashi S, Yasuda H, Konishi S, Maeno T, Kono H, Matsumura A, Namikawa T, Kato M, Hoshino M, Tamai K, Toyoda H, Suzuki A, Nakamura H : Direct Lateral Corpectomy and Reconstruction Using an Expandable Cage Improves Local Kyphosis but Not Global Sagittal Alignment. *J Clin Med* 10 : 4012, 2021
- Sasaki M, Aoki M, Nishioka K, Yoshimine T : Radiculopathy caused by osteoporotic vertebral fractures in the lumbar spine. *Neurol Med Chir (Tokyo)* 51 : 484-489, 2011
- Fujibayashi S, Neo M, Takemoto M, Ota M, Nakamura T : Paraspinal-approach transforaminal lumbar interbody fusion for the treatment of lumbar foraminal stenosis. *J Neurosurg Spine* 13 : 500-508, 2010
- Mahatthanatrakul A, Kotheeranurak V, Lin GX, Hur JW, Chung HJ, Lokanath YK, Pakdeenit B, Kim JS : Do Obliquity and Position of the Oblique Lumbar Interbody Fusion Cage Influence the Degree of Indirect Decompression of Foraminal Stenosis? *J Korean Neurosurg Soc* 65 : 74-83, 2022
- Yeung AT : The evolution of percutaneous spinal endoscopy and discectomy : state of the art. *Mt Sinai J Med* 67 : 327-332, 2000
- Yeung A, Gore S : Endoscopic foraminal decompression for failed back surgery syndrome under local anesthesia. *Int J Spine Surg* 8 : 22, 2014
- Sairyo K, Chikawa T, Nagamachi A : State-of-the-art transforaminal percutaneous endoscopic lumbar surgery under local anesthesia : Discectomy, foraminoplasty, and ventral facetectomy. *J Orthop Sci* 23 : 229-236, 2018
- Yamashita K, Higashino K, Sakai T, Takata Y, Hayashi F, Tezuka F, Morimoto M, Chikawa T, Nagamachi A, Sairyo K : Percutaneous full endoscopic lumbar foraminoplasty for adjacent level foraminal stenosis following vertebral intersegmental fusion in an awake and aware patient under local anesthesia : A case report. *J Med Invest* 64 : 291-295, 2017
- Kamada M, Manabe H, Yamashita K, Sakai T, Maeda T, Sairyo K : Full-endoscopic Decompression of Foraminal Stenosis Caused by Facet Hypertrophy Contralateral to the Dominant Hand in a Baseball Pitcher : A Case Report. *NMC Case Rep J* 7 : 173-177, 2020
- Ito M, Harada A, Nakano T, Kuratsu S, Deguchi M, Sueyoshi Y, Machida M, Yonezawa Y, Matsuyama Y, Wakao N : Retrospective multicenter study of surgical treatments for osteoporotic vertebral fractures. *J Orthop Sci* 15 : 289-293, 2010
- Nakajima H, Uchida K, Honjoh K, Sakamoto T, Kitade M, Baba H : Surgical treatment of low lumbar osteoporotic vertebral collapse : a single-institution experience. *J Neurosurg Spine* 24 : 39-47, 2016
- Lin GX, Sun LW, Jhang SW, Ou SW, Chang KS, Tsai RY, Hu BS, Rui G, Chen CM : A Pilot Study of Radiculopathy Following Osteoporotic Vertebral Fracture in Elderly Patients : An Algorithmic Approach to Surgical Management. *Geriatr Orthop Surg Rehabil* 12 : 21514593211044912, 2021
- Philips GAC, Oshima Y, Inoue H, Kitagawa T, Iwai H, Takano Y, Inanami H, Koga H : Full-endoscopic spine surgery for radiculopathy after osteoporotic vertebral

- compression fractures : a case report. *J Spine Surg* 6 : 466-471, 2020
19. Murata S, Minamide A, Iwasaki H, Nakagawa Y, Hashizume H, Yukawa Y, Tsutsui S, Takami M, Okada M, Nagata K, Yoshida M, Schoenfeld AJ, Simpson AK, Yamada H : Microendoscopic decompression for lumbosacral foraminal stenosis : a novel surgical strategy based on anatomical considerations using 3D image fusion with MRI/CT. *J Neurosurg Spine* 1-7, 2020
 20. Ishimoto Y, Yamada H, Curtis E, Cooper C, Hashizume H, Minamide A, Nakagawa Y, Yoshida M : Spinal Endoscopy for Delayed-Onset Lumbar Radiculopathy Resulting from Foraminal Stenosis after Osteoporotic Vertebral Fracture : A Case Report of a New Surgical Strategy. *Case Rep Orthop* 2018 : 1593021, 2018
 21. Hofstetter CP, Ahn Y, Choi G, Gibson JNA, Ruetten S, Zhou Y, Li ZZ, Siepe CJ, Wagner R, Lee JH, Sairyo K, Choi KC, Chen CM, Telfeian AE, Zhang X, Banhot A, Lokhande PV, Prada N, Shen J, Cortinas FC, Brooks NP, Van Daele P, Kotheeranurak V, Hasan S, Keorochana G, Assous M, Härtl R, Kim JS : AOSpine Consensus Paper on Nomenclature for Working-Channel Endoscopic Spinal Procedures. *Global Spine J* 10 : 111S-121S, 2020
 22. Minamide A, Yoshida M, Iwahashi H, Simpson AK, Yamada H, Hashizume H, Nakagawa Y, Iwasaki H, Tsutsui S, Kagotani R, Sonekatsu M, Sasaki T, Shinto K, Deguchi T : Minimally invasive decompression surgery for lumbar spinal stenosis with degenerative scoliosis : Predictive factors of radiographic and clinical outcomes. *J Orthop Sci* 22 : 377-383, 2017
 23. Sairyo K, Yamashita K, Manabe H, Ishihama Y, Sugiura K, Tezuka F, Takata Y, Sakai T, Omichi Y, Takamatsu N, Hashimoto A, Maeda T : A novel surgical concept of transforaminal full-endoscopic lumbar undercutting laminectomy (TE-LUL) for central canal stenosis of the lumbar spine with local anesthesia : A case report and literature review. *J Med Invest* 66 : 224-229, 2019
 24. Hashimoto A, Tezuka F, Yamashita K, Morimoto M, Sugiura K, Takeuchi M, Takata Y, Sakai T, Maeda T, Sairyo : Planned Four-stage Transforaminal Full-endoscopic Lumbar Decompression under Local Anesthesia in a Patient with Severe Comorbidity. *NMC Case Rep J* 8 : 221-227, 2021
 25. Zhao QL, Hou KP, Wu ZX, Xiao L, Xu HG : Full-endoscopic spine surgery treatment of lumbar foraminal stenosis after osteoporotic vertebral compression fractures : A case report. *World J Clin Cases* 10 : 656-662, 2022