

## CASE REPORT

# Anesthetic management with remimazolam for a patient with hereditary angioedema : a case report

Kenshiro Kido, Takahiro Kato, Satoshi Kamiya, Shiho Satomi, Yukari Toyota, Takashi Kondo, and Yasuo M. Tsutsumi

*Department of Anesthesiology and Critical Care, Hiroshima University, Hiroshima Japan*

**Abstract :** Background : Hereditary angioedema (HAE), a genetic disorder caused by C1-inhibitor deficiency or dysfunction, may cause mucosal edema in the upper airway during tracheal intubation and extubation. Case Report : A 57-year-old man with HAE and a history of laryngeal edema, scheduled to undergo cervical laminoplasty under general anesthesia. General anesthesia was induced by continuous injection of remimazolam and remifentanyl, during which manual mask ventilation and intubation were performed without difficulty. The patient was extubated under deep anesthesia. After emergence from general anesthesia, he had no significant upper airway edema and was treated with a C1-inhibitor seven hours post-surgery because of slight tongue swelling. No additional airway edema was observed, and the patient was discharged from the intensive care unit the following day. Conclusions : Deep anesthesia tracheal extubation with remimazolam may be effective in preventing upper airway edema during anesthetic management in patients with HAE. *J. Med. Invest.* 71 : 184-186, February, 2024

**Keywords :** Hereditary angioedema, General anesthesia, Airway management

## BACKGROUND

Hereditary angioedema (HAE) is caused by C1-inhibitor deficiency or dysfunction (1). This disease is characterized by paroxysmal localized angioedema of the skin and mucosa. Severe angioedema can occur during the perioperative period and may cause upper airway obstruction during tracheal intubation and extubation.

Remimazolam, a benzodiazepine, is an ultrashort-acting  $\gamma$ -aminobutyric acid A receptor agonist. It was approved for the induction and maintenance of general anesthesia in adults in Japan on January 23, 2020 (2). It is characterized by fast onset and quick recovery compared to midazolam with few side effects (3, 4). We report a case of successful anesthetic management for cervical laminoplasty using remimazolam in a patient with HAE.

## CASE REPORT

Written informed consent was obtained from the patient for this case report.

A 57-year-old man (height, 169 cm ; weight, 56 kg) with cervical spondylotic myelopathy was scheduled to undergo cervical laminoplasty under general anesthesia in the prone position. He had previously been diagnosed with HAE and carried icatibant, a bradykinin-2 receptor antagonist in case of unexpected angioedema attack. He had a history of tracheal intubation due to upper airway obstruction and laryngeal edema following dental treatment five years previously. He had no history of tobacco smoking, drinking, and substance abuse. Preoperative blood testing showed that D-dimer was less than 0.5  $\mu$ g/mL with no other abnormal results.

On the day of surgery, 1,500 units of C1-inhibitor were administered three hours prior to surgery. His initial vital signs in the operating room were as follows : temperature, 36.4°C ; heart rate, 55 beats/min ; blood pressure 143/95 mmHg, and room air oxygen saturation of the peripheral artery at 98%. General anesthesia was induced by continuous injection of remimazolam at 6 mg/kg/h and remifentanyl at 0.4  $\mu$ g/kg/min. After loss of consciousness, manual mask ventilation was conducted without difficulty, and 50 mg of rocuronium administered. Prior to intubation, transnasal laryngofibroscopy showed no significant edema in the mucosa of the epiglottis, arytenoid cartilage, or vocal cords (Figure 1a). Intubation was carried out with cuffed endotracheal tube with an inner diameter of 7.0 mm (Shiley Oral/Nasal Tracheal Tube Cuffed Reinforced with Stylet ; Covidien, UK) using a McGRATH MAC video laryngoscope (Covidien, UK) (Figure 1b). During the maintenance of anesthesia, remimazolam (1 mg/kg/h) and remifentanyl (0.15-0.3  $\mu$ g/kg/min) were injected continuously while monitoring the patient using an electroencephalogram monitor (Entropy ; GE Healthcare, Fairfield, CT). During the surgery, the entropy SE level was maintained within the range between 40 and 60. After induction of anesthesia, 0.05 mg of phenylephrine was administered once, but no other vasoactive agents were used during the surgery. At the end of the surgery, fibroscopy revealed no significant laryngeal swelling (Figure 1c). Intraoperative data were as follows : 1,050 mL crystalloid fluid administration, 140 g estimated blood loss, and 140 mL urine output ; duration of surgery, 82 min ; duration of anesthesia, 168 min.

At the time of tracheal extubation, we had stopped infusing both remimazolam and remifentanyl, and vital signs were as follows : heart rate, 71 beats/min ; blood pressure, 128/72 mmHg ; oxygen saturation of the peripheral artery with pure oxygen, 100%, and ET<sub>CO</sub>2 level, 37 mmHg. The patient had been

Abbreviations :

HAE : Hereditary angioedema ; SICU : surgical intensive care unit.

Received for publication August 21, 2023 ; accepted January 18, 2024.

Address correspondence and reprint requests to Takahiro Kato, MD, Ph D, Department of Anesthesiology and Critical Care, Hiroshima University, 1-2-3 Kasumi, Minami, Hiroshima 734-8551, Japan and Fax : +81-82-257-5269. E-mail : takadai@hiroshima-u.ac.jp

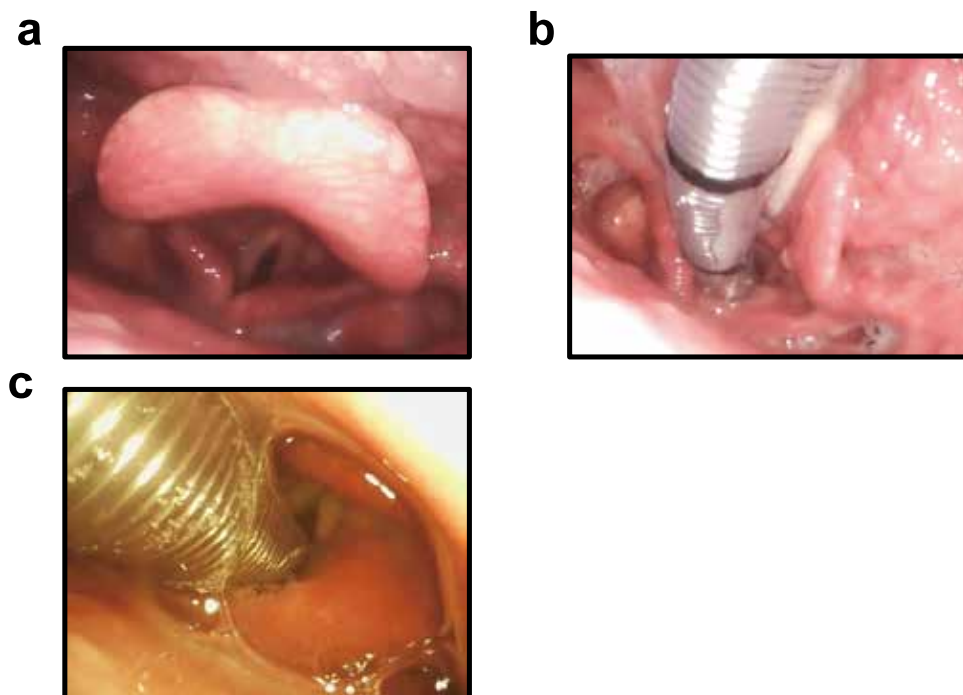


Figure 1. Endoscopic laryngeal images ; (a) Before tracheal intubation, (b) Right after tracheal intubation, (c) Before tracheal extubation

fully recovered from muscle relaxation, but spontaneous breathing had not started yet. Tracheal extubation was performed under deep anesthesia, and manual mask ventilation was initiated. We did not have to administer mechanical ventilation to secure the airway before consciousness coming. After emergence from general anesthesia, 0.2 mg of flumazenil was administered. The patient was transferred to the surgical intensive care unit (SICU) to monitor the upper airway condition.

A blood test in the SICU revealed a D-dimer level of 0.303  $\mu\text{g}/\text{mL}$ . He felt slight swelling of his tongue two hours following surgery, but objective swelling was unclear and his breathing was stable. For these reasons, we decided to follow his symptoms up without any treatments. However, he felt the more increased swelling of his tongue seven hours following surgery, and was treated with 1,000 units of C1-inhibitor. He was moved to the general ward on the first postoperative day and was discharged on the eleventh postoperative day. Blood tests showed that D-dimer was 1.2  $\mu\text{g}/\text{mL}$  on the first postoperative day and 2.5  $\mu\text{g}/\text{mL}$  on the seventh postoperative day, but no additional edema was observed.

## DISCUSSION

In the present case, the patient with HAE had a history of intubation due to upper airway obstruction after dental treatment. In addition, the operation was planned with the patient in a prone position. Therefore, we focused on the possibility of perioperative upper airway obstruction due to HAE. Patients with HAE often have a history of angioedema. Angioedema is sometimes observed in the mucosal membrane of the upper airway, and intubation or other airway management may be required to prevent asphyxiation (5). If fibroscopy shows severe laryngeal or arytenoid mucosal edema, multiple types of devices for airway management must be prepared, including tracheostomy. Because coagulation and fibrinolysis are activated during

angioedema attacks, plasma D-dimer level is a guide used to determine whether acute angioedema attacks might occur (6). If D-dimer levels increase, angioedema attacks that lead to upper airway edema should be carefully monitored. Anesthetic management without tracheal intubation should be chosen as an option according to the type of surgery (7). However, if intubation is necessary, evaluation of upper airway edema is important during the perioperative period. In this case, we observed the upper airway by transnasal fibroscopy before intubation and extubation to ensure that the patient did not show angioedema. Extubation under deep anesthesia with remimazolam and flumazenil enables safe airway management during general anesthesia.

Remimazolam is a new ultrashort-acting benzodiazepine designed to undergo rapid hydrolysis in the body by nonspecific tissue esterase to an inactive carboxylic acid metabolite (4). It is characterized by rapid onset and quick recovery, with fewer cardiac side effects during general anesthesia, such as hypotension or bradycardia (3, 8). Some reports have demonstrated that remimazolam maintained stable hemodynamics during anesthetic management in patients with expected hemodynamic instability (9, 10). Tracheal extubation under deep anesthesia leads to less airway stimulation by an endotracheal tube than extubation while the patient is awake and reduces the incidence of coughing, bucking, and hemodynamic changes due to tracheal tube movement (11). On the other hand, deep extubation can cause upper airway obstruction because of a low level of consciousness (12). Remimazolam provides a more predictable duration of sedative action than the currently available benzodiazepines and is antagonized by flumazenil (9). Therefore, remimazolam can be a useful sedative when deep anesthesia tracheal extubation needs to be considered.

In anesthetic management with HAE, anesthesiologists should consider upper airway edema or obstruction due to direct mucosal stress when attempting intubation or extubation. When HAE attacks of the upper airways occur, urgent treatment is

necessary as early as possible with an intravenous C1 inhibitor or icatibant. Icatibant is indicated for self-administered on-demand treatment of HAE attacks. Intravenous C1 inhibitor is also recommended as preprocedural prophylactic treatment of HAE (13). Therefore, we used a C1 inhibitor in the perioperative phase. Previous reports showed that the mortality rate relating to upper airway obstruction in HAE was as high as 30-50% if managed inappropriately (14). We suggest that tracheal extubation under deep anesthesia with remimazolam may be effective in patients with HAE by reducing airway stimulation and preventing upper airway obstruction caused by a decreased level of consciousness. Administration of a C1-inhibitor was also useful in preventing airway obstruction following surgery.

## CONFLICT OF INTERESTS

The authors declare that they have no competing interests.

## ACKNOWLEDGMENTS

We would like to thank Editage ([www.editage.com](http://www.editage.com)) for English language editing.

## REFERENCES

1. Patel G, Pongracic JA : Hereditary and acquired angioedema. *Allergy Asthma Proc* 40 : 441-5, 2019
2. Keam SJ : Remimazolam : first approval. *Drugs* 80 : 625-33, 2020
3. Antonik LJ, Goldwater DR, Kilpatrick GJ, Tilbrook GS, Borkett KM : A placebo- and midazolam-controlled phase I single ascending-dose study evaluating the safety, pharmacokinetics, and pharmacodynamics of remimazolam (CNS 7056) : Part I. Safety, efficacy, and basic pharmacokinetics. *Anesth Analg* 115 : 274-83, 2012
4. Kilpatrick GJ, McIntyre MS, Cox RF, Stafford JA, Pacofsky GJ, Lovell GG, Wiard RP, Feldman PL, Collins H, Waszczak BL, Tilbrook GS : CNS 7056 : a novel ultra-short-acting benzodiazepine. *Anesthesiology* 107 : 60-6, 2007
5. MacBeth LS, Volcheck GW, Sprung J, Weingarten TN : Perioperative course in patients with hereditary or acquired angioedema. *J Clin Anesth* 34 : 385-91, 2016
6. Cugno M, Zanichelli A, Bellatorre AG, Griffini S, Cicardi M : Plasma biomarkers of acute attacks in patients with angioedema due to C1-inhibitor deficiency. *Allergy* 64 : 254-7, 2009
7. Fujii M, Higashiguchi T, Shime N, Kawabata Y : Successful anesthetic management during abdominal wall-lifting laparoscopic cholecystectomy in a patient with hereditary angioedema. *JA Clin Rep* 4 : 38, 2018
8. Lee A, Shirley M : Remimazolam : a review in procedural sedation. *Drugs* 81 : 1193-201, 2021
9. Saito K, Ohno S, Maeda M, Hirata N, Yamakage M : Remimazolam anesthesia for cardiac surgery with cardiopulmonary bypass : a case report. *JA Clin Rep* 7 : 21, 2021
10. Matsumoto T, Sakurai K, Takahashi K, Kawamoto S : Use of remimazolam in living donor liver transplantation : a case report. *JA Clin Rep* 8 : 65, 2022
11. Difficult Airway Society Extubation Guidelines Group, Popat M, Mitchell V, David R, Patel A, Swampillai C, Higgs A : Difficult Airway Society Guidelines for the management of tracheal extubation. *Anaesthesia* 67 : 318-40, 2012
12. Parr AM, Robinson BJ, Glover PW, Galletly DC : Level of consciousness on arrival in the recovery room and the development of early respiratory morbidity. *Anaesth Intensive Care* 19 : 369-72, 1991
13. Maurer M, Mager M, Betschel S, Aberer W, Ansotegui IJ, Aygören-Pürsün E, Banerji A, Bara NA, Boccon-Gibod A, Bork K, Bouillet L, Boysen HB, Brodski N, Busse PJ, Bygum A, Caballero T, Cancian M, Castaldo A, Cohn DM, Csuka D, Farkas H, Gompels M, Gower R, Grumach AS, Guidos-Fogelbach, G, Hide M, Kang HR, Kaplan AP, Katelaris C, Kiani-Alikhan S, Lei WT, Lockey R, Longhurst H, Lumry WR, MacGinnitie A, Malbran A, Sauer IM, Matta JJ, Nast A, Nguyen D, Nieto-Martinez SA, Pawankar R, Peter J, Porebski G, Prior N, Reshef A, Riedl M, Ritchie B, Sheikh FR, Smith WB, Spaeth PJ, Stobiecki M, Toubi E, Varga LA, Weller K, Zanichelli A, Zhi Y, Zuraw B, Craig T : The international WAO/EAACI guideline for the management of hereditary angioedema-The 2021 revision and update. *Allergy* 77 : 1961-1990, 2022
14. Farkas H : Management of upper airway edema caused by hereditary angioedema. *Allergy Asthma Clin Immunol* 6 : 19, 2010