

# Asymptomatic case of congenital absence of the gallbladder

Naoki Muguruma, Seisuke Okamura, Soichi Ichikawa, Koji Tsujigami,  
Masaharu Suzuki, Masahiko Nakasono, Yoshihiro Kusaka, Masaya Tadatsu,  
Yoshio Okita, and Susumu Ito

*Second Department of Internal Medicine, The University of Tokushima School of Medicine,  
Tokushima, Japan*

**Abstract: Congenital absence of the gallbladder is rare among biliary abnormalities, and its preoperative diagnosis has been considered very difficult. We encountered a patient with congenital absence of the gallbladder and suggest a possible preoperative diagnosis of the abnormality, as well as reviewing the literature. J. Med. Invest. 48 : 118-121, 2001**

**Keywords :** *congenital absence of the gallbladder, preoperative diagnosis*

## INTRODUCTION

Congenital absence of the gallbladder is rare among biliary abnormalities. Since this abnormality was first described in 1701 (1), several cases have been reported (2-13), most of which were unexpectedly found at laparotomy for cholecystolithiasis, cholecystitis or during autopsy. A preoperative diagnosis has been considered very difficult. Frey *et al.* (14) proposed that congenital absence of the gallbladder can be only diagnosed by laparotomy. However, this would be excess surgery because this disease since the abnormality is benign. We encountered a patient with congenital absence of the gallbladder. Here, we suggest a possible preoperative diagnosis of the abnormality, and review the literature.

## CASE REPORT

The patient was 38-year-old male. In April 1996, abnormalities in the gallbladder were observed by abdominal ultrasonography during a clinical examination. The patient was at that time, periodically observed by abdominal ultrasonography, and was referred to our hospital for close examination in May, 1998. The patient had undergone polypectomy of

the colon, but had had no infectious diseases in the biliary duct. When the patient visited our hospital, no physical or biochemical abnormalities were observed. A luminal organ corresponding to the gallbladder was not detected by abdominal ultrasonography in the gallbladder fossa, while high echo areas alone were observed. However, no strong sound shadow, which appears when the gallbladder is filled with stones, was noted (Fig. 1). As with abdominal ultrasonography, abdominal contrast CT did not reveal a luminal organ corresponding to the gallbladder in the gallbladder fossa (Fig. 2). The gallbladder was not found in the abdominal wall or cavity. Excretion of bile to the intestine was observed by 99mTc-N-pyridoxyl-5-methyl-tryptophan (PMT) scintigraphy over a 60 minutes course after intravenous injection, showing good excretion of bile, but the gallbladder was not visualized (Fig. 3). Although the bile duct was clearly demonstrated by ERCP up to its periphery, neither the cystic duct nor gallbladder was shown (Fig. 4). In the compressed images, abnormalities showing stones in the common bile duct were not observed. These findings, together with the absence of the gallbladder in the gallbladder fossa suggested that ectopic gallbladder was unlikely and we diagnosed the disease as congenital absence of the gallbladder. For about 2 years after this diagnosis, the patient has had no subjective symptoms.

Received for publication August 28, 2000 ; accepted October 10, 2000.

Address correspondence and reprint requests to Naoki Muguruma, M.D., Second Department of Internal Medicine, The University of Tokushima School of Medicine, Kuramoto-cho, Tokushima 770-8503, Japan and Fax : +81-88-633-9235.

## DISCUSSION

Congenital absence of the gallbladder is rare

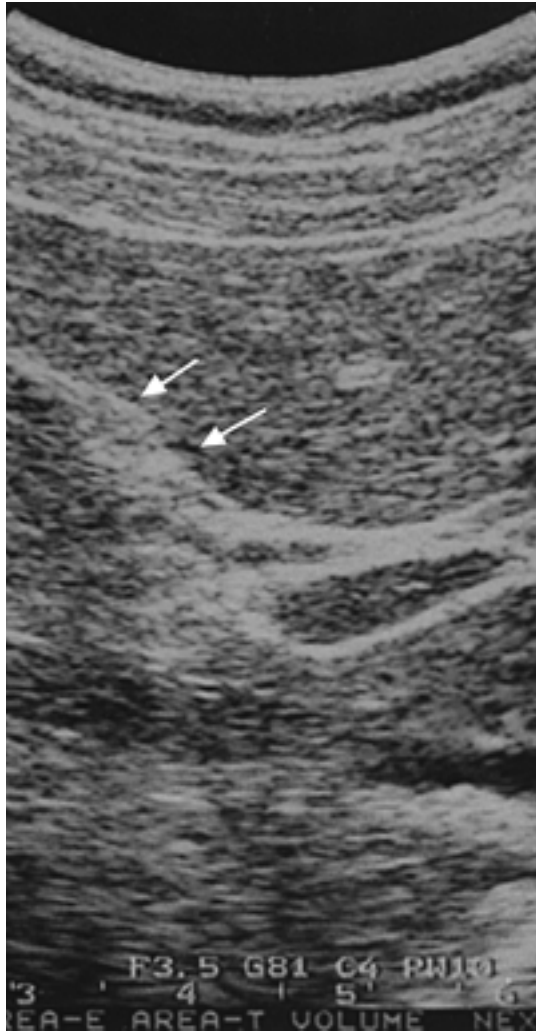


Fig.1. Abdominal ultrasonography shows no luminal organ corresponding to the gallbladder in the gallbladder fossa, while high echo areas alone are observed (arrow).

among biliary abnormalities. This abnormality was first described in 1701 (1), and several studies were recently reported (2-13). However, clinical detection of this abnormality is incidental (10), and many asymptomatic patients may exist. During embryonic development, the gallbladder normally arises as a bud from the hepatic diverticulum, a derivative of the primitive foregut. Failure of further development may result in complete absence of the gallbladder and cystic duct (5). The ultimate cause of such failure remains speculative.

It was reported that this abnormality is often associated with complications of congenital abnormalities in the cardiovascular system, hepatobiliary tree, and the genitourinary and gastrointestinal system (13, 15). It was also reported that there were

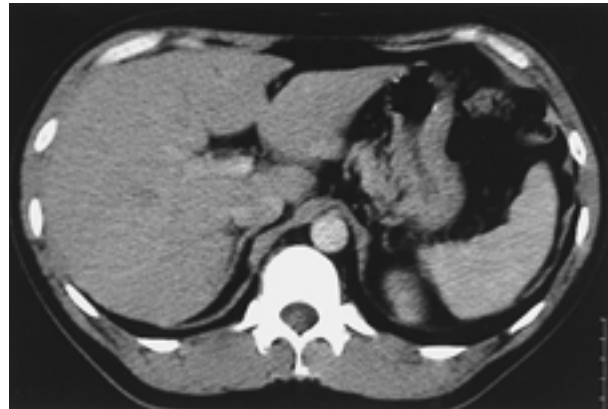

Fig.2. Abdominal contrast CT does not reveal a luminal organ corresponding to the gallbladder in the gallbladder fossa.

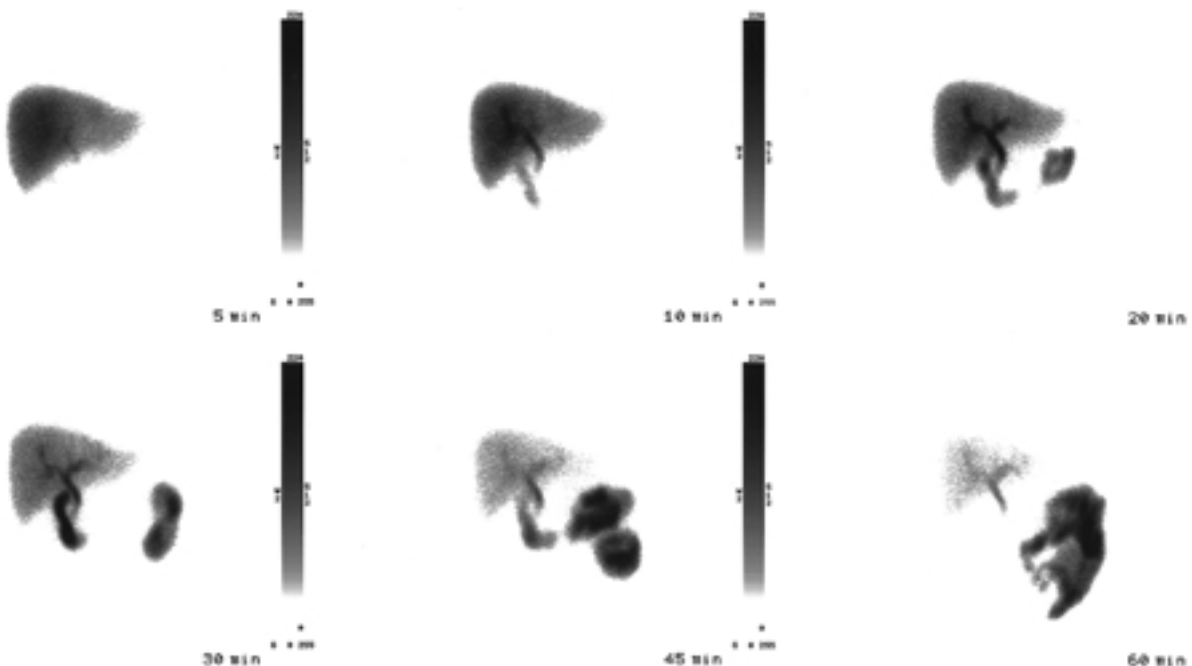


Fig.3. PMT scintigraphy for 60 minutes after intravenous injection shows good excretion of bile, but the gallbladder is not visualized.

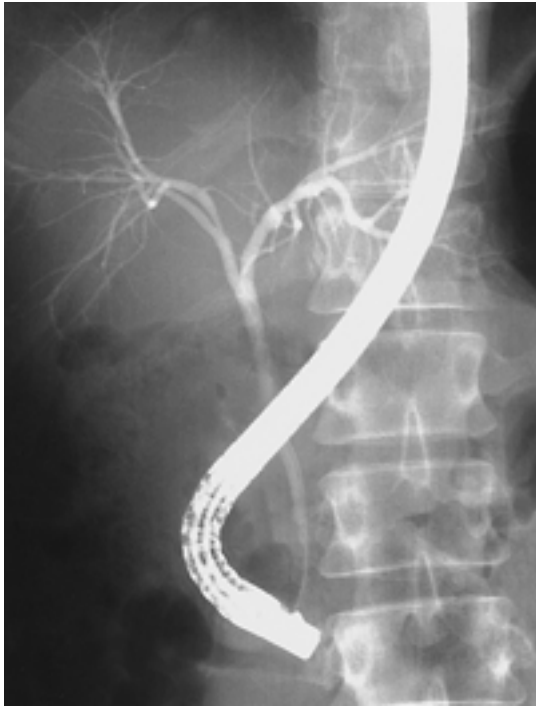


Fig.4. ERCP clearly shows the bile duct to its periphery, but the gallbladder is not observed.

many patients with this abnormality in the same family, suggesting that genetic factors are involved in the abnormality (4). In the present patient, there was no family history of congenital absence of the gallbladder. Bennion *et al.* (16) reported that patients with this abnormality have subjective symptoms such as right upper quadrant pain (90%), nausea (66%), fatty food intolerance (37%), and jaundice (36%). Dyskinesia and common duct stones are considered to cause these symptoms, but the precise mechanisms remain to be clarified. Since this abnormality is often accompanied by these symptoms, and because abdominal ultrasonography and cholangiography show findings similar to cholecystitis, patients with this abnormality are often diagnosed as having cholecystitis and undergo laparotomy (9-11). In patients with this abnormality, periportal tissues and subhepatic peritoneal folds are sometimes revealed by ultrasonography as a thick, contracted, shrunken or scarred gallbladder, and the absence of the gallbladder by cholangiography suggests that a non-functioning gallbladder exists (12, 13). In the present patient, high echo areas were observed by ultrasonography in the gallbladder fossa, but chronic cholecystitis could not be ruled out solely by this observation, as has been reported (9).

Congenital absence of the gallbladder, which is usually benign, is unlikely to transform into malignant disease (11). It was reported that manual detailed

examination during laparotomy and intraoperative cholangiography are required for the diagnosis of this abnormality (16). However, these procedures are inadequate for the diagnosis of ectopic gallbladder. The preoperative diagnosis of congenital absence of the gallbladder is considered difficult, and many recent studies on its diagnostic problems have indicated the need for adequate diagnostic methods (5, 6, 11, 13). O'Sullivan *et al.* (6) suggested that diagnosis of congenital absence of the gallbladder is possible using a combination of imaging techniques including ERCP. Patients showing no past symptoms in whom the gallbladder is not observed even by ERCP, which can visualize the intrahepatic bile duct, should be periodically observed due to the possibility of congenital absence of the gallbladder. However, several problems remain for patients with symptoms. Symptomatic patients with congenital absence of the gallbladder are often diagnosed as having cholecystitis and are subjected to treatments required for cholecystectomy. Therefore, minimally invasive therapy such as laparoscopic cholecystectomy should be chosen as the first treatment method.

In some cases, patients showed improvement after laparotomy or responses to conservative therapy despite the absence of the gallbladder (15). It was also reported that symptoms were improved by sphincterotomy in patients who did not respond to conservative therapy (17). Due to the variety of responses of patients with symptoms, no standard treatment method has been developed, and establishing a standardized system for diagnosis may be difficult. Further studies are required to establishment of diagnostic procedures.

In conclusion, we should be more conscious of the possibility of congenital absence of the gallbladder when the gallbladder is not observed by various imaging techniques, and establish an accurate diagnostic criteria for this disease.

## REFERENCES

1. Bower JO : Congenital absence of the gallbladder. *Ann Surg* 88 : 80-90, 1928
2. Blehschmidt CM : Agenesis of the gallbladder- Borderline-case of normality? *Anat Anz Jena* 151 : 281-285, 1982
3. Bose SM, Sastry RA : Agenesis of gallbladder with choledocho-colonic fistula. *Am J Gastroenterol* 78 : 34-35, 1983
4. Wilson JE, Deitrick JE : Agenesis of the gallbladder : Case report and familial investiga-

- tion. *Surgery* 99 : 106-109, 1985
5. Kennard GK : Congenital agenesis of the gallbladder. A diagnostic problem. Report of a case. *Mil Med* 150 : 283-285, 1985
  6. O'Sullivan J, O'Brien PA, MacFreely L, Whelton MJ : Congenital absence of the gallbladder and cystic duct : Nonoperative diagnosis. *Am J Gastroenterol* 82 : 1190-1192, 1987
  7. Iburarullah M, Sikora SS, Kapoor VK, Awasthi S, Kacker LK : Agenesis of the gallbladder -a case report-. *Jpn J Surg* 21 : 580-582, 1991
  8. Hershman MJ, Southern SJ, Rosin RD : Gallbladder agenesis diagnosed at laparoscopy. *J R Soc Med* 85 : 702-703, 1992
  9. Richards RJ, Taubin H, Wasson D : Agenesis of the gallbladder in symptomatic adults. A case and review of the literature. *J Clin Gastroenterol* 16 : 231-233, 1993
  10. Raule M, Bagni CM, Marinoni M, Meroni M, Perazzori G, Trivellini G : Agenesis of the gallbladder in adults : a diagnostic problem. *Br J Surg* 81 : 676, 1994
  11. Akoh JA, George MM, Auld CD, Walls ADF : Congenital absence of the gallbladder : ways of avoiding laparotomy. *Br J Clin Pract* 48 : 77-78, 1994
  12. Waternberg S, Rahmani H, Avrahami R, Nudelman IL, Deutsch AA : Agenesis of the gallbladder found at laparoscopy for cholecystectomy : an unpleasant surprise. *Am J Gastroenterol* 90 : 1020-1021, 1995
  13. Vijay KT, Kocher HH, Koti RS, Bapat RD : Agenesis of the gallbladder-a diagnostic dilemma. *J Postgrad Med* 42 : 80-82, 1996
  14. Frey C, Bizer L, Ernst C : Agenesis of the gallbladder. *Am J Surg* 114 : 917-926, 1967
  15. Biets D, Dillard D : Agenesis of the gallbladder, malrotation of the gut, and horseshoe kidney. A new syndrome? *Am J Surg* 127 : 596-598, 1974
  16. Bennion RS, Thompson JE, Tompkins RK : Agenesis of the gallbladder without extrahepatic biliary atresia. *Arch Surg* 123:1257-1260, 1988
  17. Meshkinpour H, Mollot M, Eckerling GB, Bookman L : Bile duct dyskinesia : Clinical and manometric study. *Gastroenterology* 87 : 759, 1984