

ORIGINAL**Function of the frontal lobe in autistic individuals
: a proton magnetic resonance spectroscopic study**

Emiko Fujii¹, Kenji Mori¹, Masahito Miyazaki¹, Toshiaki Hashimoto²,
Masafumi Harada³, and Shoji Kagami¹

¹Department of Pediatrics, Institute of Health Biosciences, the University of Tokushima Graduate School ; ²Department of Pediatrics, Tokushima Red Cross Hinomine General Nursing Center ; and ³Department of Radiologic Technology, School of Health Sciences, the University of Tokushima Graduate School, Tokushima, Japan

Abstract : Purpose. In this investigation, we studied differences in chemical metabolites in certain brain regions between autistic patients and normal control subjects. **Methods.** Proton magnetic resonance spectroscopy (¹H-MRS) was used to evaluate functional activity in these regions. Specific regions studied were right and left dorsolateral prefrontal cortex(DLPFC) and the anterior cingulate cortex(ACC). **Results.** In the ACC, the N-acetylaspartate(NAA)/creatine/phosphocreatine(Cr) ratio in autistic patients (n=31) was significantly lower than that in control subjects (n=28). The decrease in the NAA/Cr ratio for the ACC was much greater in the group with worst social ability. NAA/Cr for the left DLPFC and social ability of autistic patients also correlated well. Furthermore, NAA/Cr for the left DLPFC in the group with intelligence quotient (IQ) below 50 was significantly less than in controls. NAA/Cr for the right DLPFC in autistic patients was not decreased compared to controls, and did not correlate with IQ or social ability. **Conclusions.** These findings suggest neuronal dysfunction in the ACC and left DLPFC in autism, and also a relationship between social disability and metabolic dysfunction in these regions. Dysfunction in the ACC and the left DLPFC may contribute to the pathogenesis of autism. *J. Med. Invest.* 57 : 35-44, February, 2010

Keywords : autism, proton magnetic resonance spectroscopy (¹H-MRS), dorsolateral prefrontal cortex(DLPFC), anterior cingulate cortex(ACC)

INTRODUCTION

Autism is a neuropsychiatric condition of childhood characterized by impairment in personal relationships, communication difficulties, and restricted and repetitive interests and activities. Autism is now

widely considered a neurobiologic disorder. Several studies aiming to identify the etiology of autism, have indicated involvement of limbic system structures including amygdala, hippocampus, and anterior cingulate cortex, as well as prefrontal lobe, temporal lobe, and cerebellum (1-4). However, the neural basis of autism remains poorly understood.

Neuropsychologically, impairments in Theory of Mind (ToM), executive function, central coherence, and recognition of emotions have been suggested in autism. The frontal lobe participates importantly in executive function and ToM. It is recognized that

Received for publication May 29, 2009 ; accepted August 20, 2009.

Address correspondence and reprint requests to Emiko Fujii, Department of Pediatrics, Institute of Health Biosciences, the University of Tokushima Graduate School, Kuramoto-cho, Tokushima 770-8503, Japan and Fax : +81-88-631-8697.

the portion of the brain that plays a major role in executive function is the dorsolateral prefrontal cortex (DLPFC : Brodmann's area 46/9) (5-7). The anterior cingulate cortex (ACC) not only participates in executive function but also in emotion and ToM (7-10).

Recently, proton magnetic resonance spectroscopy (^1H -MRS) has been used to examine brain metabolism in patients. The main metabolites that can be assessed using this technique are N-acetylaspartate (NAA), creatine/phosphocreatine (Cr), and choline-containing compounds (Cho). The NAA signal, the most prominent ^1H spectral peak, is present at high concentrations in neurons, and might be related to mitochondrial function. Therefore, NAA often is used to assess neuronal density (11-13). The Cho signal, which might indicate glial cell density (13-15), increases in intensity with increased membrane synthesis and turnover (16, 17). The Cr signal might reflect glial or overall (neurons plus glia) cell density (13, 14); phosphocreatine represents a key component of high-energy phosphate metabolism (18). ^1H -MRS studies often use Cr as an internal intensity reference for other peaks, on the assumption that its concentration is relatively constant. We previously investigated brain function in autistic patients using ^1H -MRS, and reported that the concentrations of NAA were decreased in the amygdala, Wernicke's area, and the cerebellum (19, 20). We consider ^1H -MRS to be a valuable tool for detection of neuronal impairment in autistic brain.

In the present study, we used ^1H -MRS to investigate metabolism in the DLPFC and ACC of subjects with autism and healthy control subjects, comparing amounts and patterns of chemical metabolites. We also related the metabolic findings to intellectual and social abilities in subjects with autism.

2 PATIENTS AND METHODS

2-1 Patients

2-1-1 Anterior cingulate cortex (ACC)

The study group included 31 autistic patients (2 to 13 years old; mean age 6.1; 25 boys and 6 girls). These individuals were recruited from among outpatients at the Department of Pediatrics of Tokushima University. All subjects in this group were diagnosed with autistic disorder by two experienced pediatric neurologists according to the criteria of the Diagnostic and Statistical Manual of Mental Disorders IV(DSM-IV). The intelligence

quotient (IQ) determined by the Tanaka-Binet intelligence scale was over 85 in 4 patients; 71 to 84 in no patients; 50 to 70 in 7 patients; 35 to 49 in 10 patients; and 20 to 34 in 10 patients. Social ability of the autistic patients was evaluated with a social maturity scale (Nihon Bunka Kagakusha); (S-M scale). The social quotient (SQ) by the S-M scale was over 85 in 3 patients; 71 to 84 in 2 patients; 50 to 70 in 7 patients; 35 to 49 in 15 patients; and 20 to 34 in 4 patients.

The control subjects were 28 children underwent an MRI examination because of headache or head trauma. They showed no developmental or behavioral abnormality. Ages and genders (2 to 15 years old; mean, 6.8; 21 boys and 5 girls) were matched with those of autistic patients.

Informed consent was obtained from the parents of all subjects. Informed consent was also obtained from the subjects who could understand the content and purpose of this study.

2-1-2 Bilateral dorsolateral prefrontal cortex (DLPFC)

This group consisted of 20 individuals (2 to 13 years old; mean, 7.5; 17 boys and 3 girls). These individuals were a subgroup of the subjects in the ACC examination. We first examined ^1H -MRS in the ACC and next in the DLPFC. We performed ^1H -MRS in the ACC only when patients could not lie still until all ^1H -MRS measurements were completed. IQ was over 85 in 4 patients who underwent ^1H -MRS in both areas; 71 to 84 in 0 patients; 50 to 70 in 4 patients; 35 to 49 in 6 patients; and 20 to 34 in 6 patients. SQ was over 85 in 3 patients; 71 to 84 in 2 patients; 50 to 70 in 4 patients; 35 to 49 in 9 patients; and 20 to 34 in 2 patients. Control subjects were 18 children (2 to 15 years old; mean, 7.8; 16 boys and 2 girls), who showed no developmental or behavioral abnormalities.

2-2 ^1H -MRS measurement

All ^1H -MRS studies were performed with a 1.5-tesla clinical MRI system (Signa Horizon, GE, Milwaukee, WI) with a standard head coil, using a point-resolved spectroscopic (PRESS) sequence, with TR of 1300 and TE of 135 ms, and 256 free-induction decays (FID). Gradient map shimming was conducted in the location of measurement by a high-order shim program; the full width of the half maximum of the water peak was less than 8 Hz. We acquired T1 and T2 MRI images in axial and coronal views before the ^1H -MRS examination, and placed a single 3.4 ml (1.5×1.5×1.5 cm) volume of interest

(VOI) in each DLPFC (Brodmann's area 46/9, Fig. 1). In the present study, the VOI was placed mainly in Brodmann's area 46, which is considered to play a leading role in central executive (21). Spectra were processed using SA/GE software. FIDs were zero-filled to 4096 data-points, and Fourier transformation was performed. After DC offset correction, we calculated peak areas, i.e. signal intensities of NAA, Cr, and Cho, with curvefitting using a Gaussian function. Criteria for selecting reliable metabolite signals were based on the S.D. of the fit for each metabolite; only results with S.D. below 20% were included in the analysis. Signal-intensity ratios for NAA/Cr, NAA/Cho, and Cho/Cr were compared with those of control subjects. Furthermore, LCMoDel ver. 5.6, a fully automated program for analyzing metabolic products was used to estimate NAA, Cr, and Cho concentrations. We placed a single 4.5 ml ($2.0 \times 1.5 \times 1.5$ cm) VOI in the ACC, where we measured

the above metabolites using the same method (Fig. 1). This study was approved by the Institutional Review Board of our institution.

2-3 Statistical analysis

We compared autistic patients with control individuals with respect to the signal ratios for NAA/Cr, NAA/Cho, and Cho/Cr. Furthermore, we also compared concentrations of NAA, Cho, and Cr. We used Student's t test to determine statistically significant differences between autistic patients and the control group, and used a paired Student's t test to compare left vs, right side among several groups. A value of p below 0.05 was considered statistically significant. Furthermore, we examined the correlation between the signal ratio of NAA/Cr and IQ and SQ in autistic patients using Pearson's correlation coefficient.

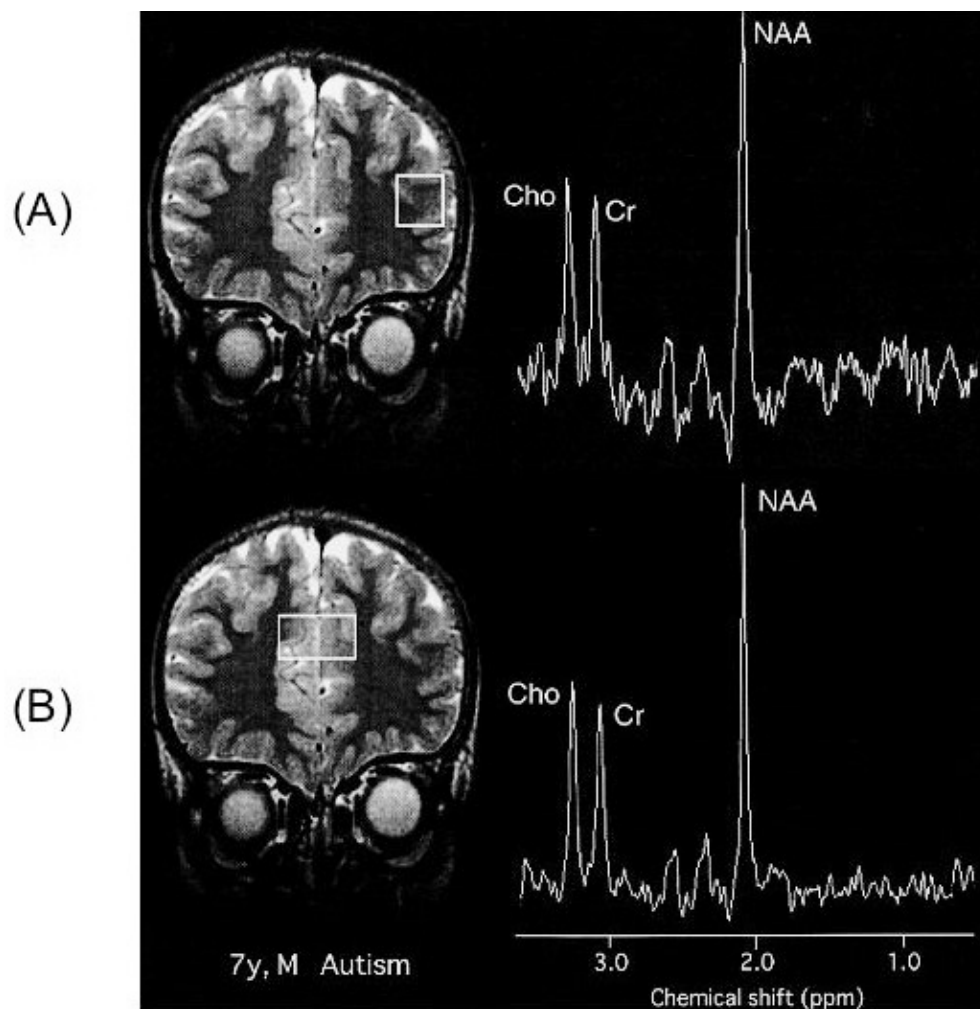


Fig. 1 Measurement locations for ^1H -MRS and representative spectra obtained. (A) : Left dorsolateral prefrontal cortex (DLPFC). (B) : Anterior cingulate cortex (ACC). NAA, N-acetylaspartate; Cr, creatine/phosphocreatine; Cho, choline-containing compounds.

RESULTS

The baseline MRI was evaluated individually by two experienced pediatric neurologists and one neuroradiologist. No abnormal signal or distinct atrophy was detected in frontal lobes of autistic patients or control individuals at the time when ^1H -MRS studies were performed.

The NAA/Cr ratio for the ACC and the left DLPFC in autistic patients was significantly decreased

compared with the control group ($p < 0.05$). There was no significant difference in this value in the right DLPFC (Fig. 2, Table 1). The NAA/Cho ratio in the ACC was significantly decreased compared with the control group ($p < 0.01$). There was no significant difference in this value in left or right DLPFC (Table 1).

We investigated the relationship between IQ and NAA/Cr in autistic patients. They were poorly correlated, as indicated by low correlation coefficients

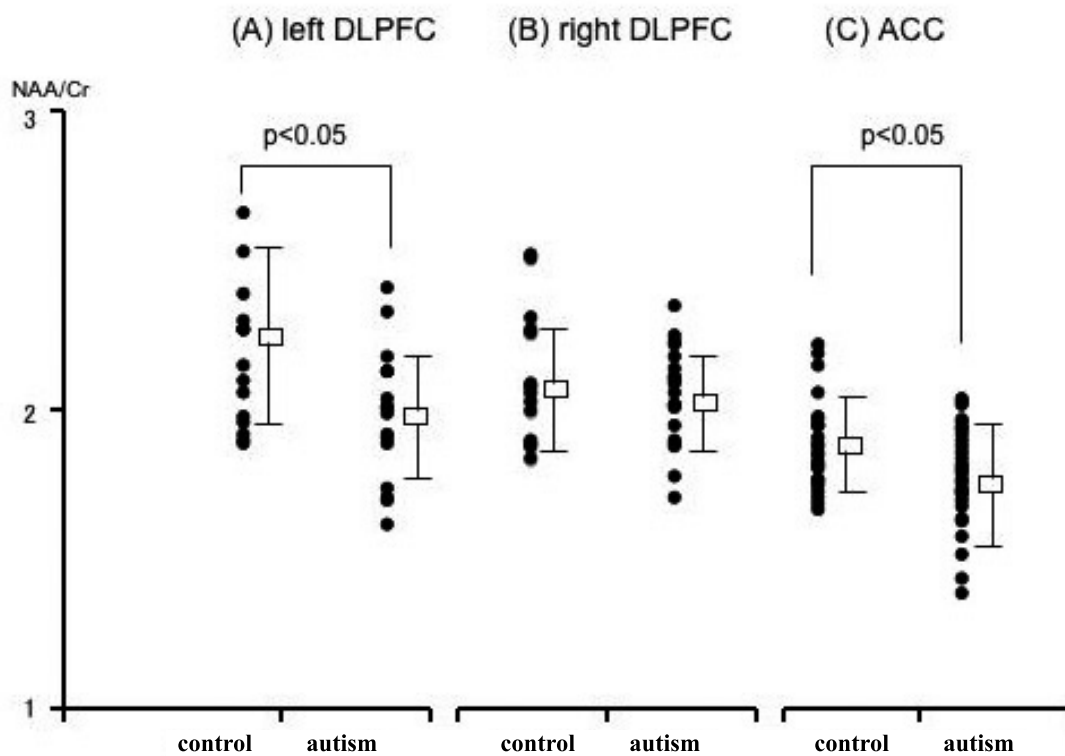


Fig. 2 NAA/Cr ratio for left and right DLPFC and the right ACC in control subjects and autistic patients. NAA/Cr ratio for the left DLPFC and the ACC in autistic patients is significantly decreased compared with control subjects ($p < 0.05$).

Table 1 Metabolite concentrations and ratios in autistic and control subjects

		NAA (mM)	Cho (mM)	Cr (mM)	NAA/Cr	NAA/Cho	Cho/Cr
ACC	autism	5.91 ± 0.93	1.60 ± 0.21	4.30 ± 0.90	1.81* ± 0.17	1.52** ± 0.20	1.17 ± 0.13
	control	6.03 ± 0.89	1.51 ± 0.19	4.10 ± 0.71	1.90 ± 0.15	1.64 ± 0.12	1.16 ± 0.13
left DLPFC	autism	6.98 ± 1.60	1.50 ± 0.41	4.70 ± 1.30	2.01* ± 0.21	2.02 ± 0.36	1.03 ± 0.19
	control	7.51 ± 2.43	1.40 ± 0.30	4.11 ± 0.89	2.23 ± 0.30	2.17 ± 0.45	1.05 ± 0.16
right DLPFC	autism	7.49 ± 1.42	1.50 ± 0.20	4.70 ± 0.89	2.07 ± 0.16	1.92 ± 0.31	1.09 ± 0.24
	control	7.68 ± 1.30	1.43 ± 0.31	4.40 ± 1.10	2.14 ± 0.22	2.20 ± 0.41	1.10 ± 0.15

Values are the mean ± SD. * $p < 0.05$; ** $p < 0.01$. ACC, anterior cingulate cortex; DLPFC, dorsolateral prefrontal cortex; NAA, N-acetylaspartate; Cho, choline-containing compounds; Cr, creatine/phosphocreatine.

in each area ($r=0.32$ for left DLPFC, $r=0.12$ for right DLPFC, $r=0.34$ for ACC) ; Fig. 3A, B, and C. However, NAA/Cr for the left DLPFC in the group

whose IQ was below 50 was significantly lower than in the control group ($p < 0.05$, Fig. 4A).

We investigated the relationship between SQ and

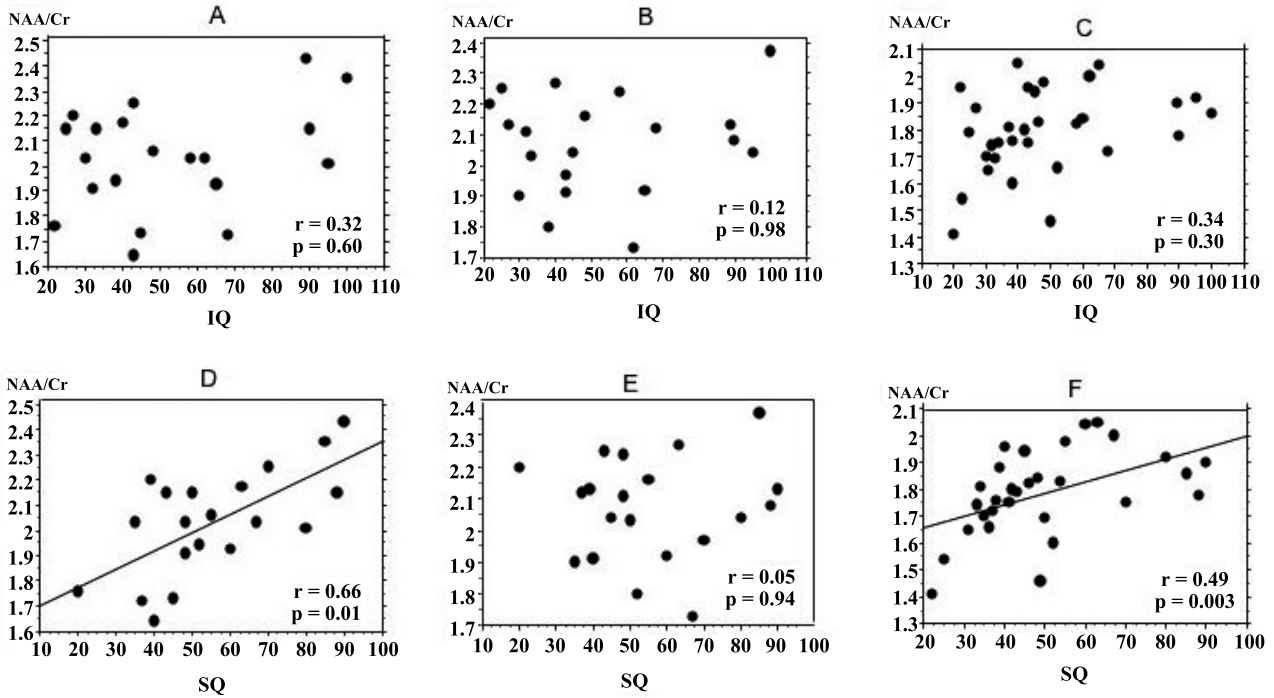


Fig. 3 Correlation between IQ, SQ, and NAA/Cr in autistic patients. No correlation is evident between intelligence quotient (IQ) and NAA/Cr in any area studied (A, B, C), but a significant correlation is confirmed between social quotient (SQ) and NAA/Cr in the left DLPFC and the ACC (D, F). A, left DLPFC ; B, right DLPFC ; C, ACC ; D, left DLPFC ; E, right DLPFC ; F, ACC.

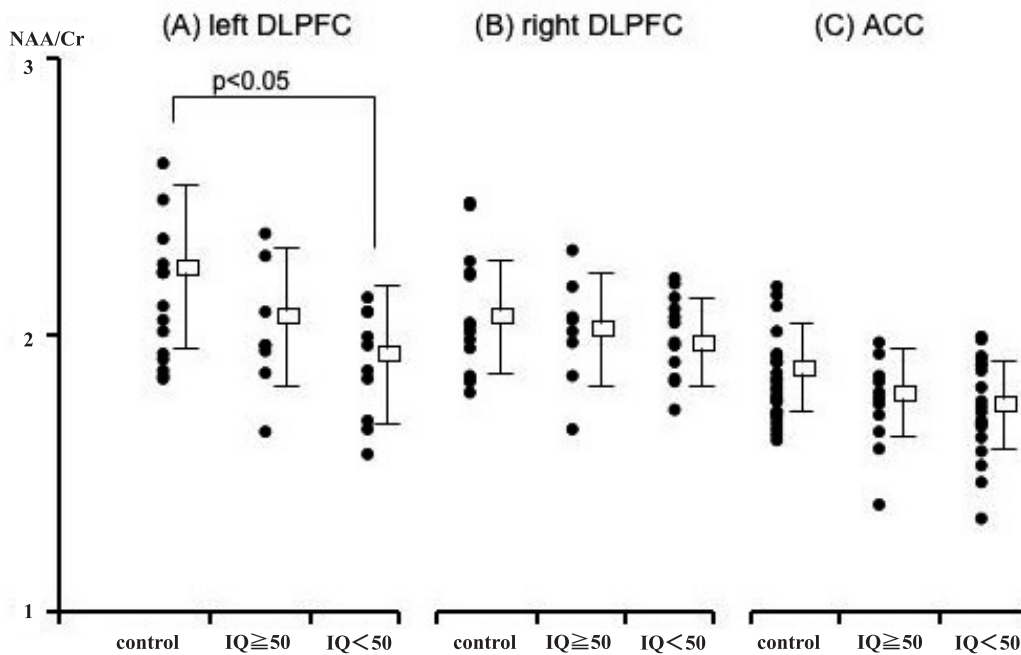


Fig. 4 NAA/Cr ratio for left and right DLPFC and the ACC in control subjects and in autistic patients divided into groups with intelligence quotients (IQ) above and below 50. NAA/Cr ratio for the left DLPFC in the autistic group with IQ below 50 is significantly lower than in control subjects ($p < 0.05$).

NAA/Cr in autistic patients. NAA/Cr for the left DLPFC in autism was correlated with SQ. The correlation coefficient was 0.66 ($p=0.01$; Fig. 3D). NAA/Cr for the left DLPFC in the subgroup whose SQ was below 50 was significantly low compared to the control group ($p<0.01$) and the subgroup whose SQ was above 50 ($p<0.05$, Fig. 5A). NAA/Cr for the ACC in the autism group also correlated with SQ. The correlation coefficient was 0.49 ($p=0.003$; Fig. 3F). NAA/Cr for the ACC in the subgroup, whose SQ was below 50 was decreased significantly compared to the control group ($p<0.01$ Fig. 5C). NAA/Cr and SQ were poorly correlated in the right DLPFC Fig. 3E and 5B).

There was no significant difference in concentrations of NAA, Cho, and Cr in any region between the autism and control groups (Table 1). When we evaluated laterality of metabolite concentrations in the DLPFC, there was no significant difference in either the control or autism group.

There was no significant difference in Cho/Cr ratio for any region between autism and control groups (Table 1).

The distributions of NAA/Cr ratio for the ACC according to age in autistic patients and control subjects are shown in Fig. 6. The correlation coefficients for NAA/Cr ratio and age were not statistically significant in the ACC of autistic patients and control

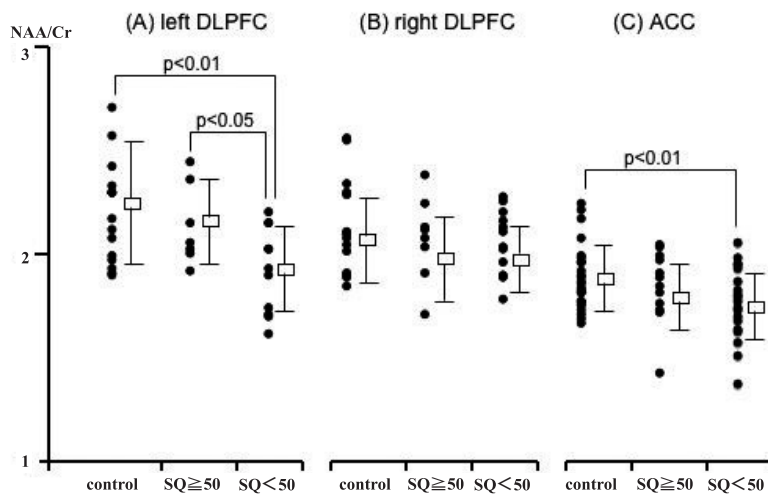


Fig. 5 NAA/Cr ratio for left and right DLPFC and the ACC in normal control subjects and in autistic patients divided into groups with social quotients (SQ) above and below 50. NAA/Cr for the left DLPFC in the autistic group with SQ below 50 is significantly lower than in control subjects ($p<0.01$) or autistic subjects with SQ above 50 ($p<0.05$). NAA/Cr ratio of the ACC in the group whose SQ is below 50 is decreased significantly compared to control subjects ($p<0.01$).

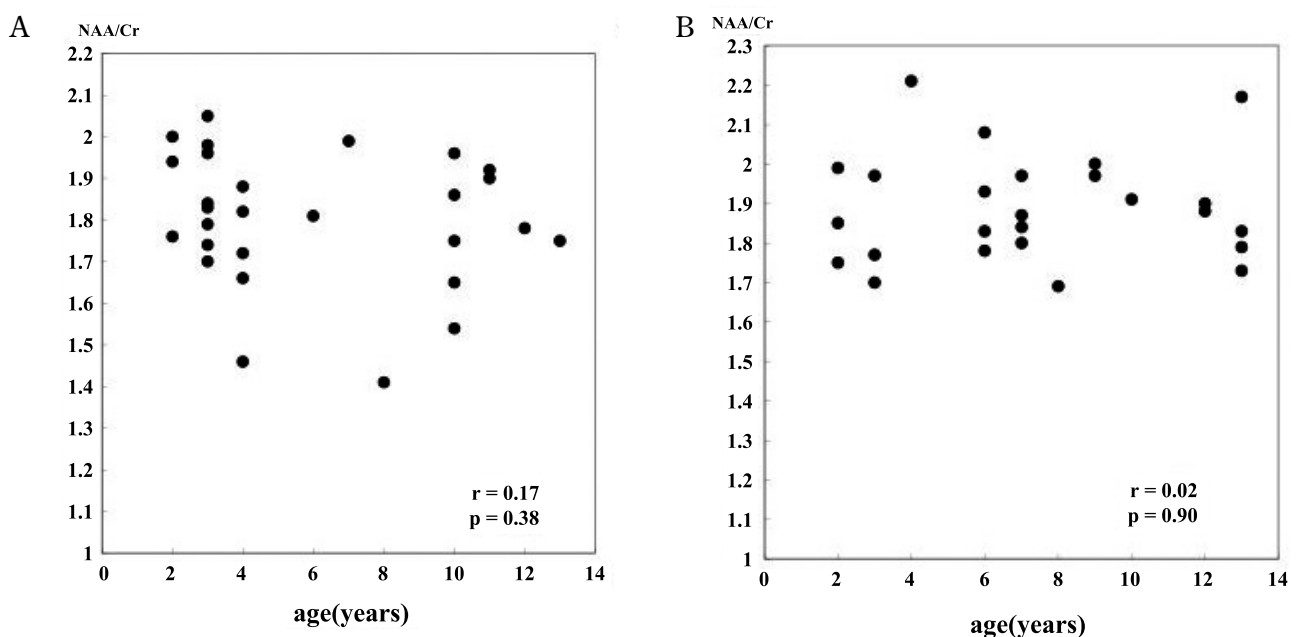


Fig. 6 The distributions of NAA/Cr ration for the ACC according to age in autistic patients (A) and control subjects (B). No correlation is evident between NAA/Cr and age in autistic patients and control subjects.

subjects. No correlation was also observed in left and right DLPFC of autistic patients and control subjects.

DISCUSSION

It is recognized that executive function deficits are frequently seen in individuals who have sustained damage to the frontal lobes. They include repetitive, aimless movements or speech, difficulty inhibiting familiar or obvious responses, inappropriate repetition of previous thoughts or actions, and diminished capacity for planning. Stuss described several additional information-processing deficits resulting from frontal lobe pathology, including a tendency to focus on one aspect of information, difficulty relating or integrating isolated details, problems managing simultaneous or multiple sources of information, and impaired ability to act on or apply knowledge in a meaningful manner (22, 23). Recently, it was recognized that the portion of the brain that plays a major role in executive function is the DLPFC (5, 6).

Some features of autism are reminiscent of the executive function deficits that follow frontal injury. The behavior of autistic people often appears rigid and inflexible ; many children with autism become distressed over trivial changes in the environment and insist on following routines in precise detail. They are often very perseverative, focusing on one narrow interest or repetitively engaging in one stereotyped behavior. They may be impulsive, having trouble delaying or inhibiting responses. Some individuals with autism possess a large store of information, but seem to have trouble applying or using this knowledge meaningfully. Finally, autistic people often seem narrowly focused on details and have difficulty in "seeing the big picture". Thus, there appear to be similarities between autism and executive function deficits at both descriptive and behavioral levels (24).

In recent years, neuroradiologic studies have revealed disorders in autistic patients' frontal function. Hashimoto (25) and Ohnishi, *et al.* (26) used single-photon emission computed tomography (SPECT) to examine cerebral blood flow of autistic patients, reporting that blood flow was decreased in the frontal region (27). Chugani, *et al.* used positron emission tomography (PET) to examine serotonin metabolism, finding a decline in synthesis of serotonin in the left frontal lobe and left thalamus in autistic

patients.

This study used ¹H-MRS to demonstrate that NAA/Cr for the left DRPFC of autistic patients correlated well with SQ ; autistic persons whose SQ scores were below 50 had a significant decrease in NAA/Cr in the DLPFC. However, those whose SQ scores were above 50 had no such decrease in the left DLPFC. NAA is present in neurons, and reduced NAA reflects decreases in the number of neurons, lowered neuron activity, and/or disorders of neuronal development. These findings suggest that disorders of neurons of the left DLPFC participate in disturbances in social orienting in autism. Highly developed executive function is considered to be necessary in order to adapt to variable environments, and to maintain normal social interactions. Ozonoff, *et al.* (24, 28) also hypothesized that alterations in executive function could explain the social impairments of autism. Furthermore, we found that left DLPFC NAA/Cr was decreased significantly in patients whose IQ was below 50. It is possible that dysfunction of neurons in the left DLPFC participates in disordered communication through language, which contributes to lower IQ scores in patients with autism.

The ACC shapes a part of the executive function neuronal network together with the DLPFC, and participates in the cognitive control of attention (7, 8). The ACC also has close anatomic connections to the amygdala, and orbitofrontal cortex, and participates in emotional expression. Monkeys in whom the ACC is destroyed have poor vocal and facial expression, showing decreased tendency to approach other monkeys and decreased vocalization to monkeys approaching them (29). These monkeys also engage in playing with plastic toys for prolonged periods of time while neglecting other monkeys. Humans with injury to the ACC have been noted to have emotional changes such as decreased feeling, hypalgesia, and emotional instability (30). Gallagher, *et al.* (9) used functional magnetic resonance imaging (fMRI) to examine brain metabolic activity in response to both verbal ToM stories and non-verbal ToM tasks that involved the processing of visually presented cartoons. They observed brain activation associated with both tasks, specifically in the paraculate area of the dorsomedial frontal cortex. Brunet, *et al.* (10) used PET to examine processing of comic strips depicting stories either involving the attribution of intention to characters or understanding physical causal sequences involving the characters. Comparison of these conditions suggests that

the former is associated with regional cerebral blood flow increases in the right dorsomedial frontal cortex and in the left and right ACC. These findings suggest that the ACC is likely to be responsible for an important part of social cognitive function and emotional expression.

Autistic patients have impairments of ToM, and frequently have emotional and sensory disturbances. Haznedar, *et al.* (31) reported decreased glucose metabolism in the ACC of autistic patients using ^{18}F fluoro-deoxyglucose PET during verbal learning by the California method. Furthermore, MRI studies have shown decreased volume of the ACC in autistic patients. Histologic abnormalities in the ACC, including decreased neuron size, have been seen in the brains of autistic patients (32). Our examination of NAA/Cr in the ACC of autistic patients showed a significant decrease compared to the control group. This was particularly true for patients whose SQ scores were decreased. These findings are consistent with histologic findings reported in autistic patients, and present understanding of the functions of the ACC.

In the present study, NAA/Cr ratio was significantly decreased for many regions in autistic patients, but we could not detect any significant differences between concentrations of NAA, Cho, and Cr in any region between the autistic groups. This discrepancy might have resulted from small sample size in this study. The NAA concentration in each region in autistic patients was slightly but not significantly decreased from that in the control group. On the other hand, concentrations of Cho and Cr in each region were slightly increased in autistic patients compared with the control group. Consequently, the NAA/Cr and NAA/Cho ratios were significantly decreased for many regions in autistic patients. The increased concentrations of Cr and Cho might reflect glial activation and increased membrane turnover in autistic brain (33, 34).

Some reports have described biochemical differences in the brain related to age and/or gender. Kadota, *et al.* (35) determined that white matter NAA/Cho ratios showed rapid growth during the first decade and reached a maximum value in the second or early third decade, followed by a steady decline starting in the latter half of the third decade. Furthermore, they found that the growth spurt and age-related decline of the white matter NAA/Cho were steeper in male than in female subjects. In this study, we used age- and gender-matched control subjects. Furthermore, no correlation was evident

between NAA/Cr and age in any region of autistic patients and control subjects. Therefore, our findings should not be greatly influenced by age or gender.

Evidence of neuronal dysfunction was found in the DLPFC and ACC of autistic brains in this study. There is some possibility that dysfunction of the DLPFC and ACC is responsible for the pathogenesis of autism. However, as described in previous reports (19-21, 36, 37), many other regions, including the temporal lobe, amygdala, hippocampus, brainstem, and cerebellum, have been suggested to be involved in autism. We previously found decreased concentrations of NAA in the amygdaloid-hippocampal region, Wernicke's area, and the cerebellum. The amygdala has a close anatomic connection to the ACC, and is considered part of the social brain. Previous functional MRI studies in autism reported reduced activation in the amygdala when making emotional judgments concerning eyes, processing facial emotion, and performing a face perception task (1, 38, 39). These findings suggest that the amygdala is important in autistic symptoms such as emotional and social impairment. Neuronal impairment or dysfunction in Wernicke's area may correlate with the language disorder in autistic patients. The cerebellum has close anatomic connections with the frontal lobe, involving not only motor functions but also cognitive functions. Many patients with autism show clumsiness. Moreover, a postmortem study detected a significant decrease in number of Purkinje cells in the cerebellar cortex of autistic brains (2). Future studies will help to clarify the relationship between above mentioned many regions of the autistic brain.

REFERENCES

1. Baron-Cohen S, Ring HA, Wheelwright S, Bullmore ET, Brammer MJ, Simmons A, Williams SC : Social intelligence in the normal and autistic brain : An fMRI study. *Eur J Neurosci* 11 : 1891-8, 1999
2. Bauman ML, Kemper TL : Structural brain anatomy in autism : What is the evidence? *The Neurobiology of Autism*, 2nd ed. Baltimore, Maryland : Johns Hopkins University Press : 121-35, 2005
3. Palmen SJ, Van Engeland H, Hof PR, Schmitz C : Neuropathological findings in autism. *Brain* 127 : 2572-83, 2004
4. Sokol DK, Edwards-Brown M : Neuroimaging

- in autistic spectrum disorder (ASD). *J Neuroimaging* 14 : 8-15, 2004
5. Owen AM, Evans AC, Petrides M : Evidence for a two-stage model of spatial working memory processing within the lateral frontal cortex : A positron emission tomography study. *Cerebral Cortex* 6 : 31-8, 1996
 6. Berman KF, Ostrem JL, Randolph C, Gold J, Goldberg TE, Coppola R, et al. : Physiological activation of a cortical network during performance of the Wisconsin Card Sorting Test : A positron emission tomography study. *Neuropsychologia* 33 : 1027-46, 1995
 7. Osaka N, Osaka M, Kondo H, Morishita M, Fukuyama H, Shibasaki H : The neural basis of executive function in working memory. An fMRI study based on individual differences. *Neuroimage* 21 : 623-31, 2004
 8. Cohen JD, Botvinick M, Carter CS : Anterior cingulate and prefrontal cortex : who's in control? *Nat Neurosci* 3 : 421-3, 2000
 9. Gallagher HL, Happé F, Brunswick N, Fletcher PC, Frith U, Frith CD : Reading the mind in cartoons and stories : an fMRI study of 'theory of mind' in verbal and nonverbal tasks. *Neuropsychologia* 38 : 11-21, 2000
 10. Brunet E, Sarfati Y, Hardy-Baylé MC, Decety J : A PET investigation of the attribution of intentions with a nonverbal task. *Neuroimage* 11 : 157-66, 2000
 11. Birken DL, Oldendorf WH : N-acetyl-L-aspartic acid : A literature review of a compound prominent in 1H-NMR spectroscopic studies of brain. *Neurosci Biobehav Rev* 13 : 23-31, 1989
 12. Clark JB : N-acetyl aspartate : a marker for neuronal loss or mitochondrial dysfunction. *Dev Neurosci* 20 : 271-6, 1998
 13. Urenjak J, Williams SR, Gardian DG, Noble M : Proton nuclear magnetic resonance spectroscopy unambiguously identifies different neural cell types. *J Neurosci* 13 : 981-9, 1993
 14. Brand A, Richter-Landsberg C, Leibfritz D : Multinuclear NMR studies on the energy metabolism of glial and neural cells. *Dev Neurosci* 15 : 289-98, 1993
 15. Gupta RK, Cloughesy TF, Sinha U, Garakian J, Lazareff J, Rubino G, Rubino L, Becker DP, Vinters HV, Alger JR : Relationships between choline magnetic resonance spectroscopy, apparent diffusion coefficient and quantitative histopathology in human glioma. *J Neurooncol* 50 : 215-26, 2000
 16. Gill SS, Thomas DG, Van Bruggen N, Gadian DG, Peden CJ, Bell JD, Cox IJ, Menon DK, Iles RA, Bryant DJ : Proton MR spectroscopy of intracranial tumors : *In vivo* and *in vitro* studies. *J Comp Assist Tomogr* 14 : 497-504, 1990
 17. Speck O, Thiel T, Hennig J : Grading and therapy monitoring of astrocytomas with 1H-spectroscopy : preliminary study. *Anticancer Res* 16 : 1581-5, 1996
 18. Tedeschi G, Bertolino A, Righini A, Campbell G, Raman R, Duyn JH, Moonen CT, Alger JR, Di Chiro G : Brain regional distribution pattern of metabolite signal intensities in young adults by proton magnetic resonance spectroscopic imaging. *Neurology* 45 : 1384-91, 1995
 19. Otsuka H, Harada M, Mori K, Hisaoka S, Nishitani H : Brain metabolites in the hippocampus-amygdala region and cerebellum in autism : an 1H-MR spectroscopy study. *Neuroradiology* 41 : 517-9, 1999
 20. Hisaoka S, Harada M, Nishitani H, Mori K : Regional magnetic resonance spectroscopy of the brain in autistic individuals. *Neuroradiology* 43 : 496-8, 2001
 21. Hashimoto T, Tayama M, Miyazaki M, Murakawa K, Kuroda Y : Brainstem and cerebellar vermis involvement in autistic children. *J Child Neurol* 8 : 149-53, 1993
 22. Stuss DT, Benson D : The frontal lobes. New York : Raven Press, 1986
 23. Mateer CA, Williams D : Effects of frontal lobe injury in childhood. *Devel Neuropsychol* 7 : 359-76, 1991
 24. Ozonoff S, Pennington BF, Rogers SJ : Executive function deficits in high functioning autistic individuals : Relationship to theory of mind. *Child Psychol Psychiatry* 32 : 1081-105, 1991
 25. Hashimoto T, Sasaki M, Fukumizu M : Single emission computed tomography of the brain in autism : effect of the developmental level. *Pediatr Neurol* 23 : 416-20, 2000
 26. Ohnishi T, Matsuda H, Hashimoto T : Abnormal regional cerebral blood flow in childhood autism. *Brain* 123 : 1838-44, 2000
 27. Chugani DC, Muzik O, Rothermel R, Behen M, Chakraborty P, Mangner T, Silva EA, Chugani HT : Altered serotonin synthesis in the dentatohalamocortical pathway in autistic boys. *Ann Neurol* 42 : 666-9, 1997
 28. Ozonoff S, Griffith EM : Neuropsychological function and the external validity of Asperger syndrome. In : Klin A, Volkmar FR, Sparrow

- SS editors. Asperger syndrome. Guilford Press, New York, 2000, PP. 72-96
29. Hadland KA, Rushworth MF, Gaffan D, Passingham RE : The effect of cingulate lesions on social behavior and emotion. *Neuropsychologia* 41 : 919-31, 2003
 30. Vogt BA, Finch DM, Olson CR : Functional heterogeneity in cingulate cortex : the anterior executive and posterior evaluative regions. *Cereb Cortex* 2 : 435-43, 1992
 31. Haznedar MM, Buchsbaum MS, Metzger M, Solimando A, Spiegel-Cohen J, Hollander E : Anterior cingulate gyrus volume and glucose metabolism in autistic disorder. *Am J Psychiatry* 154 : 1047-50, 1997
 32. Kemper TL, Bauman M : Neuropathology of infantile autism. *J Neuropathol Exp Neurol* 57 : 645-52, 1998
 33. Vargas DL, Nascimbene CN, Krishnan C, Zimmerman AW, Pardo CA : Neuroglial activation and neuroinflammation in the brain of patients with autism. *Ann Neurol* 57 : 67-81, 2005
 34. Sokol DK, Dunn DW, Edwards-Brown M, Feinberg J : Hydrogen proton magnetic resonance spectroscopy in autism : preliminary evidence of elevated choline/creatine ratio. *J Child Neurol* 17 : 245-9, 2002
 35. Kadota T, Horinouchi T, Kuroda C : Development and aging of the cerebrum : assessment with proton MR spectroscopy. *AJNR Am J Neuroradiol* 22 : 128-35, 2001
 36. Courchesne E, Saitoh O, Yeung-Courchesne R, Press GA, Lincoln AJ, Haas RH, Schreibman L : Abnormality of cerebellar vermal lobules VI and VII in patients with infantile autism : identification of hypoplastic and hyperplastic subgroups with MR imaging. *AJR* 162 : 123-30, 1994
 37. Frith U, Frith CD : Development and neurophysiology of mentalizing. *Philos Trans R Soc Lond B Biol Sci* 358 : 459-73, 2003
 38. Critchley HD, Daly EM, Bullmore ET, Williams SC, Van Amelsvoort T, Robertson DM, Rowe A, Phillips M, McAlonan G, Howlin P, Murphy DG : The functional neuroanatomy of social behaviour ; Changes in cerebral blood flow when people with autistic disorder process facial expressions. *Brain* 123 : 2203-12, 2000
 39. Pierce K, Muller RA, Ambrose J, Allen G, Courchesne E : Face processing occurs outside the fusiform 'face area' in autism : Evidence from functional MRI. *Brain* 124 : 2059-73, 2001